

Technical Report

## Electromyographically Guided Trigger Point Injections in the Cervicothoracic Musculature of Obese Patients: A New and Unreported Technique

Kenneth P. Botwin, MD, and Bharat C. Patel, MD

From: Deuk Spine Institute, Titusville, FL.

Dr. Botwin is a Physiatrist of the Interventional Pain Physician program at the Deuk Spine Institute, Titusville, FL, and Fellowship Director, Florida Spine Institute, Clearwater, FL.

Dr. Patel is a Physiatrist of the Deuk Spine Institute, Titusville, FL

Address correspondence:  
Kenneth P. Botwin  
Florida Spine Institute  
Medical Staff Office  
2250 Drew Street  
Clearwater, FL 33765  
E-mail: cbarragan@floridaspineinstitute.com

Disclaimer: There was no external funding in the preparation of this manuscript.

Conflict of interest: None.

Manuscript received: 07/30/2007  
Accepted for publication:  
10/11/2007

Free full manuscript:  
[www.painphysicianjournal.com](http://www.painphysicianjournal.com)

**Background:** Myofascial pain is defined as pain that originates from myofascial trigger points in skeletal muscle. It is prevalent in regional musculoskeletal pain syndromes, either alone or in combination with other pain generators. The myofascial pain syndrome is one of the largest groups of under-diagnosed and under-treated medical problems encountered in clinical practice. Trigger points are commonly seen in patients with myofascial pain that can be responsible for localized pain in the affected muscles as well as referred pain patterns. Correct needle placement in a myofascial trigger point is vital to prevent complications and improve efficacy of the trigger point injection to help reduce or relieve myofascial pain. In the obese patients, these injections may not reach the target tissue. In the cervicothoracic spine, a misguided or misplaced injection can result in a pneumothorax. Here, we review an electromyographically guided trigger point injection technique to avoid this potential pitfall.

**Methods:** Using a disposable Teflon coated hypodermic injection needle attached to an electromyography (EMG) machine, a trigger point injection can be performed utilizing electromyographic guidance. This guidance by observing motor unit action potentials (MUAPs) on the EMG screen helps confirm the needle placement to be within the muscle tissue and not in an adipose tissue or any other non-musculature structure.

**Results:** The technique is simple when performed by a pain management specialist who has electromyographic training.

**Conclusion:** This technique helps confirm proper needle placement within the cervicothoracic musculature in an obese patient in whom the musculature is not readily palpated. This, thus, reduces the potential for a pneumothorax by an improperly placed injection.

**Key words:** Trigger point injection, myofascial pain, electromyography.

**Pain Physician 2007; 10:753-756**

**M**yofascial pain syndrome is one of many painful conditions of the musculoskeletal system. It constitutes some of the most important chronic problems encountered in a clinical practice (1). Myofascial pain is defined as pain that originates from myofascial trigger points in skeletal muscle. It is prevalent in regional musculoskeletal

pain syndromes, either alone or in combination with other pain generators. The myofascial pain syndrome is one of the largest groups of under-diagnosed and under-treated medical problems encountered in clinical practice. An appropriate evaluation and management of myofascial pain is an important part of musculoskeletal rehabilitation of regional axial and

limb pain syndromes (2). A myofascial trigger point is a hyperirritable spot, usually within a taut band of skeletal muscle, which is painful on compression and can give rise to characteristic referred pain, motor dysfunction, and autonomic phenomena (1,3). Trigger points have been proven causes of myofascial pain that are responsible for neck and back pain. Trigger points can be activated with local pressure or stretch of the tissue. They can also cause referred pain in a specific dermatomal and myotomal pattern. Trigger points may be relieved through noninvasive measures, such as spray and stretch, transcutaneous electrical stimulation, physical therapy, and massage. Invasive treatments for myofascial trigger points include injections with local anesthetics, corticosteroids, botulism toxin, or dry needling (1-7). Precise injections into the trigger points are vital in helping inactivate them.

Trigger points are usually palpated during physical examination before and while injecting them. It is very hard and sometimes impossible to do this in the obese patients. At times, in these patients it is dif-

icult to know if the needle is properly placed within the muscle tissue. This can perhaps lead to an increase in complications in these patients when performing trigger point injections in the posterolateral neck and thoracic musculature. This can result in an improperly placed injection.

A Medline/EMBASE review of literature did not reveal a description of this technique. Thus, this paper is the first to describe this new and previously unreported technique of trigger point injection utilizing electromyographic guidance in the cervicothoracic musculature of obese patients.

## METHODS

After marking the trigger point injection site with a marking pen, the skin over that area is prepared by applying betadine and then alcohol. After that, a 25G 2-inch or 3.5-inch Teflon coated hypodermic needle with injection port (Part #101335, XLTEK, Oakville, Ontario, Canada LGH5S1) is inserted at the marked trigger point (Fig. 1). After connecting the injecting needle to the EMG machine, ground and active electrodes are

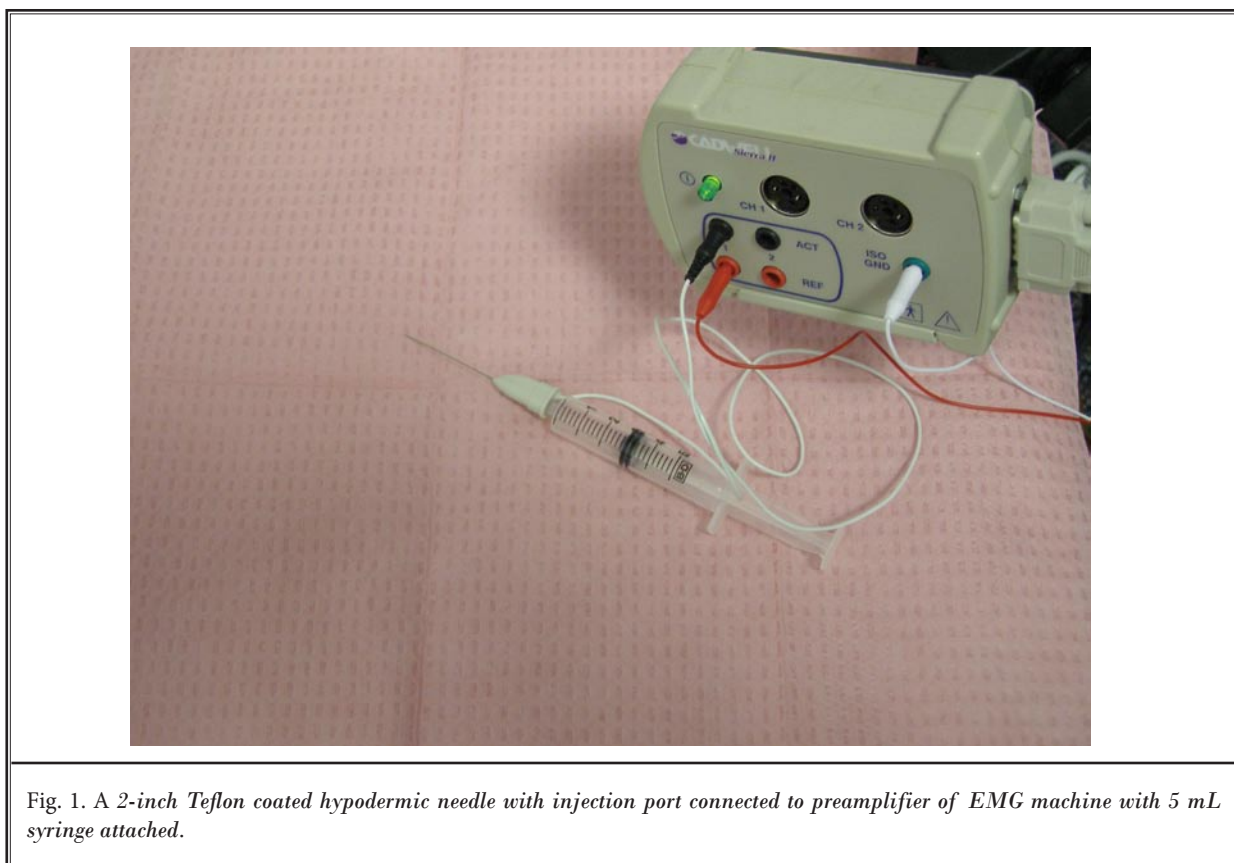


Fig. 1. A 2-inch Teflon coated hypodermic needle with injection port connected to preamplifier of EMG machine with 5 mL syringe attached.

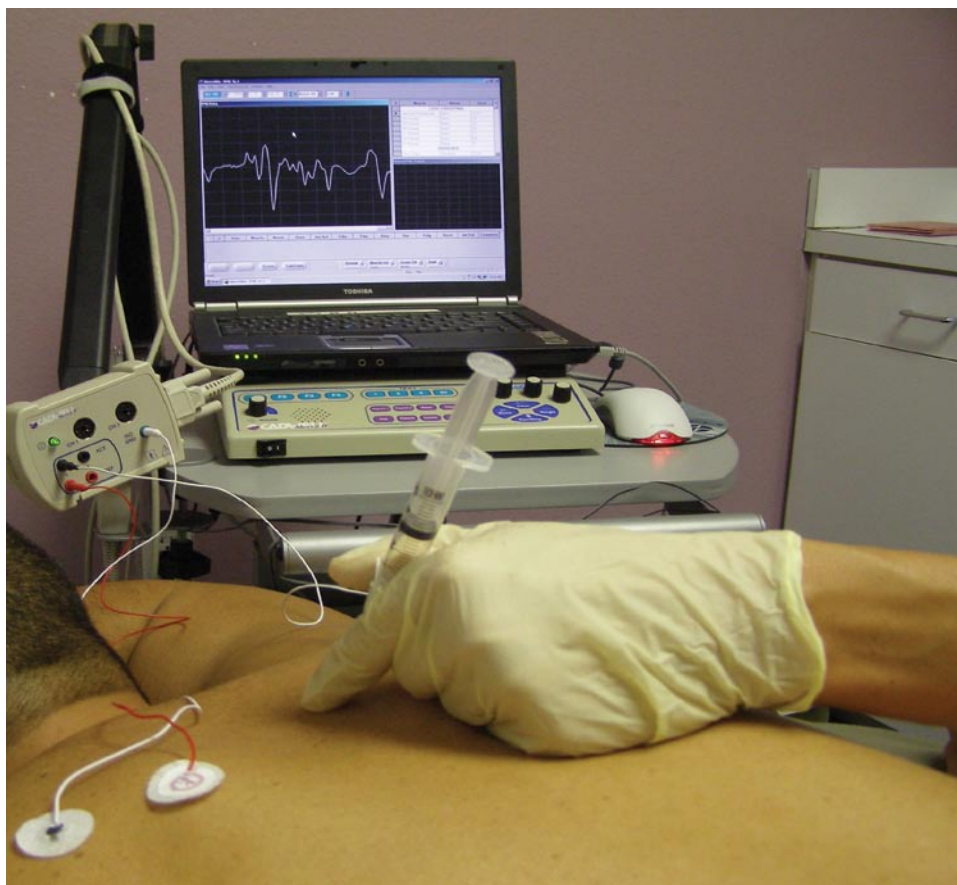


Fig. 2. A 2-inch Teflon coated hypodermic needle with injection port connected to preamplifier of EMG machine with 5 mL syringe attached. Both ground and reference electrodes are placed on the patient. Motor units observed on the EMG machine.

placed on the patient's body while the other ends are connected to the EMG machine. The needle is then advanced slowly while the EMG machine (Cadwell SIERRA II, Cadwell Laboratories, 909 North Kellogg Street, Kennewick, WA 99336) is on until motor unit action potentials are noted. Needle placement in the specific muscle to be injected can be confirmed by asking the patient to activate that particular muscle while observing an increase in motor unit action potentials (MUAPs) on the EMG machine (Fig. 2). Once the proper localization is achieved, the injection with or without an injectate can be performed and then the needle is removed. Pressure is applied at the injection site to ensure proper homeostasis. A bandage can be applied.

## DISCUSSION

Trigger point injections have been proven to be useful to relieve myofascial pain in patients suffering

from neck and low back pain (4-6,8-14). There are 2 possible problems when performing trigger point injections in obese patients. First, in such patients, it is difficult at times to determine whether the needle tip is in the muscle or in the adipose tissue. If the needle is not in the muscle, the injection will not relieve any pain and symptoms related to a trigger point. Secondly, trigger point injections in cervical and thoracic spine in all patients can be associated with the possibility of a pneumothorax (15-18). Electromyographic guidance has been recommended during the cervicothoracic musculature botulinum toxin A injection for the treatment of muscle spasticity in post-stroke patients, cerebral palsy, and dystonia for precise localization of a specific muscle as well as the motor point in that muscle by observing MUAPs and end-plate potentials before injecting (19-28). We have described a similar technique that can be useful when performing trigger point injections in

the cervical crevice thoracic musculature in obese patients. This helps to avoid the potential complication of a pneumothorax as well as to assure proper placement in the musculature.

Clinical studies need to be done to evaluate the effectiveness of this technique compared with the conventional technique of injection without electromyographic guidance.

## CONCLUSION

An electromyographically guided trigger point injection technique confirms accurate needle placement in the cervicothoracic musculature of obese patients.

This helps to avoid injection into adipose tissue which may minimize the injection's effectiveness. The Electromyographic guidance also helps to avoid the potential complication of a pneumothorax when injecting trigger points in the cervicothoracic musculature. Thus, it also increases the efficacy of the trigger point injections to reduce or relieve myofascial pain.

## ACKNOWLEDGMENTS

Our appreciation goes to Dr. Rafael Santiago and Carol Barragan for their help in the preparation of this manuscript.

## REFERENCES

- Lavelle ED, Lavelle W, Smith HS. Myofascial trigger points. *Med Clin North Am* 2007; 91:229-239.
- Borg-Stein J, Simons DG. Focused review: Myofascial pain. *Arch Phys Med Rehabil* 2002; 83(3 Suppl 1):S40-47, S48-49. Review.
- Simons DG, Mense S. Diagnosis and therapy of myofascial trigger points. *Schmerz* 2003; 17:419-424. Review. German.
- Simons DG, Travell JG. Myofascial origins of low back pain. Principles of diagnosis and treatment. *Postgrad Med* 1983; 73:66, 68-70, 73.
- Travell JG, Simond DG. *Myofascial Pain and Dysfunction: The Trigger Point Manual: The Lower Extremities. Vol. 1.* Baltimore, MD: Williams & Wilkins, 1983.
- Travell JG, Simond DG. *Myofascial Pain and Dysfunction: The Trigger Point Manual: The Upper Extremities. Vol. 1.* Baltimore, MD: Williams & Wilkins, 1983.
- Fischer AA. Local injections in pain management. Trigger point needling with infiltration and somatic blocks. *Physical Med Rehabilitation Clinic North America* 1995;6:851-870.
- Graboski CL, Gray DS, Burnham RS. Botulinum toxin A versus bupivacaine trigger point injections for the treatment of myofascial pain syndrome: A randomized double blind cross over study. *Pain* 2005; 118:170-175.
- Hamada H, Moriwaki K, Shiroyama K, Tanaka H, Kawamoto M, Yuge O. Myofascial pain in patients with postthoracotomy pain syndrome. *Reg Anesth Pain Med* 2000; 25:302-305.
- Staud R. Are tender point injections beneficial: The role of tonic nociception in fibromyalgia. *Curr Pharm Des* 2006; 12:23-27.
- Borg-Stein J, Stein J. Trigger points and tender points: One and the same? Does injection treatment help? *Rheum Dis Clin North Am* 1996; 22:305-322.
- Smith HS, Audette J, Royal MA. Botulinum toxin in pain management of soft tissue syndromes. *Clin J Pain* 2002; 18(6 Suppl):S147-154.
- Hong CZ, Hsueh TC. Difference in pain relief after trigger point injections in myofascial pain patients with and without fibromyalgia. *Arch Phys Med Rehabil* 1996; 77:1161-1166.
- Kamanli A, Kaya A, Ardicoglu O, Ozgocmen S, Zengin FO, Bayik Y. Comparison of lidocaine injection, botulinum toxin injection, and dry needling to trigger points in myofascial pain syndrome. *Rheumatol Int* 2005; 25:604-611. Epub 2004 Sep 15.
- Simond DG, Travell JG, Simons LS. *Travell and Simon's Myofascial Pain and Dysfunction: The trigger point manual. 2nd Ed.* Baltimore, MD: Williams & Wilkins, 1999:94-173.
- Alvarez DJ, Rockwell PG. Trigger points: Diagnosis and management. *Am Fam Physician* 2002; 65:653-660.
- Shafer N. Pneumothorax following "trigger point" injection. *JAMA* 1970; 213:1193.
- Nelson LS, Hoffman RS. Intrathecal injection: Unusual complication of trigger-point injection therapy. *Ann Emerg Med* 1998; 32:506-508.
- Klein AW, Mantell A. Electromyographic guidance in injecting botulinum toxin. *Dermatol Surg* 1998; 24:1184-1186.
- O'Brien CF. Injection techniques for botulinum toxin using electromyography and electrical stimulation. *Muscle Nerve Suppl* 1997; 6:S176-180.
- Childers MK. The importance of electromyographic guidance and electrical stimulation for injection of botulinum toxin. *Phys Med Rehabil Clin N Am* 2003; 14:781-792.
- Finsterer J, Fuchs I, Mamoli B. Automatic EMG-guided botulinum toxin treatment of spasticity. *Clin Neuropharmacol* 1997; 20:195-203.
- Molloy FM, Shill HA, Kaelin-Lang A, Karp BI. Accuracy of muscle localization without EMG: Implications for treatment of limb dystonia. *Neurology* 2002; 58:805-807.
- Comella CL, Buchman AS, Tanner CM, Brown-Toms NC, Goetz CG. Botulinum toxin injection for spasmodic torticollis: Increased magnitude of benefit with electromyographic assistance. *Neurology* 1992; 42:878.
- Barbano RL. Needle EMG guidance for injection of botulinum toxin. Needle EMG guidance is useful. *Muscle Nerve* 2001; 24:1567-1568.
- Lang AM. Botulinum toxin type A therapy in chronic pain disorders. *Arch Phys Med Rehabil* 2003; 84(3 Suppl 1):S69-73.
- Lang AM. Botulinum toxin therapy for myofascial pain disorders. *Curr Pain Headache Rep* 2002; 6:355-360.
- Lang AM. A preliminary comparison of the efficacy and tolerability of botulinum toxin serotypes A and B in the treatment of myofascial pain syndrome: A retrospective, open-label chart review. *Clin Ther* 2003; 25:2268-2278.