

Case Series

Hydrocodone Use and Sensorineural Hearing Loss

Tang Ho MD¹, Jeffrey T. Vrabec MD², and Allen W. Burton MD³

From: ¹Baylor College of Medicine, Houston, TX; ²University of Texas MD Anderson Cancer Center, Houston, TX.
¹Drs. Ho and Vrabec are with the Bobby R. Alford Department of Otolaryngology, Head and Neck Surgery, Baylor College of Medicine, Houston, TX; ²Dr. Burton is with the Department of Anesthesiology and Pain Medicine, University of Texas MD Anderson Cancer Center, Houston, TX.

Address Correspondence:
Jeffrey T. Vrabec, MD
6550 Fannin St., SM1727
Houston, TX 77030-3498
E-mail: jvrabec@bcm.tmc.edu

Funding: None.
Conflict of Interest: None.
Manuscript received on: 01/18/2007
Accepted for publication on:
02/22/2007

Free Full manuscript
www.painphysicianjournal.com

Background: The hydrocodone/acetaminophen combination is one of the most commonly used analgesic preparations. Isolated incidences of suspected association between hydrocodone abuse and rapidly progressive hearing loss have been reported. In this study, we describe the clinical characteristics of 5 patients presenting with progressive hearing loss and a history of hydrocodone use.

Methods: Patients presenting with rapidly progressive bilateral hearing loss who had a documented history of hydrocodone use were selected for the study. The presentation, audiologic findings, associated comorbidities, and treatment outcomes were reviewed

Results: All patients displayed rapidly progressive sensorineural hearing loss without vestibular symptoms. Hearing loss was asymmetric in 3 patients at initial presentation, but progressed to profound loss, usually within months. Steroid treatment has no effect on the progression of the hearing loss. The admitted quantity of hydrocodone consumed ranged from 10 to 300 mg per day. Hepatitis C was the most common comorbidity, present in 60% of the patients. All patients underwent cochlear implantation with satisfactory results.

Conclusions: The chronic use of hydrocodone can be associated with progressive sensorineural hearing loss. Successful auditory rehabilitation can be achieved with cochlear implantation. Genetic polymorphisms of drug metabolizing enzymes as well as associated comorbidities such as hepatitis C infection may be significant in the development of hydrocodone ototoxicity, though additional investigations are necessary.

Key words: hydrocodone, sensorineural hearing loss, cochlear implant

Pain Physician 2007; 10:467-472

The combination of hydrocodone and acetaminophen is commonly prescribed for relief of acute and chronic pain. According to the National Center for Health Statistics 2002 data, acetaminophen and hydrocodone are first and fourth on the list of most prescribed generic drugs during US ambulatory health care visits, with more than 75 and 32 million citations respectively (1).

Hydrocodone is effective both as an antitussive and narcotic analgesic. Commonly reported adverse reactions to the hydrocodone/acetaminophen combination include dizziness, nausea, vomiting, drowsiness, and euphoria. More serious side effects such as respiratory depression and mood disturbance are rare. As with all narcotics, hydrocodone can lead to psychological and physical dependence. It is the most widely prescribed opioid in the U.S. in addition to being one of the most widely abused prescription drugs (2).

Hearing loss is an infrequently recognized adverse side effect of hydrocodone use with only a few case reports to date (3,4). Indeed, association between any other narcotic and hearing loss is also restricted to a few case reports (5-7). In this study we describe the clinical characteristics of 5 patients who presented with progressive sensorineural hearing loss suspected to be related to their history of chronic hydrocodone/acetaminophen use.

METHODS:

All patients in the series presented to the otology clinic with the chief complaint of progressive hearing loss and were evaluated by the senior neurotologist. All 5 subjects underwent a complete history and physical examination as well as additional diagnostic work-up to identify the likely cause for the sensorineural hearing loss. The hearing loss was further evaluated by serial audiograms confirming severe to profound progressive sensorineural hearing loss in all patients. Additional workup included serological studies to

evaluate for autoimmune etiologies as well as radiological evaluation including computed tomography imaging of the temporal bone and magnetic resonance imaging.

Relevant patient information regarding use of hydrocodone/acetaminophen combination including amount, duration, and associated neurotological symptoms were elicited either at the time of initial presentation or during follow-up visits. All patients subsequently underwent cochlear implantation for the acquired sensorineural hearing loss.

RESULTS:

The age of the patients at the time of presentation ranged from 28 to 57 years in this series, with 3 male and 2 female subjects. The admitted amount of hydrocodone consumption varied widely ranging from 10 to 300 mg per day. The duration of use prior to hearing loss also varied widely ranging from months to years (Table I). Only one patient was using the drug with physician supervision. There was no prior history of ear disease or hearing loss in any patient. The initial audiogram usually showed a moderate hearing loss. As hearing loss rapidly progressed, communication was severely affected as these individuals uniformly had little, if any, lip reading ability (Fig. 1). Cessation of drug use was reported by 4 of the patients, though this is difficult to confirm. There was no spontaneous recovery of hearing in any case after reported cessation of drug use.

All patients presented for evaluation of progressive bilateral sensorineural hearing loss, although hearing loss was asymmetrical in 3 patients. Tinnitus was the most commonly reported associated symptom, present in 3 patients. Except for history of hydrocodone use, no clear etiology or predisposing factor for hearing loss could be identified in these patients. Four patients had complete autoimmune serology panel studies that were unrevealing except one patient was noted to have a

Table 1. Patient demographics.

Patient	Sex	Age	Amount Hydrocodone Used	Duration Of Use	Indication for Hydrocodone	Duration of Hearing Loss	Associated Symptoms
1	F	28	>50 mg/day	>2 years	None, illicit use	2 years	Tinnitus
2	M	47	Unknown	>1 year	None, illicit use	4 – 5 months	Tinnitus
3	M	49	≈100 mg/day	1 – 2 months	None, illicit use	1 – 2 months	None
4	F	48	10 mg/day	>5 years	Chronic back pain?	2 months	Headache
5	M	57	200 – 300 mg/day	Unknown	None, illicit use	10 years	Tinnitus

mildly elevated rheumatoid factor level. Rheumatologic consultation and additional workup failed to identify any systemic autoimmune process. Four patients were treated with steroids with no improvement in hearing. Brain and temporal bone imaging studies were within normal limits in all patients.

Hepatitis C was the most commonly documented comorbid condition, seen in 3 patients (Patients 2, 3, 4). One patient had documented cirrhosis (Patient 2) as a result of the hepatitis and was considered a possible candidate for liver transplant. Use of interferon for treatment of hepatitis C has been associated with sudden hearing loss (8,9). However, only one patient had been treated with interferon, and this was 4 years

prior to the onset of hearing loss.

All patients progressed to a severe to profound sensorineural hearing loss and underwent unilateral cochlear implantation. All patients tolerated the cochlear implantation procedure well without complications. Post-operative follow-up period ranged from 2 to 21 months with a mean follow-up period of 10 months. Post-operative performance on Consonant-Nucleus-Consonant (CNC) monosyllabic words score ranged from 18% to 56%, the hearing-in-noise test (HINT) score ranged from 78% to 100%, and the CUNY sentence recognition test score ranged from 95% to 100% for the three subjects that completed the evaluation.

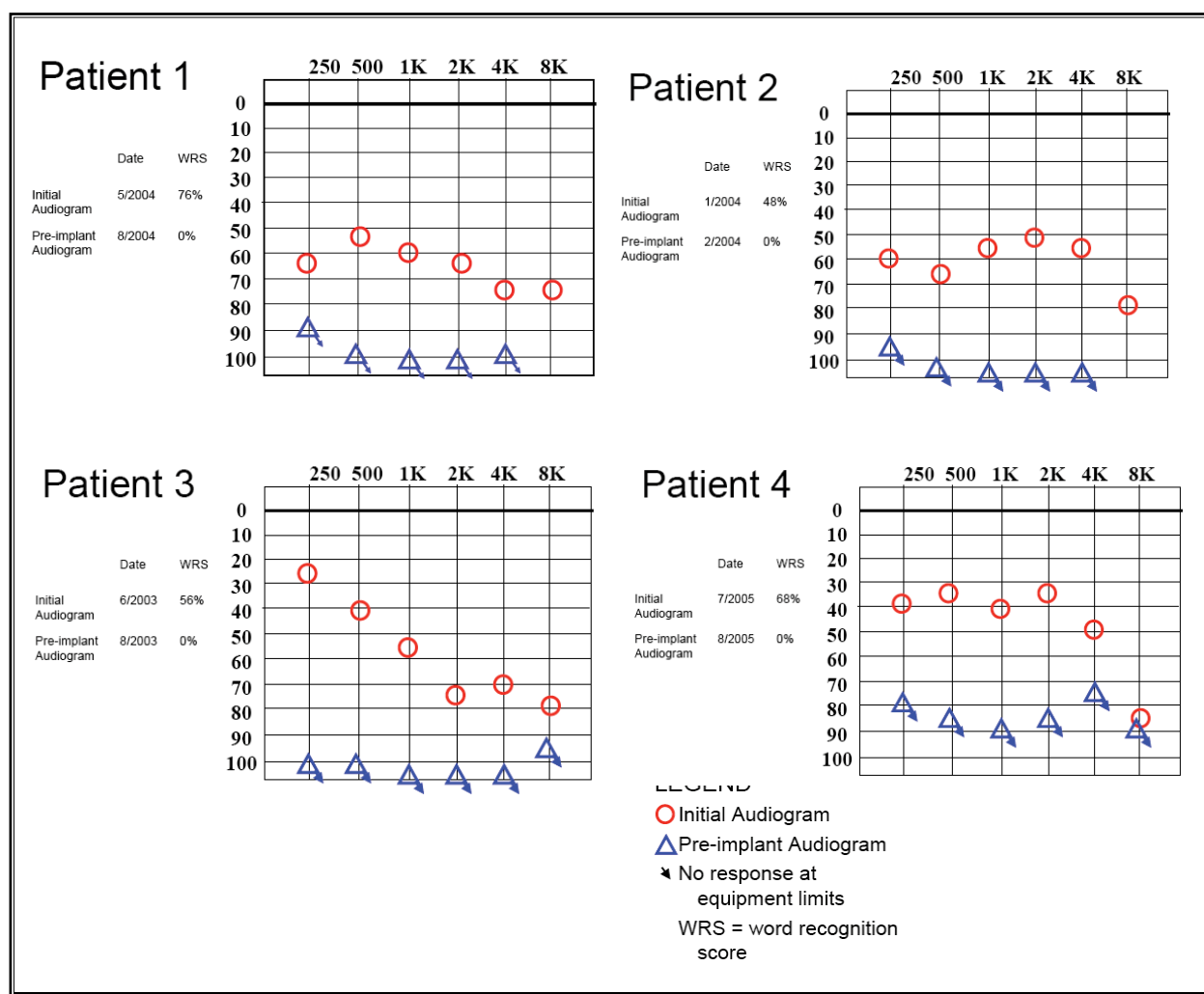


Fig. 1. Comparison of Audiological Data (for better-hearing ear)*
 * initial audiological data unavailable for patient 5

Discussion:

Hydrocodone and acetaminophen are widely used medications and rapidly progressive sensorineural hearing loss is very rare, thus the possibility of a chance association is raised. Unilateral sudden onset sensorineural hearing loss has a population prevalence of approximately 1:10,000 persons per year (10). Bilateral cases account for only about 1 - 2% of sudden losses (11). Even in a busy otological practice, patients with progression of hearing loss by 10 - 20 dB in one month are rarely encountered.

The rarity of rapidly progressive bilateral sensorineural hearing loss results in a relatively short, but ominous, differential diagnosis. Intracranial infections or malignancies, severe head trauma, and multiple sclerosis are typically accompanied by other neurological deficits. Individuals with otosyphilis and autoimmune inner ear disease commonly report disequilibrium or vertigo and will display recovery of hearing or arrest of progression with appropriate treatment including corticosteroids. Multiple medications have been implicated in producing hearing loss, though aminoglycoside antibiotics are probably the most common. Onset of hearing loss in conjunction with administration of the drug is expected in these cases. History, laboratory testing, imaging, and response to steroid treatment exclude these possibilities.

There are 2 published reports on suspected hydrocodone/acetaminophen combination abuse-related progressive sensorineural hearing loss (3,4). Substantial variation is seen in the amount of hydrocodone/acetaminophen consumed as well as the timing of hearing loss onset. Thus, it is unlikely that ototoxicity is a predictable consequence of a specific cumulative dose. Furthermore, sudden hearing loss is not reported in the treatment of pain due to advanced malignancy, when daily intake of hydrocodone can commonly exceed 30 mg/day. We also observed sensorineural hearing loss in a patient who reportedly had taken the medication within recommended dosages (e.g. 10 mg/day) for years.

The likely explanation for hydrocodone/acetaminophen ototoxicity is altered pharmacokinetics due to genetic factors or comorbid conditions. While standard drug dosages are based on pharmacokinetic data obtained from randomly selected healthy individuals, inherent differences between individuals will likely result in variations in drug metabolism. This disparity can be attributed to genetic variations in drug transport proteins, drug receptors, and/or genetic polymor-

phisms of drug metabolizing enzymes. These metabolizing enzymes can be broadly categorized into type I oxidative enzymes such as cytochrome P450 (CYP) and phase II detoxifying enzymes such as glutathione S-transferase (12).

Hydrocodone is a semi-synthetic opioid compound, structurally related to codeine. It has a relatively low binding affinity for the μ opiate receptor. Structurally, hydrocodone is distinguished from codeine by the keto group at the C6 position instead of a hydroxyl group, thus preventing it from undergoing extensive conjugation as in codeine. However, like codeine, hydrocodone primarily undergoes O-demethylation at the C3 position by CYP2D6 enzyme and forms hydromorphone, which has significantly higher affinity for the μ opiate receptor than the parent compound (13,14). Hydrocodone also undergoes N-demethylation by the CYP3A4 to norhydrocodone, although the extent and a significance of this metabolic pathway has not been well characterized. It has been estimated that approximately 7% of the Caucasian population has an inactive CYP2D6 phenotype; in those with a functional CYP2D6 enzyme the enzymatic activity can vary tremendously between individuals. Recently it has been suggested that genetic polymorphisms of the CYP2D6 enzyme can have an impact on the metabolism and therapeutic efficacy of hydrocodone (15).

It is also surmised that individuals with genetically altered CYP2D6 activity will manifest increased toxicity of drugs metabolized via this enzyme. Jannetto et al postulated that individuals with reduced CYP2D6 activity (poor metabolizers) would be at greater risk of toxicity, but when they examined 26 deaths due to oxycodone overdose they did not find an increased prevalence of poor metabolizers compared to a randomly selected control population (16). Alternatively, de Leon et al described the adverse reactions to hydrocodone in ultrarapid metabolizers (17). Neither finding affirms or excludes the possibility of heightened sensitivity to opiates resulting in ototoxicity in genetically predisposed individuals. It is conceivable that genetic variations in hydrocodone metabolism secondary to enzyme polymorphisms in CYP2D6 or CYP3D4 may predispose certain individuals to adverse reactions to the drug, which would be consistent with the sporadic nature of the observed association between hearing loss and hydrocodone exposure. Future research may include sequencing of drug metabolizing enzymes for detection of the presence of genetic polymorphisms in affected individuals.

Since hydrocodone is only available in the US in combination with other drugs, the possibility of acetaminophen contributing to the observed hearing loss cannot be completely ruled out. Although hepatotoxicity with acetaminophen overdose is a well-recognized adverse effect, we are not aware of any report of associated hearing loss in the literature. The co-administration of acetaminophen may also alter hydrocodone metabolism. High dose acetaminophen (>6 gm/d) is associated with degradation of CYP3A4 which would impair metabolism of hydrocodone to norhydrocodone and thus would increase hydrocodone metabolism to hydromorphone (18).

Interestingly, hepatitis C was the most commonly observed comorbidity in this series with three patients testing positive for HCV serology. The finding may not be entirely innocuous. HCV infection can cause significant liver damage as evidenced by our patient with cirrhosis. Alteration in activity of CYP enzymes may also occur in HCV infection associated with production of liver-kidney-microsome autoantibody type 1 (LKM1). The LKM1 autoantibody targets CYP2D6, though the resulting effect on enzyme activity is uncertain (19).

The site of lesion for hydrocodone/acetaminophen toxicity is undetermined, but the lack of significant vestibular abnormality and satisfactory auditory rehabilitation with cochlear implantation suggests isolated cochlear involvement. The distribution of opioid receptors in the inner ear is described in rodents, with the μ receptor typically found in spiral and Scarpa's ganglia (20,21). The delta and kappa receptors are seen in hair cells. Additional knowledge of the distribution of opioid receptors in the human inner ear is

required to further formulate a hypothesis regarding opioid toxicity.

From our review, the following guidelines may be used for diagnosis of hydrocodone/acetaminophen induced hearing loss. First, the clinician should document bilateral rapidly progressive hearing loss. All patients in this series displayed a rapid and unrelenting progression to profound loss, typically within a few months. No patient had a pure tone audiometry in either ear of better than 85 dB. Secondly, there was uniform absence of vestibular symptoms. Thirdly, there was no response to oral steroids and often continued progression of hearing loss in spite of this treatment. Next, there were no symptoms or laboratory evidence of intracranial infection or concurrent autoimmune disease with the exception of possible HCV induced autoimmune hepatitis. Finally, prolonged daily use of hydrocodone or oxycodone, or high doses over a short interval preceding onset of hearing loss, are documented.

CONCLUSION

In this study, we report the possible association between progressive sensorineural hearing loss and hydrocodone/acetaminophen use. A clinical picture of rapid bilateral hearing loss and concurrent narcotic use should raise suspicion of possible toxicity. Successful auditory rehabilitation can be achieved with cochlear implantation. Genetic polymorphisms of drug metabolizing enzymes as well as associated comorbidities such as hepatitis C infection may be significant in the development of hydrocodone/acetaminophen ototoxicity, although additional experimental investigations are necessary.

REFERENCES

- Schappert SM, Burt CW. Ambulatory care visits to physician offices, hospital outpatient departments, and emergency departments: United States, 2001-02. *Vital Health Stat* 13 2006; 1-66.
- Cicero TJ, Inciardi JA, Munoz A. Trends in abuse of Oxycontin and other opioid analgesics in the United States: 2002-2004. *J Pain* 2005; 6:662-672.
- Oh AK, Ishiyama A, Baloh RW. Deafness associated with abuse of hydrocodone/acetaminophen. *Neurology* 2000; 54:2345.
- Friedman RA, House JW, Luxford WM, Gherini S, Mills D. Profound hearing loss associated with hydrocodone/acetaminophen abuse. *Am J Otol* 2000; 21:188-191.
- Ramsey BC. Complete nerve deafness after abuse of co-proxamol. *Lancet* 1991; 338:446-447.
- Harell M, Shea JJ, Emmett JR. Total deafness with chronic propoxyphene abuse. *Laryngoscope* 1978; 88:1518-1521.
- Lupin AJHS. Inner ear damage related to propoxyphene ingestion. *Can Med Assoc J* 1976; 114:596.
- Kanda Y, Shigeno K, Kinoshita N, Nakao K, Yano M, Matsuo, H. Sudden hearing loss associated with interferon. *Lancet* 1994; 343:1134-1135.
- Formann E, Stauber R, Denk DM, Jessner W, Zollner G, Munda-Steindl P, Gangl A, Ferenci P. Sudden hearing loss in patients with chronic hepatitis C treated with pegylated interferon/ribavirin. *Am J Gastroenterol* 2004; 99:873-877.
- Byl FM Jr. Sudden hearing loss: eight years' experience and suggested prognostic table. *Laryngoscope*. 1984; 94(5 Pt 1):647-661.
- Shaia FT, Sheehy JL. Sudden sensorineural hearing impairment: a report of 1,220 cases. *Laryngoscope*. 1976; 86(3):389-398.
- Rogers JF, Nafziger AN, Bertino JS, Jr. Pharmacogenetics affects dosing, efficacy, and toxicity of cytochrome P450-metabolized drugs. *Am J Med* 2002; 113:746-750.
- Chen ZR, Somogyi AA, Reynolds G, Bochner F. Disposition and metabolism

- of codeine after single and chronic doses in one poor and seven extensive metabolisers. *Br J Clin Pharmacol* 1991; 31:381-390.
14. Chen ZR, Irvine RJ, Somogyi AA, Bochner F. Mu receptor binding of some commonly used opioids and their metabolites. *Life Sci* 1991; 48:2165-2171.
 15. Hutchinson MR, Menelaou A, Foster DJ, Coller JK, Somogyi AA. CYP2D6 and CYP3A4 involvement in the primary oxidative metabolism of hydrocodone by human liver microsomes. *Br J Clin Pharmacol* 2004; 57:287-297.
 16. Jannetto PJ, Wong SH, Gock SB, Laleli-Sahin E, Schur BC, Jentzen JM. Pharmacogenomics as molecular autopsy for postmortem forensic toxicology: genotyping cytochrome P450 2D6 for oxycodone cases. *J Anal Toxicol* 2002;26:438-447.
 17. de Leon J, Dinsmore L, Wedlund P. Adverse drug reactions to oxycodone and hydrocodone in CYP2D6 ultrarapid metabolizers. *J Clin Psychopharmacol* 2003; 23:420-421.
 18. Zhang QX, Melnikov Z, Feierman DE. Characterization of the acetaminophen-induced degradation of cytochrome P450-3A4 and the proteolytic pathway. *Basic Clin Pharmacol Toxicol* 2004; 94:191-200.
 19. Zachou K, Rigopoulou E, Dalekos GN. Autoantibodies and autoantigens in autoimmune hepatitis: important tools in clinical practice and to study pathogenesis of the disease. *J Autoimmune Dis* 2004; 1:2.
 20. Jongkamonwivat N, Phansuwan-Pujito P, Sarapoke P, Chetsawang B, Casalotti SO, Forge A, Dodson H, Govitrapong P. The presence of opioid receptors in rat inner ear. *Hear Res* 2003; 181:85-93.
 21. Popper P, Cristobal R, Wackym PA. Expression and distribution of mu opioid receptors in the inner ear of the rat. *Neuroscience* 2004; 129:225-233.