

Literature Review

Fulminant Cervical Epidural Hematomas: Why Do They Happen, How Can We Minimize Their Occurrence, and What Can We Do When They Do Occur? A Perspective

Standiford Helm, MD¹, Mahendra Sanapati, MD², Carl Noe, MD³, and Gabor Racz, MD⁴

From: ¹University of California, Irvine; ²Pain Management Centers of America, Evansville IN; ³University of Texas Southwestern Medical Center, Dallas, TX; ⁴Texas Tech University Health Sciences Center, Lubbock, TX

Address Correspondence:
Standiford Helm, MD
Department of Anesthesiology
and Perioperative Care,
University of California, Irvine
UCI Health Center for Pain
and Wellness, Gottschalk
Medical Plaza
1 Medical Plaza Dr
Irvine, CA 92617
E-mail:
drhelm@thehelmcenter.com

Disclaimer: There was no external funding in the preparation of this manuscript.

Conflict of interest: Each author certifies that he or she, or a member of his or her immediate family, has no commercial association (i.e., consultancies, stock ownership, equity interest, patent/licensing arrangements, etc.) that might pose a conflict of interest in connection with the submitted manuscript.

Manuscript received: 02-27-2023
Revised manuscript received:
03-09-2023
Accepted for publication:
05-16-2023

Free full manuscript:
www.painphysicianjournal.com

Background: Epidural hematomas after appropriately performed cervicothoracic interlaminar epidural injections have been associated with the rapid onset of neurological symptoms and devastating outcomes, despite prompt identification and treatment. Anticoagulation issues were initially felt to be the problem, but the occurrence of fulminant hematomas in patients without coagulation forced a reassessment of the causes and responses to this problem.

Objectives: To evaluate why fulminant epidural hematomas occur after cervicothoracic epidural injections, with a literature review to survey knowledge about them in the surgical literature, and to offer comments as to what the interventional pain physician can do to minimize their occurrence.

Study Design: A perspective piece with a literature review.

Settings: Interventional pain management practices.

Methods: A perspective on the issue of fulminant cervical hematomas and an associated literature review.

Results: Anatomical studies show that there are no meaningful arteries in the posterior epidural spaces which would explain hematomas. There is a dense posterior intravertebral epidural venous plexus at C1 and also at C6-C7 extending caudally to the upper thoracic region. A venous origin has been questioned because venous pressure was felt to be too low to explain the bleeding. The surgical literature, going back 80 years, contains numerous reports of engorged epidural veins causing radiculopathy and myelopathy. These engorged veins can occur in the presence or absence of spinal pathology. There is no known means of reliably identifying these engorged veins; they have been mistaken for disc protrusions. At least one report documents massive bleeding from these veins. Studies done on a feline model of cervical stenosis suggest that the epidural pressure can reach arterial levels.

Limitations: No direct documentation of arterialized posterior intravertebral epidural venous pressures has been made. While anatomical anomalies and degeneration contribute to epidural scarring, we do not have a full understanding as to the cause of arterialization of veins, particularly in younger patients with no obvious intraspinal pathology.

Conclusion: Fulminant cervicothoracic epidural hematomas after an epidural injection appear to arise from the unintentional and unavoidable puncture of arterialized veins with sharp needles. A technique to open a path out from the foramen so that the blood can escape is described. Alternatively, providers should consider injecting more cephalad, between C2-C3 and C6-C7 in the cervical spine, or an alternative procedure, such as a selective nerve root injection. A cervical transforaminal approach should only be attempted with a blunt needle, which cannot enter an artery. Should symptoms occur, cervical flexion rotation maneuvers should be implemented while awaiting prompt transfer to a facility where an appropriate diagnosis and treatment can be provided.

Key words: Cervical epidural hematoma, cervical epidural injection, posterior intravertebral venous plexus, arterialized epidural veins, pressurized epidural veins

Pain Physician 2023; 26:449-456

Fulminant cervicothoracic epidural hematomas after interlaminar injections have been well documented in the literature. Multiple cases have described the rapid onset of symptoms, including paralysis, within one to 2 hours or less of the injection (1-8). Spontaneous epidural hematomas have shown similar rapid onset (9,10). Even with prompt surgical decompression, permanent neurological symptoms have occurred. Considerable effort has been spent attempting to identify factors which would put the patient at risk for these catastrophic events.

Anticoagulation has been a major focus to try to explain the hematomas (3,11-14). However, despite meticulous attention to anticoagulation profiles, cervical hematomas have been reported, suggesting that anticoagulation is not the issue (15,16). Supporting the absence of a relationship between cervical epidural hematoma occurrence and anticoagulation is the report of Kaye et al (13) of 8 cases of hematomas after cervical epidurals in patients who were on no anticoagulant medications. The exception among anti-inflammatories is aspirin, which is associated with an increased risk of bleeding (12,13).

Both “single shot” injections utilizing a Tuohy needle, and radiopaque catheter techniques (TheraCath, Arrow International Inc.), have been reported to be associated with fulminant cervical hematomas (4,17).

Some have argued that the risks of cervical epidural steroid injections are not worth the benefit (18). This position is not supported by systematic reviews of the literature (19).

OBJECTIVES

The objective of this perspective piece is to examine the causes of fulminant cervical hematomas with the goal of better understanding how to minimize their occurrence and how to best treat them should they occur.

STUDY DESIGN

This is an expert perspective analysis of the clinical problem of fulminant hematomas, with an associated literature review to better inform practitioners as to the cause of this complication.

SETTING

The setting in which we looked at fulminant cervicothoracic hematomas was in interventional pain management practices. These complications can also occur spontaneously, after acupuncture, during cervical manipulation under anesthesia, or after spinal cord stimulator placement.

METHODS

Published and unpublished cases of epidural hematomas were reviewed, along with the associated literature to date regarding factors influencing their occurrence. A review of the associated surgical literature was also performed.

RESULTS

The failure of diligent efforts to determine the cause of fulminant epidural hematomas suggests the need to look for anatomic, rather than procedural, causes. Helm, Noe, and Racz, in a letter to the editor (20), suggested that cervical venous anatomy explained the basis for these hematomas.

Given the rapid onset of compressive hematomas, an arterial source would seem likely. Unnithan (21) concluded that, because cervical venous pressure was low, spontaneous cervical epidural hematomas were likely arterial. Given that neither the radicular/radiculomedullary arteries nor the arteries in the posterior longitudinal ligament would be violated during interlaminar epidural injections, there is no anatomic basis to invoke arterial bleeding.

If a low pressure vein were the cause of the bleeding, then one would expect the vein to be compressed, and the bleeding stopped, as cervical intrathecal pressure is felt to be higher than venous (22). While small arteriovascular malformations have been identified in the posterior dura (23), Groen et al (24,25) opined that these small malformations are not sources of cervicothoracic epidural bleeding; the source instead being venous. Supporting Groen et al's (24,25) opinion that veins are the source of spontaneous epidural hematomas is the observation that these hematomas occur most frequently in the areas where posterior epidural veins are most prominent. Fedor et al (26) performed a review of cases of spontaneous epidural hematoma subsequent to Groen et al's review, concurring with the opinion that most bleeds were venous in origin, noting that dysfunction could, as after cervical epidural injections, occur within minutes of the onset of symptoms.

Epidural venous anatomy was first described by Breschet in 1829 (27). No further advances were made until Batson, in 1940 (28), described connections between pelvic and vertebral venous systems by injecting dye into the deep dorsal vein. He suggested that the vertebral venous system be added as a fourth system of veins, in addition to the caval, the portal, and the pulmonary. His work provided the anatomic basis for the metastatic spread of pelvic tumors to

the spine and of vertebral osteomyelitis from bladder infections.

In 1961, Clemens (29) published a study of the venous system of the spinal canal, performed by injecting polymer into the veins. He stated that the posterior epidural veins became prominent at C6-C7 and extended down to the upper thoracic posterior epidural space, precisely the region where interventional pain management physicians are recommended to enter for cervical injections.

Groen et al (25), in attempting to understand the basis for spontaneous spinal epidural hematomas, refined Clemens' technique and confirmed his findings. Based on the studies of these investigators, the epidural veins are valveless and, like the azygos vein, connect the inferior and superior vena cava, but, by virtue of being in the spinal canal, are protected from changes in thoracoabdominal pressure. The epidural veins consist of the internal vertebral venous plexus, surrounding the dura anteriorly and posteriorly, the basivertebral veins in the vertebrae, and the external venous plexus, surrounding the vertebral column. The posterior internal vertebral plexus is of interest regarding the cause of fulminant epidural hematomas after cervical epidural injections.

The anterior internal vertebral plexus is largely covered by the posterior longitudinal ligament. The anterior plexus is quite regular and consists of 2 longitudinal trunks converging at each vertebral body with each other and with the basivertebral veins to form a dense plexus. Sagittal veins also exist, around the foramina, but have not been separately named.

The posterior internal venous plexus lies in the epidural fat and has 2 longitudinal trunks. While there is significant inter-individual variation, generally there are prominent bridging horizontal veins at C1, C6 and C7, with few veins in between. In the upper thoracic region, there is a dense plexus of inverted "V" shaped bridging veins. These venous structures are shown, using Breschet's 1829 drawings, in Fig. 1 and in Fig. 2, as found by Clemens in his polymer study (29). Breschet's findings correlate closely with Clemens' and Groen's.

The anterior and posterior venous plexuses exist as different structures; the anterior plexus does not transition posteriorly at C6-C7 to form the posterior plexus.

Clemens (29) documented that the volume of the vertebral veins is larger than the contributing arteries. Ruiz et al (30) showed that while the cerebral

veins drain through the internal jugular system when supine, when erect, drainage is through the vertebral venous system. In dogs, the internal vertebral plexus can take up to 30% of the epidural space (31). These

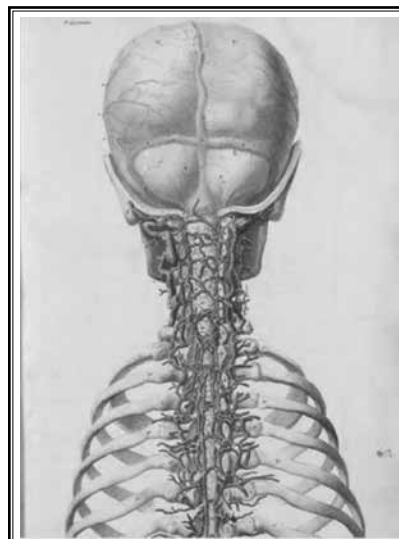


Fig 1. *Posterior intervertebral venous plexus. From Breschet G. Recherches anatomiques, physiologiques et pathologiques sur le système veineux et spécialement sur les canaux veineux des os. Rouen frères, 1829.*

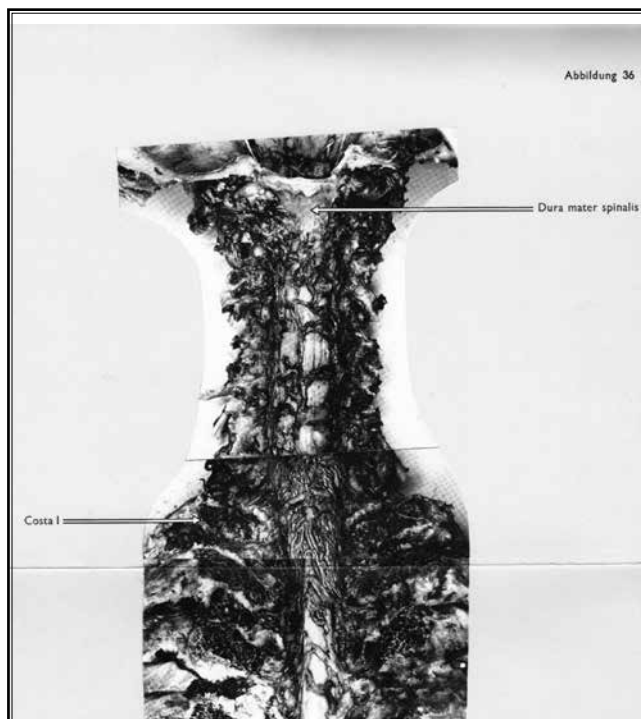


Fig. 2 *The posterior internal vertebral venous plexus. From Clemens H.J. Die Venensysteme der Menschlichen Wirbelsäule. Walter de Gruyter & Co., Berlin, 1961.*

findings show the capacity of the vertebral venous system. As a large capacity, valveless venous system, the vertebral venous plexus has been suggested to serve as a large capacity fluid reserve, holding drainage from the cranial vault and adjusting venous drainage with changes in posture; it also has a role in brain and spinal cord cooling (32).

The presence of posterior epidural veins in the lower cervical and the upper thoracic region does not in and of itself explain the occurrence of fulminant epidural hematomas. If these veins are to be considered sources of rapid bleeding, they would need to be under high pressure.

There is ample evidence in the surgical literature of high pressure dorsal internal vertebral plexus epidural veins. As early as 1941, Cohen (33) described epidural varices causing sciatica, a finding reiterated by Gumbel in 1969 and Zarski in 1978 (34,35). Dickman (36), in describing a cervicothoracic myelopathy caused by epidural veins, observed that abnormalities such as dysraphia and other spinal abnormalities were the most common causes of epidural venous engorgement, but mechanical obstruction, as from disc herniation, trauma, or obesity, were also causes (37). Importantly, he also noted that a diagnosis is difficult. Carpenter (32) has cited both compression of the inferior vena cava, for whatever reason, and foraminal stenosis as additional possible causes of epidural venous engorgement.

Ciceri et al (37) suggested that Hirayama's disease (38), which is anterior horn degeneration associated with neck flexion, might be caused by cervical venous engorgement associated with shifting venous draining from the jugular vein to the epidural system with neck flexion. Yokote et al (39) confirmed the presence of dilated epidural veins as a cause of Hirayama's disease. Brandicourt et al (40) successfully treated Hirayama's disease by decompressing the epidural veins via laminectomy.

Latrogenic venous engorgement from overdrainage of cerebrospinal fluid causing cervical myelopathy has also been reported (41). Symptomatic epidural venous engorgement can also occur after spontaneous intracranial hypotension (42).

Hoyland et al., in 1989 (43), published a large cadaver study showing the frequent occurrence of congestion and dilatation of the foraminal veins, with consequent compressive changes of the nerve roots. Another study (44) later confirmed their findings in vivo, finding venous congestion and related changes on specimens taken during discectomy. Ooi et al (45),

using endoscopy, documented the engorgement of epidural veins with exercise in patients with stenosis causing intermittent claudication.

Wong et al (46) surgically identified 2 cases of engorged epidural veins mistaken as lumbar disc protrusions. They documented epidural engorgement with the presence of spinal pathology, such as stenosis and disc protrusions, and also, importantly, in the absence of pathology (46). Slin'ko and Al-Qashqish (47) also resolved radiculopathy by decompressing epidural veins and again confirmed the presence of engorged veins in both the presence and absence of pathology. Dudeck et al (48), Endres (49), Omid-Kashani et al (50), Bursalı et al (51), Jeong et al (52), and Shin et al (53) reported similar findings. Ju et al (54) found that engorged veins could remain after surgical decompression.

Demaeral et al (55), Hammer et al (56), and Paksoy and Gormus (57) reported sciatica caused by dilated epidural veins. Krishnan et al (58) reported cervical myelopathy caused by venous engorgement due to impaired venous drainage.

That epidural venous congestion can occur in the absence of pathology is demonstrated by Bapat and Metkar's report (59) of a 21-year-old with cervicothoracic venous congestion leading to quadriplegia.

Wnuk et al (60) noted that pathology of the intravertebral venous system was seldom considered to be a cause of clinical symptoms. Their case report of venous engorgement causing radicular symptoms is interesting because during decompression, the dilated veins at L2 caused "massive and persistent bleeding" which they ultimately were able to control (60).

Symptomatic posterior intravertebral epidural venous plexus engorgement, arising in both the presence and absence of spinal or other pathology, is well documented, as is the ability of that engorgement to cause massive bleeding. A reasonable hypothesis would be that such massive bleeding would be associated with elevated venous pressures. Supporting the hypothesis of arterialized pressures in the posterior internal vertebral plexus is a study by Wolfla et al (61). They evaluated ventral epidural pressures in a cat model of cervical central stenosis. They documented mean venous pressures of over 100 mm Hg with the neck neutral at 50% stenosis, rising to 140 mm Hg with extension and dropping to 85 mm Hg with flexion (61).

DISCUSSION

The posterior internal venous plexus can become

sufficiently engorged so as to cause radicular symptoms and myelopathy. These symptoms can occur in a wide variety of clinical settings, including no apparent intraspinal or other pathology. Foramina can be obstructed, preventing the outflow of blood which would avoid compression of the cord. The surgical literature documents massive bleeding from these veins. Animal studies suggest that they can be arterialized. Given these findings coupled with the absence of significant arteries in the epidural space, the evidence seems compelling that the cause of fulminant hematomas after otherwise uncomplicated cervicothoracic epidural injections is rupture of an arterialized vein. The risks present during an epidural injection are also present during spinal cord stimulator leads placements.

The associated literature also shows that these engorged, arterialized veins are not easily identified. There are no case reports of preprocedural magnetic resonance images showing enlarged veins.

Helm, Noe, and Racz (20) have provided several suggestions as to how to minimize, but not necessarily prevent, the occurrence of a hematoma. These suggestions include:

1. Enter at C7-T1 or higher, but below C1-C2. Injecting at C7-T1 and possibly C6-C7 has been recommended as a means of enhancing patient safety (61,62). Schultz et al (63) have recently shown that levels as cephalad as C2-C3 can be safely injected. Given the paucity of posterior intravertebral epidural veins cephalad to C6-C7, physicians who lack the necessary needles and catheter to open a foramen might consider more cephalad interlaminar cervical injections.
2. Avoid the use of sharp needles because of the risk of damage to the veins.
3. Ideally, a curved blunt (coudé) needle with a protruding second stylet (RX2™ Coudé®, Epimed) should be used. The protruding interlocked second stylet is inserted prior to rotating the needle tip after entry into the epidural space in order to protect veins from wide laceration from the needle's sharp tip.
4. A spring wound catheter should be passed through the foramen to open lateral runoff (Fig. 3). The maneuver of opening lateral runoff converts high-pressure veins into low-pressure veins because the epidural veins are interconnected. The problem is not blood, but blood under pressure. This approach does not run the risk of damaging radiculomedullary arteries as the catheter cannot

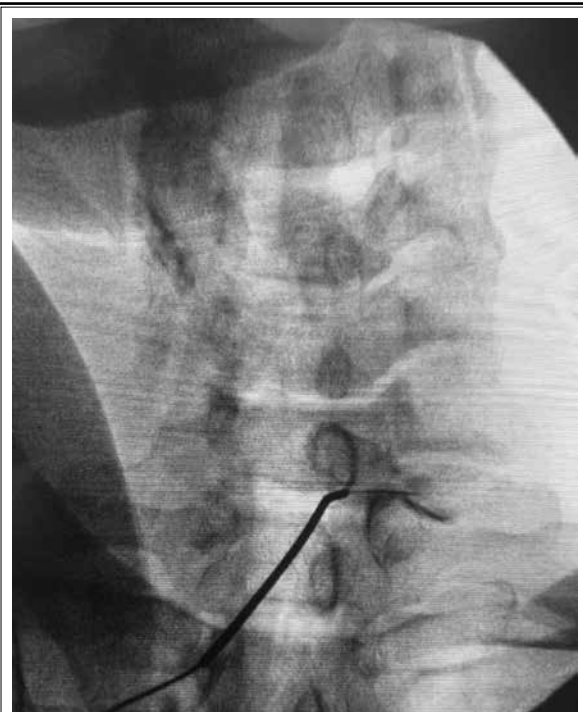


Fig. 3. Image of spring wound catheter placed through the right C7-T1 foramen, with contrast dye.

pierce the artery. There is also extensive experience with cervical neuroplasty documenting the safety of passing a spring wound catheter through the foramen. No cervical hematomas have been reported with cervical neuroplasty.

5. If a spring wound catheter is not available, consider entering above C6-C7 but not higher than C2-C3. A cervical transforaminal approach should be avoided because of the inability to reliably avoid entering an artery, unless a blunt needle, which has been shown to be unable to enter an artery, is used.
6. Should the patient report postprocedural pain or weakness, flexion rotation maneuvers of the head and neck should be started. Flexion rotation uses dural movement to force the accumulating blood away from its site of accumulation in the dural space and through the enlarged foramen to reduce pressure on the cord (65,66). Flexion rotation has been used in clinical practice, both during and after procedures, to allow injected fluid or blood to escape through the foramen. Cervical intraforaminal and extraforaminal supportive ligaments do not obstruct the flow of fluids. Thus, fluid pres-

sure can be relieved with foraminal enlargement, thereby protecting the cord. Flexion rotation should be started before signs of neural compromise are seen.

7. Diagnosing a cervical hematoma in the absence of motor changes can be challenging. A review of unpublished cases in the medicolegal arena suggests that a delay in surgical decompression can arise from delays in getting cervical imaging. These patients should be given the highest priority in obtaining cervical imaging. Physicians performing cervical epidural injections should consider collaborating with nearby facilities to develop protocols to enhance a rapid response to suspected cervical hematomas after epidural injections, including protocols for prompt access to imaging after the diagnosis is raised. If the facility is a trauma center, neurologic changes after a cervical epidural procedure should be given the same high priority as blunt or penetrating trauma.
8. Surgical decision is made after a review of the presence of blood on radiological imaging and symptoms and signs.

Limitations

While we found compelling evidence that the epidural veins in the cervicothoracic epidural space become arterialized, no direct measurements of those pressures have been made to confirm arterialization of the veins. Currently, we have an incomplete understanding as to the cause of arterialization of epidural veins, particularly in younger patients without obvious spinal pathology. Other factors such as the use of non-prescription anticoagulant drugs or foods, older age,

undiagnosed coagulopathy, liver and renal disease affecting anticoagulant clearance, and inaccurate self-reporting of anticoagulation medication usage could contribute to hematoma risk. Coagulation testing in these cases is usually performed after the procedure and treatment for bleeding, such as reversal agents, have been administered.

CONCLUSION

Fulminant cervical epidural hematomas can be neurological catastrophes. Compelling evidence supports their being caused by the puncture of an arterialized posterior internal venous plexus during the performance of the epidural injection. Currently, we have no technology which allows identification of these arterialized veins prior to the procedure and no risk factors have been identified which would allow stratification as to which patients are at risk. Hematoma occurrences have not been associated with any errors of omission or commission on the part of a performing physician.

We present here suggestions which will hopefully minimize cord compression occurrences by allowing the outflow of epidural blood through the foramen. In the event that there is any suggestion of compression, flexion and rotation of the head and neck is a simple way to open up the foramen and increase the chance of diverting blood out of the foramen. If symptoms continue, transfer to a facility with magnetic resonance imaging and spine surgery capability should be expedited.

If the equipment necessary to open the foramen is not available, physicians should consider injecting more cephalad in the cervical spine, where the posterior epidural intravertebral veins are scant.

REFERENCES

1. Swicegood JR, Manchikanti L, Benyamin RM, Hirsch JA. Two cases of acute epidural hematoma formation after cervical interlaminar epidural steroid injections. *Interv Pain Manag Rep* 2017; 1:27-32.
2. Swicegood JR, Manchikanti L, Benyamin RM, Hirsch JA. A report of acute thoracic epidural hematoma after interlaminar epidural injection. *Interv Pain Manag Rep* 2017; 1:33-38.
3. Jenkie EJ, Benyamin RM, Manchikanti L. Case report/Literature review: Fish oil as a potential contributor to epidural hematoma following cervical epidural steroid injection: A case report and focused literature review. *Interv Pain Manag Rep* 2017; 1:19-26.
4. Palmer E. Management of cervical epidural hematoma after cervical epidural steroid injection using a catheter technique. *Pain Med* 2020; 21:1301-1302.
5. LaBan MM, Kasturi G, Wang I-M. Epidural corticosteroid injections precipitating epidural hematomas with spinal paresis. *Am J Phys Med Rehabil* 2007; 86:166-167.
6. Beasley D, Goree JH. Cervical epidural hematoma following interlaminar epidural steroid injection via the contralateral oblique view in patient taking omega-3 fatty acids. *Reg Anesth Pain Med* 2019; 44:253-255.
7. Tan LA, Kasliwal MK, Deutsch H. Rapidly progressive quadriplegia secondary to cervical epidural hematoma-A rare complication of epidural injection. *Br J Neurosurg* 2014; 29:280-280.
8. Banik RK, Chen Chen CC. Spinal epidural hematoma after interlaminar cervical epidural steroid injection. *Anesthesiology* 2019; 13:1342-1343.
9. Fiani B, Jarrah R, Fiani NJ, Runnels J. Spontaneous cervical epidural

- hematoma: Insight into this occurrence with case examples. *Surg Neurol Int* 2021; 12:79.
10. Fukui MB, Swarnkar AS, RL W. Acute spontaneous spinal epidural hematomas. *Am J Neuroradiol* 1999; 20:1365-1372.
 11. Chang Chien C, McCormick Z, Araujo M, Candido KD. The potential contributing effect of ketorolac and fluoxetine to a spinal epidural hematoma following a cervical interlaminar epidural steroid injection: A case report and narrative review. *Pain Physician* 2014; 17:E385-E395.
 12. Narouze S, Benzon HT, Provenzano DA, et al. Interventional spine and pain procedures in patients on antiplatelet and anticoagulant medications (second edition): Guidelines from the American Society of Regional Anesthesia and Pain Medicine, the European Society of Regional Anaesthesia and Pain Therapy, the American Academy of Pain Medicine, the International Neuromodulation Society, the North American Neuromodulation Society, and the World Institute of Pain. *Reg Anesth Pain Med* 2018; 43:225-262.
 13. Kaye AD, Manchikanti L, Novitch MD, et al. Responsible, safe, and effective use of antithrombotics and anticoagulants in patients undergoing interventional techniques: American Society of Interventional Pain Physicians (ASIPP) guidelines. *Pain Physician* 2019; 22:S75-S128.
 14. De Cassai A, Correale C, Sandei L. Neuraxial and perineural bleeding after neuraxial techniques: An overview of the last year. *Eurasian J Med* 2020; 52:211.
 15. Benyamin RM, Vallejo RF, Wang V, et al. Acute Epidural Hematoma Formation in Cervical Spine After Interlaminar Epidural Steroid Injection Despite Discontinuation of Clopidogrel. *Reg Anesth Pain Med* 2016; 41:398-401.
 16. Loomba V, Kaveeshvar H, Dwivedi S. Paraplegia after thoracic epidural steroid injection. *A&A Prac* 2016; 7:118-121.
 17. McCormick ZL, Nelson A, Bhav M, et al. A prospective randomized comparative trial of targeted steroid injection via epidural catheter versus standard C7-T1 interlaminar approach for the treatment of unilateral cervical radicular pain. *Reg Anesth Pain Med* 2017; 42:82-89.
 18. Epstein NE. Major risks and complications of cervical epidural steroid injections: an updated review. *Surg Neurol Int* 2018; 9:86.
 19. Manchikanti L, Knezevic NN, Navani A, et al. Epidural interventions in the management of chronic spinal pain: American Society of Interventional Pain Physicians (ASIPP) comprehensive evidence-based guidelines. *Pain Physician* 2021; 24:S27-S208.
 20. Helm S, Noe CE, Racz G. Cervicothoracic epidural venous anatomy explains Fulminant hematomas. *Pain Med* 2020; 21:2613-2615.
 21. Unnithan AKA. A brief review of literature of spontaneous spinal epidural hematoma in the context of an idiopathic spinal epidural hematoma. *Egypt J Neurosurg* 2019; 34:21.
 22. Beatty RM, Winston KR. Spontaneous cervical epidural hematoma: A consideration of etiology. *J Neurosurg* 1984; 61:143-148.
 23. Lazorthes G, Manelfe C. La vascularisation artérielle de la dure-mère rachidienne. Les artères spiralées et les pelotons vasculaires [Arterial vascularization of spinal dura mater. Spiral arteries and vascular clusters] [Article in French]. *C R Acad Hebd Seances Acad Sci D* 1970; 217:88-91.
 24. Groen RJ, Ponsen H. Vascular anatomy of the spinal epidural space: Considerations on the etiology of the spontaneous spinal epidural hematoma. *Clin Anat* 1991; 4:413-420.
 25. Groen RJ, Groenewegen HJ, van Alphen HAM, Hoogland PV. Morphology of the human internal vertebral venous plexus: A cadaver study after intravenous Araldite CY 221 injection. *Anat Rec* 1997; 249:285-294.
 26. Fedor M, Kim ES, Ding K, Muizelaar JP, Kim KD. Spontaneous spinal epidural hematoma: A retrospective study on prognostic factors and review of the literature. *Korean J Spine* 2011; 8:272-282.
 27. Breschet G. Recherches anatomiques, physiologiques et pathologiques sur le système veineux et spécialement sur les canaux veineux des os: Rouen frères 1829. https://archive.org/details/BIUSante_00636
 28. Batson OV. The function of the vertebral veins and their role in the spread of metastases. *Ann Surg* 1940; 112:138-149.
 29. Clemens HJ. Die Venensysteme der Menschlichen Wirbelsäule. Walter de Gruyter & Co., Berlin, 1961.
 30. Ruiz DSM, Gailloud P, Rüfenacht DA, et al. The craniocervical venous system in relation to cerebral venous drainage. *Am J Neuroradiol* 2002; 23:1500-1508.
 31. Gomez Jaramillo MA. "Imaging Studies of the Canine Cervical Vertebral Venous Plexus." PhD Thesis, Virginia Polytechnic Institute 2005. <https://vtechworks.lib.vt.edu/bitstream/handle/10919/26055/gomezdisso12805.pdf>
 32. Carpenter K, Decater T, Iwanaga J, et al. Revisiting the Vertebral Venous Plexus—A Comprehensive Review of the Literature. *World Neurosurg* 2021; 145:381-395.
 33. Cohen I. Extradural varix simulating herniated nucleus pulposus. *J Mt Sinai Hosp* 1941; 8: 136-138
 34. Gümbel U, Pia H, Vogelsang H. Lumbosacral vascular anomalies as the cause of ischialgia. [Article in German] *Acta Neurochir* 1969; 20:131-151.
 35. Zarski S, Styczyński T. Varicosity of the lower part of the vertebral canal. *Neurol Neurochir Pol* 1978; 12:67-72.
 36. Dickman CA, Zabramski JM, Sonntag VK, Coons S. Myelopathy due to epidural varicose veins of the cervicothoracic junction: Case report. *J Neurosurg* 1988; 69:940-941.
 37. Ciceri EF, Chiapparini L, Erbetta A, et al. Angiographically proven cervical venous engorgement: A possible concurrent cause in the pathophysiology of Hirayama's myelopathy. *Neuro Sci* 2010; 31:845-848.
 38. Hirayama K. Juvenile muscular atrophy of unilateral upper extremity (Hirayama disease)—Half-century progress and establishment since its discovery. *Brain Nerve* 2008; 60:17-29.
 39. Yokote A, Fukuhara K, Tsugawa J, Tsuboi Y. Juvenile muscular atrophy of the proximal upper extremity as so-called proximal-type hirayama disease: Case report and review of the literature. *Case Rep Neurol* 2019; 11:106-111.
 40. Brandicourt P, Sol J, Aldea S, et al. Cervical laminectomy and micro resection of the posterior venous plexus in Hirayama disease. *Neurochirurgie* 2018; 64:303-309.
 41. Wolfe SQ, Bhatia S, Green B, Ragheb J. Engorged epidural venous plexus and cervical myelopathy due to cerebrospinal fluid overdrainage: A rare complication of ventricular shunts. Case report. *J Neurosurg* 2007; 106:227-231.
 42. Albayram S, Wasserman BA, Yousem DM, Wityk R. Intracranial hypotension as a cause of radiculopathy from cervical epidural venous engorgement: Case report. *AJNR AM J Neuroradiol* 2002; 23:618-621.
 43. Hoyland JA, Freemont A, Jayson

- M. Intervertebral foramen venous obstruction. A cause of periradicular fibrosis? *Spine (Phila Pa 1976)* 1989; 14:558-568.
44. Cooper R, Freemont A, Hoyland J, et al. Herniated intervertebral disc-associated periradicular fibrosis and vascular abnormalities occur without inflammatory cell infiltration. *Spine (Phila Pa 1976)* 1995; 20:591-598.
 45. Ooi Y, Mita F, Satoh Y. Myeloscopic study on lumbar spinal canal stenosis with special reference to intermittent claudication. *Spine (Phila Pa 1976)* 1990; 15:544-549.
 46. Wong C-H, Thng PL, Thoo F-L, Low C-O. Symptomatic spinal epidural varices presenting with nerve impingement: report of two cases and review of the literature. *Spine (Phila Pa 1976)* 2003; 28:E347-E350.
 47. Slin'ko EI, Al-Qashqish II. Surgical treatment of lumbar epidural varices. *J Neurosurg* 2006; 5:414-423.
 48. Dudeck O, Zeile M, Poellinger A, Kluhs L, Ludwig W-D, Hamm B. Epidural venous enlargements presenting with intractable lower back pain and sciatica in a patient with absence of the infrarenal inferior vena cava and bilateral deep venous thrombosis. *Spine (Phila Pa 1976)* 2007; 32:E688-E691.
 49. Endres S. Epidural varicosis as a possible cause of radicular pain: A case report. *J Med Case Rep* 2011; 5:537.
 50. Omid-Kashani F, Hasankhani EG, Fathi M. Primary epidural varicosis as a rare cause of sciatica: A case report. *Iran J Med Sci* 2015; 40:541-543.
 51. Bursalı A, Goktug A, Guvenal AB, Yaman O. Lumbar epidural varix mimicking disc herniation. *J Korean Neurosurg Soc* 2016; 59:410-413.
 52. Jeong HJ, Sim WS, Park HJ, et al. Severe lumbar radiculopathy with epidural venous plexus engorgement in a morbidly obese pediatric patient: A case report. *Medicine (Baltimore)* 2019; 98:e16842.
 53. Shin J, Oh N, Huh J, et al. Radiculopathy caused by lumbar epidural varix. *J Neurocrit Care* 2020; 13:133-136.
 54. Ju J-H, Ha H-G, Jung C-K, Kim H-W, Lee C-Y, Kim J-H. Patterns of epidural venous varicosity in lumbar stenosis. *Korean J Spine* 2012; 9:244-249.
 55. Demaerel P, Petré C, Wilms G, Plets C. Sciatica caused by a dilated epidural vein: MR findings. *Eur Radiol* 1999; 9:113-114.
 56. Hammer A, Knight I, Agarwal A. Localized venous plexi in the spine simulating prolapse of an intervertebral disc: A report of six cases. *Spine (Phila Pa 1976)* 2003; 28:E5-E12.
 57. Paksoy Y, Gormus N. Epidural venous plexus enlargements presenting with radiculopathy and back pain in patients with inferior vena cava obstruction or occlusion. *Spine (Phila Pa 1976)* 2004; 29:2419-2424.
 58. Krishnan C, Malik J, Kerr D. Venous hypertensive myelopathy as a potential mimic of transverse myelitis. *Spinal Cord* 2004; 42:261-264.
 59. Bapat M, Metkar U. Epidural varix at the cervicothoracic junction: Unusual cause of quadriplegia: A case report. *Spine (Phila Pa 1976)* 2006; 31:E88-E90.
 60. Wnuk E, Maj E, Dziedzic T, Piętkowska AP. Spinal epidural venous plexus enlargement as a cause of neurologic symptoms: Vascular anatomy and MRI findings. *Neurol India* 2020; 68:1238-1241.
 61. Wolfla CE, Snell BE, Honeycutt JH. Cervical ventral epidural pressure response to graded spinal canal compromise and spinal motion. *Spine (Phila Pa 1976)* 2004; 29:1524-1529.
 62. Rathmell JP, Benzon HT, Dreyfuss P, et al. Safeguards to prevent neurologic complications after epidural steroid injections: consensus opinions from a multidisciplinary working group and national organizations. *Anesthesiology* 2015; 122:974-984.
 63. Benzon HT, Huntoon MA, Rathmell JP. Improving the safety of epidural steroid injections. *JAMA* 2015; 313:1713-1714.
 64. Schultz DM, Hagedorn JM, Abd-Elsayed A, Stayner S, Bakke C. Safety of interlaminar cervical epidural injections: Experience with 12,168 procedures in a single pain clinic. *Pain Physician* 2022; 25:49-58.
 65. Kitagawa T, Fujiwara A, Kobayashi N, et al. Morphologic changes in the cervical neural foramen due to flexion and extension: In vivo imaging study. *Spine (Phila Pa 1976)* 2004; 29:2821-2825.
 66. Racz GB, Apicella E, Vohra P. Collegial communication and problem-solving: Intraspinal canal manipulation. *Pain Pract* 2013; 13:667-670.