

## Retrospective Study

# e Quantity of Disc Removal and Radiological Outcomes of Percutaneous Endoscopic Lumbar Discectomy

Ji Han Heo, BS<sup>1</sup>, Chi Heon Kim, MD, PhD<sup>2,4</sup>, Chun Kee Chung, MD, PhD<sup>2,5</sup>, Yunhee Choi, PhD<sup>6</sup>, Young-Geun Seo, BS<sup>1</sup>, Dong Hoi Kim, BS<sup>1</sup>, Sung Bae Park, MD<sup>2,4,7</sup>, Jung Hyeon Moon, MD<sup>2,3</sup>, Won Heo, MD<sup>2,3</sup>, and Jong-Myung Jung, MD<sup>2,3</sup>

From: <sup>1</sup>Department of Medicine, Seoul National University College of Medicine, Seoul, South Korea; <sup>2</sup>Department of Neurosurgery, Seoul National University College of Medicine, Seoul, South Korea; <sup>3</sup>Department of Neurosurgery, Seoul National University Hospital, Seoul, South Korea; <sup>4</sup>Clinical Research Institute, Seoul National University Hospital, Seoul, South Korea; <sup>5</sup>Department of Brain and Cognitive Sciences, Seoul National University College of Natural Sciences, Seoul, South Korea; <sup>6</sup>Medical Research Collaborating Center, Seoul National University Hospital, Seoul, South Korea; <sup>7</sup>Department of Neurosurgery, Seoul National University Boramae Hospital, Borame Medical Center 20, Seoul, South Korea

Address Correspondence: Chi Heon Kim, MD, PhD  
Department of Neurosurgery,  
Seoul National University  
College of Medicine  
101 Daehak-Ro, Jongno-gu  
Seoul, 110-744, South Korea  
E-mail: chiheon1@snu.ac.kr

Disclaimer: See pg. E745.

Manuscript received:  
12-11-2016  
Accepted for publication:  
01-13-2017

Free full manuscript:  
www.painphysicianjournal.  
com

**Background:** Herniated intervertebral disc disease (HIVD) is a common cause of lower back and leg pain. Percutaneous endoscopic lumbar discectomy (PELD) is indicated when non-surgical treatments such as medication and interventions are intractable. Ruptured discs and loose fragments inside discs are removed during PELD. Nerve root decompression is usually assessed by visualizing the free movement of the traversing nerve root or epidural fat, the free passage of a probe into the epidural space, the depression of the annulus, and the removal of the expected ruptured discs and loose fragments based on preoperative magnetic resonance images (MRI). However, these criteria are subjective, and the quantity of the disc removal necessary for successful outcomes after PELD has not been investigated.

**Objectives:** The present study investigates the amount of discectomy of PELD and its clinical and radiological outcomes.

**Study Design:** A retrospective case study (IRB Number H-1611-015-803).

**Setting:** University Medical Center, Seoul, Korea.

**Methods:** PELD was performed in 109 consecutive patients (M:F = 53:56; mean age, 37.4 years) using the transforaminal or interlaminar route. Ruptured disc fragments were first removed in all patients, and the graspable loose fragments under the disc were removed. After surgery, all removed disc fragments were placed into disposable syringes and manually compressed to measure their volume. The volume of herniated disc outside the disc boundary was calculated in MRI. The measured and calculated disc volumes were retrospectively compared. Clinical success was defined as an improvement in both the Oswestry Disability Index (ODI) and leg pain, as well as no recurrent symptoms. Radiological success was defined as the disappearance of herniated disc material outside the disc boundary based on postoperative MRI taken within one day after surgery. The follow-up period was  $7.2 \pm 5.2$  months.

**Results:** Successful clinical outcomes were obtained in 96/109 (88.1%) patients in a median time of 3 months. Re-operation was performed in 3 patients due to recurrent discs in 2 patients and a residual disc in one patient. Predictors of clinical success were not identified, and the quantity of the removed disc was not associated with the clinical outcome.

Radiological success was achieved in 93/109 (85.3%) patients. Of 13 patients with radiological failure, 2 patients showed clinical failure. A logistic regression analysis showed that the relative volume of the removed disc (%) compared with the volume of preoperative herniated disc based on the MRI was the only significant predictor ( $P < 0.001$ ; OR = 0.96). When 100% of the calculated disc amount was removed during the operation, the probability of residual disc was 30%. When 131% of the calculated disc amount was removed, the probability of residual disc was 10%.

**Limitations:** This study employed a retrospective design, and its inherent selection bias and limited statistical power should be considered.

**Conclusions:** The amount of disc removal during PELD was not a significant predictor of clinical success after the primary ruptured fragments were removed. The relative volume of the removed disc based on the preoperative MRI might predict the postoperative MRI.

**Key words:** Disc, lumbar vertebra, discectomy, surgery, endoscopy, volume

Pain Physician 2017; 20:E737-E746

**H**erniated intervertebral disc disease (HIVD) is a common cause of lower back and leg pain. Discectomy is indicated when non-surgical treatments such as medication, injections, and interventions are intractable (1). Micro and open discectomies (ODs) are standard surgical techniques for lumbar HIVD (2). This primary surgical procedure involves the removal of herniated disc fragments and the decompression of the nerve root. However, the optimal amount of disc removal is controversial. Two predominant types of discectomy exist: subtotal discectomy (including formal annulotomy, endplate curettage, and the removal of all accessible fragments in the disc space) and limited discectomy (including the removal of the herniated and loose fragments inside the disc) (3-7). The interest in minimally invasive surgeries such as percutaneous endoscopic lumbar discectomy (PELD) has increased recently (8-11). The symptomatic ruptured disc fragments and loose fragments inside the disc are generally removed during PELD (12). Previous studies have demonstrated that the recurrence rate associated with PELD is not higher than that with OD (12-16). The decompression of the entire nerve root in OD is confirmed under direct vision (17). In contrast, visualizing the entire nerve root is not always possible using a transforaminal or interlaminar approach during PELD (12,18-20). The decompression of the nerve root is indirectly confirmed by visualizing the free movement of the traversing nerve root or epidural fat, the free passage of a probe into the epidural space, and the removal of expected ruptured discs and loose fragments based on preoperative magnetic resonance images (MRI) (12,18,19). However, these aforementioned criteria are subjective, and the optimal quantity of disc removal required for a successful outcome after PELD has not been reported. The present study investigates the amount of discectomy necessary for successful clinical and radiological outcomes after PELD.

## **METHODS**

The institutional review board approved this study (IRB No. H-1611-015-803). Patient medical records and images were reviewed retrospectively. The volumes of the removed disc fragments were measured after surgery beginning in August 2014, and all data were recorded prospectively using an electronic medical recording system (IRB No. 0507-509-153). In total, 138 patients underwent PELD for lumbar HIVD between August 2014 and May 2016. All patients reported in-

tractable radicular leg pain for more than 6 weeks of medical treatment (e.g., physical therapy, epidural injections, anti-inflammatory medications, and opioid analgesics) and HIVD based on MRI that corresponded to radicular symptoms (19). In total, 109 patients were included in the present study, and those with multiple-level surgeries (2 patients), fibromyalgia (2 patients), combined spinal metastasis (one patient), Parkinson's disease (2 patients), and previous lumbar surgery (19 patients) as well as those not providing sufficient data (3 patients) were excluded from this study. Table 1 describes the patient demographics. The follow-up period was  $7.2 \pm 5.2$  months (range, 3 – 24 months).

## **Surgical Method**

The surgical method was previously described in the literature (12,19,21). Briefly, PELD was performed via the transforaminal or interlaminar route. The percutaneous endoscopic interlaminar approach and discectomy (PEID) was preferred for all patients with HIVD at L5-S1, whereas the percutaneous endoscopic transforaminal approach and discectomy (PETD) was selected for patients with HIVD at L4-5 or above (21). The interlaminar approach was selected for patients with high-grade superior or inferior migration of the disc (18,21). One surgeon who performed more than 800 PELDs over the preceding 8 years performed all the surgeries (13,18,21,22). General anesthesia was induced, and intraoperative spontaneous electromyographic (EMG) monitoring was used. An 18-gauge needle was inserted into the neural foramen for PETD, and a guide wire was introduced after removing the stylet. The working channel was inserted over the dilator along the guide wire after making an incision in the skin (8 mm). An endoscope (Vertebris system; Richard Wolf, Knittlingen, Germany) was introduced into the neural foramen after the removal of the obturator. The ruptured disc fragments were identified as over or under the annulus in all cases and removed with forceps. The loose disc fragments under the ruptured disc fragments were removed using forceps. All of the graspable loose disc fragments were removed by changing the direction of the forceps and using flexible forceps. The decompression of the nerve root was indirectly confirmed by visualizing the free movement of the traversing nerve root or epidural fat, the free passage of a probe into the epidural space, and the removal of the expected ruptured discs and loose fragments based on preoperative MRI (12,18,19).

For PEID, the endoscope was introduced on the ligamentum flavum (LF) after the insertion of a dilator and working channel. An oblique trajectory was chosen in cases of highly migrated disc herniation based on the direction and amount of the migrated disc fragment. A small hole was created at the LF, and the working channel and endoscope were inserted into the spinal canal through the hole. The ruptured disc was visualized after the gentle retraction of the neural tissue using the working channel. The ruptured disc was removed first in all cases, and the loose fragments under the ruptured disc were removed. The working channel and endoscope were withdrawn after the completion of the PEID or PETD, and the skin was closed using 3-0 nylon sutures. Patients were encouraged to ambulate on the day of surgery and were discharged the following day.

### Disc Volume Measurement

Preoperative MRI were used to measure the volume of the herniated discs. The areas outside the disc boundary based on all axial images at the index level were measured using the tool in the image viewer (Fig. 1). The areas were summed and multiplied by the thickness of the gap in the axial image (Fig. 1, white arrow). An independent reviewer performed all measurements and analyses in a 150% magnified view using the measurement tools in the image archiving and communication software (Marosis, version 5483, Infinitt Healthcare, Seoul, Korea), which was performed in a Microsoft Windows environment (Microsoft Corp., Redmond, WA, USA) (23). The volumes of the removed disc materials were measured after surgery. All of the removed disc fragments were placed into 2.5- or 5-mL disposable syringes and manually compressed for volume measurements (Fig. 2). The indicator in the syringe was used to assess the volume of the disc materials.

### Outcomes

Clinical assessments were performed using a patient-reported outcome questionnaire that included a Korean version of the Oswestry Disability Index (K-ODI/45) (24), and visual analog pain scores for the back (VAS-back/10) and leg (VAS-leg/10) (25). All of the patients completed the questionnaires preoperatively (25). The patients were scheduled to visit the outpatient clinic 1, 3, 6, and 12 months postoperatively, and the questionnaires were completed in every visit. The minimal clinically important difference (MCID) for the VAS-leg and VAS-back was 2.5 out of 10, and the absolute score was less than 3.5 (26-28). Similarly, the MCID of

Table 1. Patient demographics.

Factors	
Age (years, mean $\pm$ SD)	37.4 $\pm$ 10.5 (range, 18 – 65)
Gender (F)	56 (52%)
Body mass index (kg/m <sup>2</sup> )	23.7 (17.6 – 35)
Symptom onset (months)	4 (0.1 – 24)
Weakness (yes)	38 (35%)
Smoking (yes)	27 (25%)
Straight leg raising test (°)	60 (10 – 90)
K-ODI (/45)	23 (8 – 45)
VAS-trunk (/10)	7 (0 – 10)
VAS-leg (/10)	7 (5 – 10)
Surgical level	
L1-2	1 (1%)
L3-4	6 (6%)
L4-5	67 (61%)
L5-S1	35 (32%)
Side (R:L:B)	48 (44%):55 (50%):6 (6%)
Multiple disc herniation	32 (29%)
Disc morphology (protrusion:extrusion/sequestration)	47 (43%):62 (57%)
High canal compromise (yes)	54 (50%)
Very high:high/low grade migration	6 (6%):103 (94%)
Pfirrmann grade (grade 1-3:4-5)	45 (41%):64 (59%)
Modic change (yes)	28 (26%)
Surgical method (PETD:PEID)	66 (61%):43 (39%)
Preoperative disc volume (mL)	0.9 (0.3 – 5.9)
Intraoperative removed disc volume (mL)	1.3 (0.4 – 5)
Removal percent (%)	142.2 (60.9 – 477.2)

Normally distributed variables are presented as the means  $\pm$  SD; non-normal continuous variables are presented as the medians (range); categorical variables are presented as frequencies (%).

Abbreviations: K-ODI, Korean Oswestry Disability Index; VAS, visual analogue pain score; PETD, percutaneous endoscopic transforaminal lumbar discectomy; PEID, percutaneous endoscopic interlaminar lumbar discectomy

K-ODI was 9 out of 45 (26-28). A successful clinical outcome was defined as an improvement in the VAS-leg and a K-ODI greater than the MCID without symptom recurrence during the follow-up period.

A successful radiological outcome was defined as the disappearance of the herniated discs without residual fragments outside the disc boundary based on postoperative MRI within 2 days after surgery. Another reviewer who was blinded to the clinical outcomes assessed the radiological outcomes (Fig. 3).

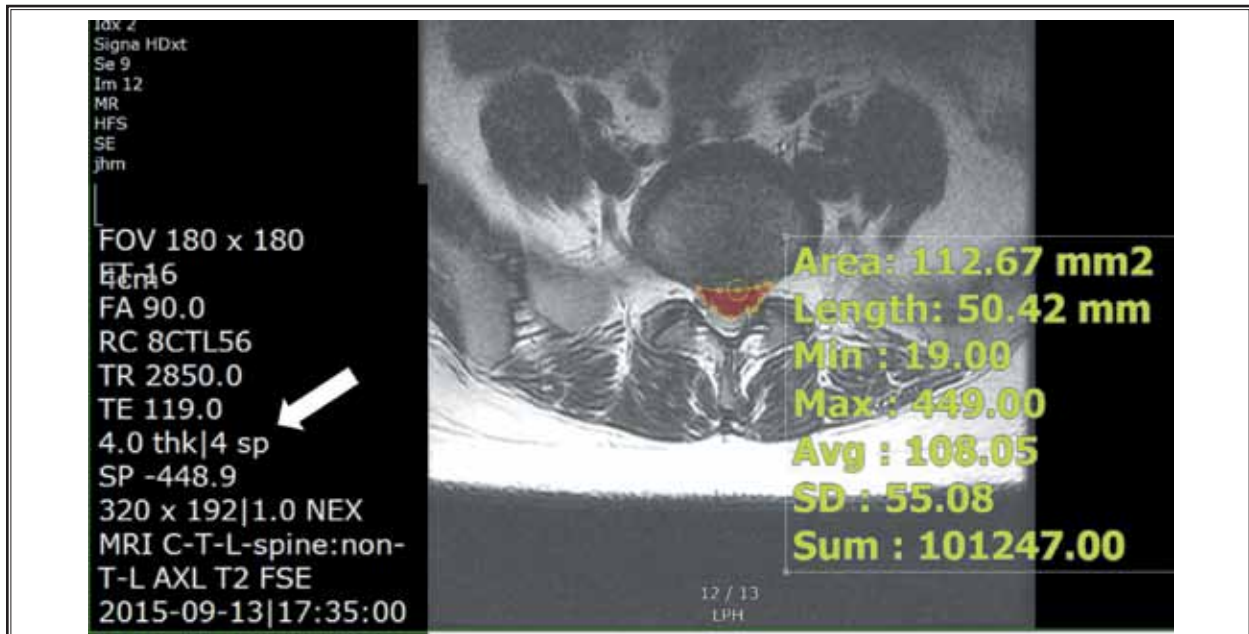


Fig. 1. Measurement of the herniated disc volume.

Preoperative T2-weighted axial MRI were used to calculate the volume of the herniated discs. The area outside the boundary of the original disc was measured for each axial image (a1, a2, a3, ...), and the added areas (a1 + a2 + a3 + ...) were multiplied by the length of the space between the images (white arrow). The volume of the herniated disc was 1.7 mL.

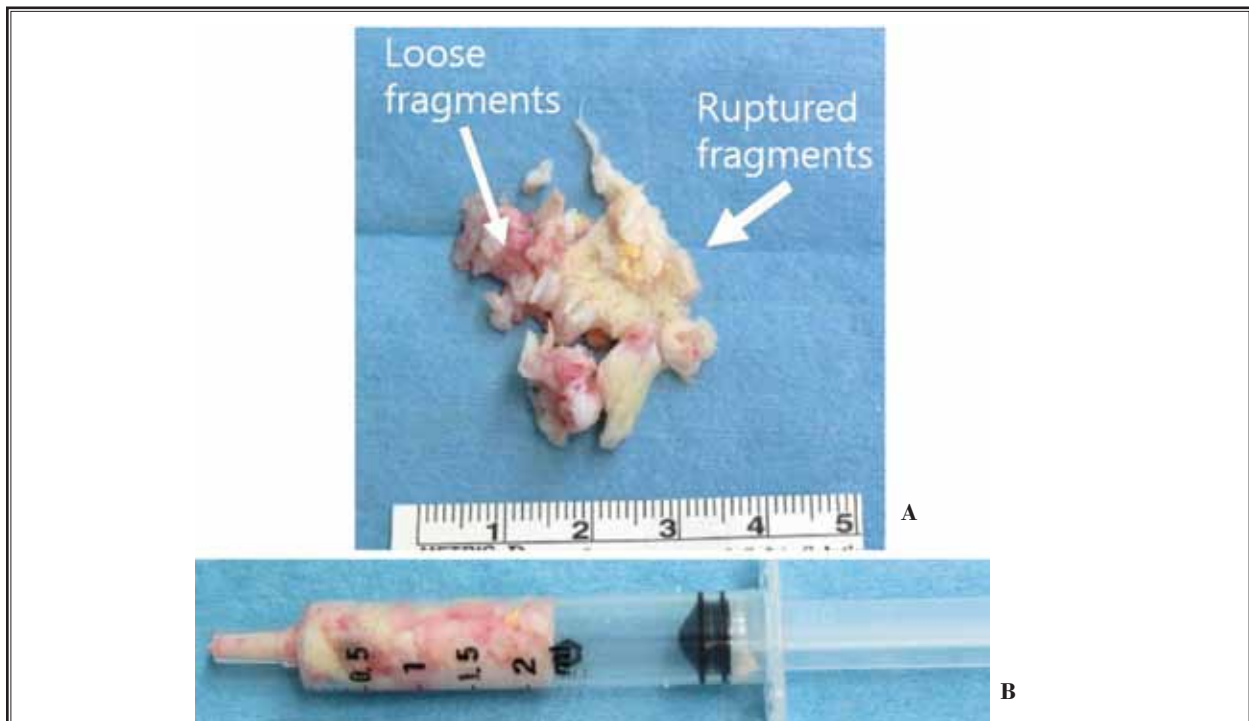


Fig. 2. Removed disc. A. The ruptured primary disc fragments were removed. The graspable loose fragments under the removed major disc fragments were removed with forceps. B. All of the removed disc material was placed into disposable syringes and manually compressed to measure the volume. The indicator shows 2.2 mL.



### Statistical Analyses

Various factors were considered for the analyses: age, gender, preoperative clinical parameters (i.e., K-ODI, VAS-leg and VAS-back), body mass index (BMI, kg/m<sup>2</sup>), symptom duration (months), the presence of weakness (less than manual motor power grade IV-/V), smoking status, limitations in the straight leg raising test, surgical level (L4-5, L5-S1, and other levels), side of the pain (right, left, and both), multiple-level disc herniation, disc morphology (protrusion vs. extrusion/sequestration) (29), the presence of very high-grade migrated disc herniation (yes vs. no) (18,20), centrally located high canal compromised (> 50%) disc herniation (20), Pfirrmann's grade at the index level (grade 1 – 3 vs. 4-5) (30,31), the presence of Modic change (yes vs. no) (32), surgical method (PETD vs. PEID), preoperative disc volume (mL), intraoperative removed disc volume (mL), and the relative removal amount (% , 100 x intraoperative removed disc volume/preoperative disc volume). We defined recurrence as “documented recurrent disc herniation based on MRI or computed tomography scan more than 3 months after the index operation at the same level or the same and contralateral side because of increased pain” (14). A continuous variable was summarized using the mean ± standard deviation (SD) for normal data or the median (range) for non-normal data. Normality was assessed using the Shapiro-Wilk test and a boxplot. Categorical data were summarized using frequencies (%). First, a univariate analysis using a Cox proportional hazard model was performed to identify the predictors of the time to clinical success. The linearity of the continuous variables and the proportional hazard assumption were checked using a restricted cubic spline function (33) and a Cox regression model with time varying coefficients, respectively. Factors with *P*-values less than 0.1 in the univariate analysis were considered in the multivariable analysis, and forward variable selection was used.

Second, a logistic regression model was used to analyze the predictors of radiological success, and factors with *P*-values less than 0.1 in the univariate analysis were considered for the multivariable analysis. The linearity of the continuous variable was examined using a restricted cubic spline function (33). The model adequacy was checked using the Hosmer-Lemeshow test and the area under the receiver operating characteristic (ROC) curve. All statistical analyses were performed using SPSS (version 18.0, IBM Corporation, Armonk, NY, USA), and significance was defined as *P* < 0.05 (2-tailed).

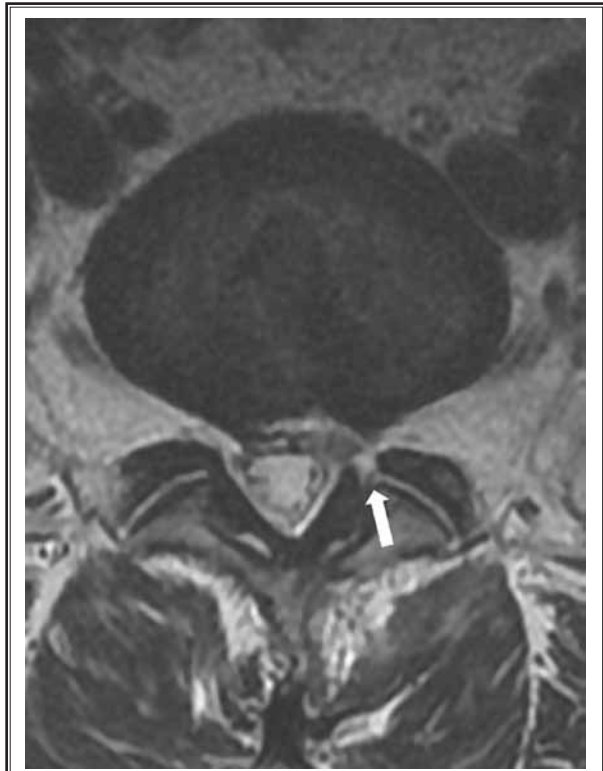

Fig. 3. *Radiological outcome assessments.*

Postoperative T2-weighted axial and sagittal MRI were used to assess the radiological outcomes. The disappearance of the disc materials outside the boundary of the disc was regarded a radiological success. Therefore, this figure reveals radiological success. The surgery was performed via the interlaminar route (thick arrow), and 129% of the herniated volume was removed.

### RESULTS

Successful clinical outcomes were obtained in 96/109 (88.1%) patients within a median of 3 months (95% CIs = 2.9 – 3.1; Fig. 3). Improvements in VAS-leg, VAS-back, and K-ODI greater than the MCID were observed in 99/109 (90.8%), 93/109 (85.3%), and 102/109 (93.6%) patients, respectively. The preoperative VAS-leg medians (range) were 7 (5 – 10) and 2 (0 – 8) at the last follow-up assessment. Similarly, the VAS-trunk median (range) changed from 7 (0 – 10) to 2 (0 – 8), and the K-ODI median changed from 23 (8 – 45) to 8 (0 – 29). The symptoms of 10 patients diagnosed with clinical failure were controlled using non-surgical treatments, but 3 patients underwent re-operation; 2 patients underwent PELD at 3 and 6 months, respectively, due to recurrent disc herniation, and one patient underwent OD because of a residual disc fragment. No factors significantly predicted successful clinical outcomes (Table

Table 2. Statistical analyses.

Factors	Clinical success HR (95% CIs)	Radiological success OR (95% CIs)
Age	1.01 (0.99 – 1.03)	1.01 (0.96 – 1.06)
Gender (F vs. M)	1.01 (0.68 – 1.51)	0.7 (0.24 – 2.03)
Body mass index (kg/m <sup>2</sup> )	1.02 (0.96 – 1.08)	1.08 (0.94 – 1.24)
Symptom onset (months)	1 (0.95 – 1.05)	1.01 (0.89 – 1.13)
Weakness (Yes vs. no)	1.06 (0.69 – 1.62)	0.38 (0.1 – 1.44)
Smoking (Yes vs. no)	1.02 (0.64 – 1.63)	1.02 (0.3 – 3.46)
Straight leg raising test (°)	1 (0.99 – 1.01)	1.02 (0.99 – 1.05)
K-ODI (/45)	1.01 (0.98 – 1.03)	0.97 (0.9 – 1.04)
VAS-trunk (/10)	1.01 (0.92 – 1.1)	1.01 (0.79 – 1.29)
VAS-leg (/10)	0.97 (0.87 – 1.1)	0.94 (0.69 – 1.28)
Surgical level (L5-S1 vs. others)	0.89 (0.58 – 1.37)	0.44 (0.12 – 1.66)
Side		
L vs. B	1.18 (0.47 – 2.97)	0.85 (0.09 – 8.27)
R vs. B	1.03 (0.41 – 2.61)	0.85 (0.09 – 8.44)
Multiple disc herniation (Yes vs. no)	0.94 (0.6 – 1.47)	0.51 (0.14 – 1.93)
Disc morphology (Protrusion vs. extrusion/sequestration)	1.01 (0.68 – 1.51)	0.76 (0.26 – 2.27)
High canal compromise (Yes vs. no)	0.96 (0.64 – 1.43)	1.02 (0.35 – 2.95)
Very high migration (Yes vs. no)	1.1 (0.44 – 2.7)	1.17 (0.13 – 10.76)
Pfirrmann grade (1-3 vs. 4-5)	1.03 (0.68 – 1.55)	0.83 (0.28 – 2.48)
Modic change (Yes vs. no)	1.03 (0.65 – 1.64)	0.96 (0.28 – 3.26)
Surgical method (PETD vs. PEID)	1.09 (0.72 – 1.63)	3.27 (0.87 – 12.25)
Preoperative disc volume (mL)	1.02 (0.77 – 1.35)	2.02 (0.99 – 4.09)
Intraoperative removed disc volume (mL)	1.01 (0.81 – 1.28)	0.7 (0.34 – 1.42)
Relative removal amount (%)	1 (0.98 – 1.02)	0.96 (0.94 – 0.98)*
Radiological success (Yes vs. no)	1.04 (0.59 – 1.83)	

\*P-value &lt; 0.05

2). Neither the amount of disc removal nor the radiological outcome was significantly correlated with clinical success ( $P > 0.5$ )

Successful radiological outcomes were achieved for 93/109 (85.3%) patients. Two of the 13 patients with clinical failure exhibited radiological failure. The surgical method, preoperative disc volume, and relative removal amount were included in the multivariate analysis (Table 2). The relative amount of disc removal ( $P < 0.001$ ; OR = 0.96; 95% CIs = 0.94 – 0.98) was the only significant predictor in the logistic regression analysis. The Hosmer-Lemeshow goodness-of-fit test revealed a  $P$ -value of 0.24, and the area under the curve was 0.86 (95% CIs = 0.77 – 0.96); these results supported the hypothesis that the relative amount of disc removal adequately explains the radiological success. Based on the present result, the probability of residual disc fragment

according to the extent of disc removal in postoperative MRI is presented in a formula and graph (Fig. 4). For example, when 100% of the calculated disc amount was removed during the operation, the probability of residual disc was 29.5%. To maintain the probability of residual disc at less than 10%, on average, more than 131% of the calculated disc amount had to be removed, according to the prediction model.

## DISCUSSION

The present study investigated the amount of discectomy required for successful clinical and radiological outcomes after PELD. The primary ruptured disc fragment was removed during surgery in all patients, but they differed by the volume of the removed loose fragments. Clinical success was achieved in 88.1% of the patients in the present study after PELD. The amount

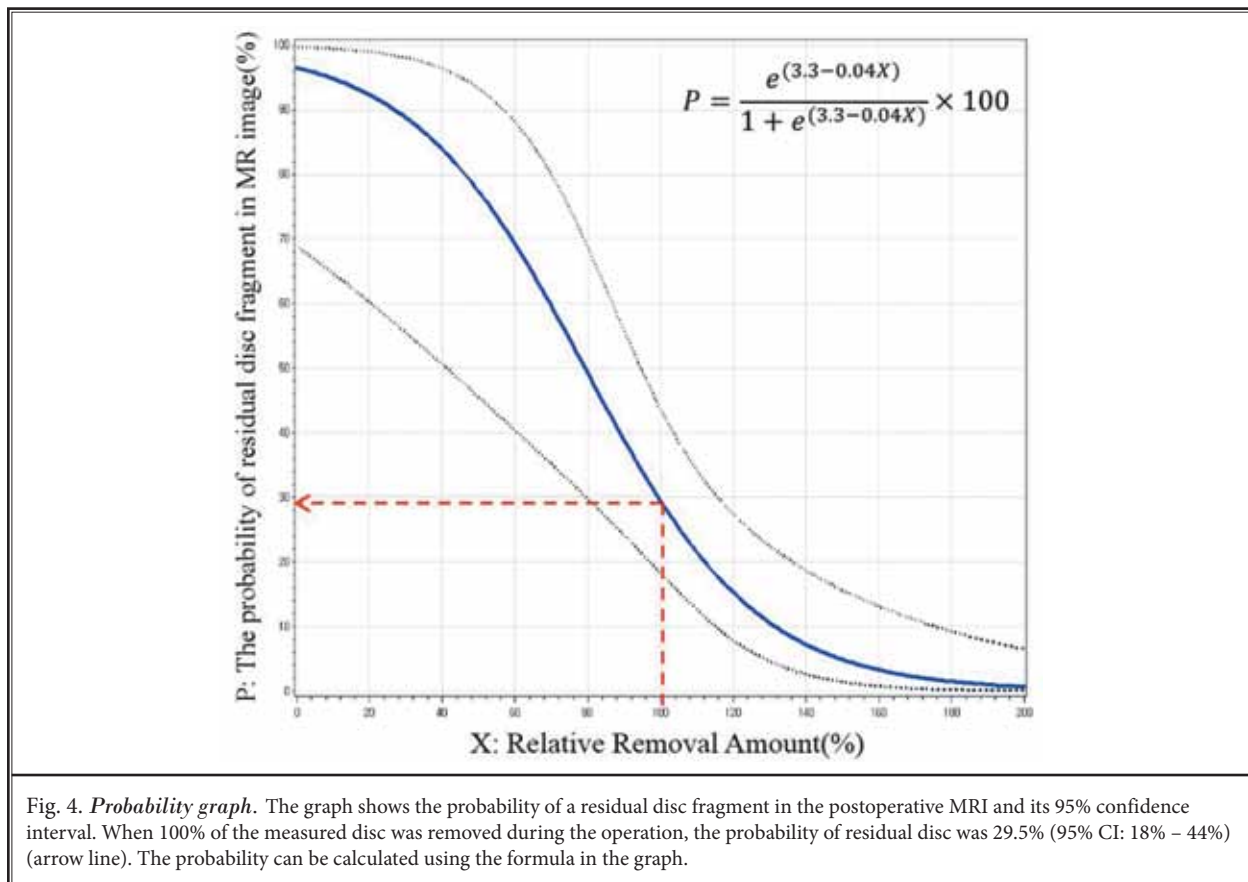


Fig. 4. *Probability graph.* The graph shows the probability of a residual disc fragment in the postoperative MRI and its 95% confidence interval. When 100% of the measured disc was removed during the operation, the probability of residual disc was 29.5% (95% CI: 18% – 44%) (arrow line). The probability can be calculated using the formula in the graph.

of the removed disc was not associated with clinical outcomes in the present study, and no other prognostic factor was revealed. Radiological success was achieved in 85.3% of the patients. The relative volume of the removed disc was most significantly associated with the radiological outcomes. The probability of residual disc in postoperative MRI is presented in the formula and graph.

### Amount of Disc Removal and Surgical Outcomes

Recurrent disc herniation is often the primary issue after discectomy (13). Discectomy can be divided into 2 types: subtotal discectomy and limited discectomy (4,7,17,34,35). Many papers have supported the use of subtotal discectomy because of the low associated recurrence and re-operation rates (4,5,7,36). A prospective study by Carragee et al (17) demonstrated that limited discectomy is associated with a 2 times higher re-herniation rate than subtotal discectomy (18% vs. 9%). McGirt et al (37) performed a prospective study and compared the volume of the removed disc with that of the preop-

erative disc. A higher percentage of disc removal (28%) was associated with a lower chance of symptomatic recurrence (OR = 0.30; 95% CIs = 0.10 – 0.98) than was a lower percentage of disc removal (13%) (37). The re-operation rate of a more than 6-year follow-up study was approximately 2 times higher after limited discectomy than subtotal discectomy (5,38). However, problems associated with disc degeneration were reported after subtotal discectomy. The disc height decreased in 63% of the patients after subtotal discectomy but in only 38% of the patients after limited discectomy (5). Modic change occurred in 47% of the patients after subtotal discectomy but in only 14% of the patients after limited discectomy after a 2-year follow-up (5,34). Consequently, more patients were off medication (35% vs. 23%), experienced less back pain (VAS 1.2 vs. 3), and maintained their preoperative work statuses (81% vs. 70%) after limited discectomy compared with subtotal discectomy (17). McGirt et al (7) performed a meta-analysis of 54 studies that included 13,359 cases of lumbar discectomy via either subtotal or limited discectomy. The frequencies of back pain and radiculopathy immediately

after surgery were similar in both surgeries; however, the frequency was 2.5 times higher after subtotal discectomy (27.8%) than after limited discectomy (11.6%) after 2 years or more. In contrast, the frequency of recurrent disc herniation was 2 times higher after limited discectomy (7% vs. 3.5%) (7). Another systemic review demonstrated similar results (39). No convincing evidence supports the use of limited discectomy over subtotal discectomy; nevertheless, limited discectomy leads to shorter operative times, a quicker return to work, and a decreased incidence of long-term recurrent lower back pain (39).

PELD is similar to limited discectomy, including the removal of ruptured and loose fragments inside the disc; however, the amount of disc removal might be smaller than that in open limited discectomy. Therefore, the risk of recurrence might be higher with PELD than with OD. However, a randomized controlled trial demonstrated a similar recurrence rate between PELD and OD (6.2 vs. 5.7%) (1,12). A nationwide cohort study also demonstrated that the re-operation rate was not higher after PELD during a 5-year follow-up period (13,14). The size of the annular defect associated with PELD seemed slight because of the small instruments and high magnification. The similar outcome after PELD with limited discectomy might be attributable to the minimal defect at the annulus (22,40,41).

### Amount of Disc Removal in PELD

The amount of the removed disc material must be sufficiently large enough to decompress the neural tissue without residual disc fragments inside the spinal canal to prevent recurrence. The entire nerve root may be visualized by removing large amounts of the annulus in PELD, but large annular defects are associated with a high recurrence rate (41,42). It is not always necessary to visualize the entire nerve root in PELD because of indirect clues such as the free movement of the epidural fat or nerve root during coughing or the Valsalva maneuver, the depression of the elevated annulus after the removal of disc fragments, the free passage of a probe into the epidural space, and the removal of estimated ruptured disc fragments based on preoperative MRI. The clinical outcomes were not correlated with the amount of disc removal in the present study. The present study did not identify a predictor; however, we hypothesize that successful removal of the major ruptured fragments and confirmation of the decompression using the aforementioned clues might be sufficient to achieve clinical success. However, radiological success

was correlated with the amount of disc removal. A previous paper compared the removed disc volume with the entire disc volume (37). However, the amount of loose fragments might be correlated with the size of the herniated disc, and the present study demonstrated that the relative volume was the most significant predictor (not the absolute volume). The removal of loose fragments might be customized based on the size of the herniated disc. The present study investigated the probability of radiological success based on the amount of disc removal and presents a formula and graph for calculation. However, postoperative MRI is not a routine test after every surgery. Postoperative MRI are generally required when persistent or recurrent symptoms are present (43). Lebow et al (44) demonstrated that the rate of radiological recurrent disc herniation after subtotal discectomy or sequestrectomy was 23% (25/108) over a 2-year follow-up, although 56% of these patients (14/25) were asymptomatic. Barth et al (34) also demonstrated that postoperative disc protrusion/extrusion was observed in 66% of patients after microdiscectomy and in 68% of patients after sequestrectomy. Only 2 of 13 patients with radiological failure showed clinical failure in the present study. Therefore, radiological success might not be an absolute criterion for a successful surgery. However, residual disc fragment with persistent compression was one cause of re-operation (20,43). Radiological success has not always been correlated with clinical outcomes; nevertheless, the present study might be helpful when determining the amount of disc removal during surgery for radiological success.

### Limitations

The present study has several limitations.

- First, the retrospective design of this study might lead to bias. The present study included consecutive patients to minimize selection bias. However, the investigation failed to identify predictors of clinical success, and thus, a type II error is possible. A study with a larger sample is required to identify predictors of clinical success.
- Second, one surgeon performed all the surgeries at a single institution. Common basic surgical techniques and endoscopic instruments were used for all the patients, but limitations in generalizability might still exist.
- Third, late herniation (> 11 months after surgery) was not considered (37). A long-term follow-up study is necessary to identify the optimal amount



of disc removal required for radiological and long-term clinical success.

## CONCLUSIONS

The amount of disc removal in PELD did not significantly predict clinical success following the removal of the primary ruptured fragments. The relative volume of the removed disc based on preoperative MRI might be a useful method to predict the postoperative MRI. A long-term follow-up study with many patients is necessary to identify the amount of disc removal required for successful surgery.

## Conflicts of Interest

A grant from the Korea Health Technology R&D Project supported this work through the Korea Health Industry Development Institute (KHIDI) funded by the Ministry of Health & Welfare, Republic of Korea (HC15C1320). Grant No. 0320160210 (2016-1062) from the Seoul National University Hospital also partially supported this study. The first author (CHK) is a con-

sultant of RIWOspine GmbH. The other authors declare that they have no conflicts of interest concerning the materials/methods used in this study or the findings described in this paper. The institutional review board at the Seoul National University Hospital approved this study (H-1611-015-803). We also thank the editorial board of Pain Physician for their review and suggestions to improve the manuscript.

## Author Contribution

Drs. JH Heo, YG Seo, DH Kim, CH Kim, CK Chung, and Y Choi had full access to all study data and take responsibility for its integrity and the accuracy of the analyses. Drs. CH Kim, JH Heo, and CK Chung designed the study protocol. Drs. JH Heo, CH Kim, SB Park, JH Moon, W Heo, and JM Jung managed the literature searches and summaries of the previous research and wrote the first draft of the manuscript. Drs. CK Chung and Y Choi revised the intellectual content and provided the final approval of the manuscript.

## REFERENCES

- Birkenmaier C, Komp M, Leu HF, Wegener B, Ruetten S. The current state of endoscopic disc surgery: Review of controlled studies comparing full-endoscopic procedures for disc herniations to standard procedures. *Pain Physician* 2013; 16:335-344.
- Rasouli MR, Rahimi-Movaghar V, Shokraneh F, Moradi-Lakeh M, Chou R. Minimally invasive discectomy versus microdiscectomy/open discectomy for symptomatic lumbar disc herniation. *Cochrane Database Syst Rev* 2014; 9:CD010328.
- Ma XL. A new pathological classification of lumbar disc protrusion and its clinical significance. *Orthop Surg* 2015; 7:1-12.
- Carragee EJ, Han MY, Suen PW, Kim D. Clinical outcomes after lumbar discectomy for sciatica: The effects of fragment type and anular competence. *J Bone Joint Surg Am* 2003; 85:102-108.
- Shamji MF, Bains I, Yong E, Sutherland G, Hurlbert RJ. Treatment of herniated lumbar disk by sequestrectomy or conventional discectomy. *World Neurosurg* 2014; 82:879-883.
- Kaloostian PE, Gokaslan ZL. Extent of lumbar discectomy in modern-day neurosurgery. *World Neurosurg* 2014; 82:640-642.
- McGirt MJ, Ambrossi GL, Dato G, Sciubba DM, Witham TF, Wolinsky JP, Gokaslan ZL, Bydon A. Recurrent disc herniation and long-term back pain after primary lumbar discectomy: Review of outcomes reported for limited versus aggressive disc removal. *Neurosurgery* 2009; 64:338-344; discussion 344-335.
- Sencer A, Yorukoglu AG, Akcakaya MO, Aras Y, Aydoseli A, Boyali O, Sencan F, Sabanci PA, Gomleksiz C, Imer M, Kiris T, Hepgul K, Unal OF, Izgi N, Canbolat AT. Fully endoscopic interlaminar and transforaminal lumbar discectomy: Short-term clinical results of 163 surgically treated patients. *World Neurosurg* 2014; 82:884-890.
- Sairyo K, Matsuura T, Higashino K, Sakai T, Takata Y, Goda Y, Suzue N, Hamada D, Goto T, Nishisho T, Sato R, Tsutsui T, Tonogai I, Mineta K. Surgery related complications in percutaneous endoscopic lumbar discectomy under local anesthesia. *J Med Invest* 2014; 61:264-269.
- Choi G, Lee SH, Deshpande K, Choi H. Working channel endoscope in lumbar spine surgery. *J Neurosurg Sci* 2014; 58:77-85.
- Wang H, Huang B, Li C, Zhang Z, Wang J, Zheng W, Zhou Y. Learning curve for percutaneous endoscopic lumbar discectomy depending on the surgeon's training level of minimally invasive spine surgery. *Clin Neurol Neurosurg* 2013; 115:1987-1991.
- Ruetten S, Komp M, Merk H, Godolias G. Full-endoscopic interlaminar and transforaminal lumbar discectomy versus conventional microsurgical technique: A prospective, randomized, controlled study. *Spine (Phila Pa 1976)* 2008; 33:931-939.
- Kim CH, Chung CK, Choi Y, Shin S, Kim MJ, Lee J, Park BJ. The selection of open or percutaneous endoscopic lumbar discectomy according to an age cut-off point: Nationwide cohort study. *Spine (Phila Pa 1976)* 2015; 40:E1063-E1070.
- Kim CH, Chung CK, Park CS, Choi B, Kim MJ, Park BJ. Reoperation rate after surgery for lumbar herniated intervertebral disc disease: Nationwide cohort study. *Spine (Phila Pa 1976)* 2013; 38:581-590.
- Nellensteijn J, Ostelo R, Bartels R, Peul W, van Royen B, van Tulder M. Transforaminal endoscopic surgery for symptomatic lumbar disc herniations: A systematic review of the literature. *Eur Spine J* 2010; 19:181-204.

16. Hermantin FU, Peters T, Quartararo L, Kambin P. A prospective, randomized study comparing the results of open discectomy with those of video-assisted arthroscopic microdiscectomy. *J Bone Joint Surg Am* 1999; 81:958-965.
17. Carragee EJ, Spinnickie AO, Alamin TF, Paragioudakis S. A prospective controlled study of limited versus subtotal posterior discectomy: Short-term outcomes in patients with herniated lumbar intervertebral discs and large posterior anular defect. *Spine (Phila Pa 1976)* 2006; 31:653-657.
18. Kim CH, Chung CK, Woo JW. Surgical outcome of percutaneous endoscopic interlaminar lumbar discectomy for highly migrated disk herniation. *Clin Spine Surg* 2016; 29:E259-E266.
19. Kim R, Kim RH, Kim CH, Choi Y, Hong HS, Park SB, Yang SH, Kim SM, Chung CK. The incidence and risk factors for lumbar or sciatic scoliosis in lumbar disc herniation and the outcomes after percutaneous endoscopic discectomy. *Pain Physician* 2015; 18:555-564.
20. Lee SH, Kang BU, Ahn Y, Choi G, Choi YG, Ahn KU, Shin SW, Kang HY. Operative failure of percutaneous endoscopic lumbar discectomy: A radiologic analysis of 55 cases. *Spine (Phila Pa 1976)* 2006; 31:E285-E290.
21. Kim CH, Chung CK, Sohn S, Lee S, Park SB. The surgical outcome and the surgical strategy of percutaneous endoscopic discectomy for recurrent disk herniation. *J Spinal Disord Tech* 2014; 27:415-422.
22. Kim HS, Park JY. Comparative assessment of different percutaneous endoscopic interlaminar lumbar discectomy (PEID) techniques. *Pain Physician* 2013; 16:359-367.
23. Kim CH, Chung CK, Hong HS, Kim EH, Kim MJ, Park BJ. Validation of a simple computerized tool for measuring spinal and pelvic parameters. *J Neurosurg Spine* 2012; 16:154-162.
24. Kim DY, Lee SH, Lee HY, Lee HJ, Chang SB, Chung SK, Kim HJ. Validation of the Korean version of the Oswestry disability index. *Spine (Phila Pa 1976)* 2005; 30:E123-E127.
25. Kim CH, Chung CK, Choi Y, Shin H, Woo JW, Kim SM, Lee HJ. The usefulness of a mobile device-based system for patient-reported outcomes in a spine outpatient clinic. *Spine J* 2016; 16:843-850.
26. Copay AG, Martin MM, Subach BR, Carreon LY, Glassman SD, Schuler TC, Berven S. Assessment of spine surgery outcomes: Inconsistency of change amongst outcome measurements. *Spine J* 2010; 10:291-296.
27. Glassman SD, Copay AG, Berven SH, Polly DW, Subach BR, Carreon LY. Defining substantial clinical benefit following lumbar spine arthrodesis. *J Bone Joint Surg Am* 2008; 90:1839-1847.
28. Parker SL, Mendenhall SK, Godil SS, Sivasubramanian P, Cahill K, Ziewacz J, McGirt MJ. Incidence of low back pain after lumbar discectomy for herniated disc and its effect on patient-reported outcomes. *Clin Orthop Relat Res* 2015; 473:1988-1999.
29. Fardon DF, Williams AL, Dohring EJ, Murtagh FR, Gabriel Rothman SL, Sze GK. Lumbar disc nomenclature: Version 2.0: Recommendations of the combined task forces of the North American Spine Society, the American Society of Spine Radiology and the American Society of Neuroradiology. *Spine J* 2014; 14:2525-2545.
30. Teraguchi M, Yoshimura N, Hashizume H, Muraki S, Yamada H, Oka H, Minamide A, Nakagawa H, Ishimoto Y, Nagata K, Kagotani R, Tanaka S, Kawaguchi H, Nakamura K, Akune T, Yoshida M. The association of combination of disc degeneration, end plate signal change, and Schmorl node with low back pain in a large population study: The Wakayama Spine Study. *Spine J* 2015; 15:622-628.
31. Pfirrmann CW, Metzdorf A, Zanetti M, Hodler J, Boos N. Magnetic resonance classification of lumbar intervertebral disc degeneration. *Spine (Phila Pa 1976)* 2001; 26:1873-1878.
32. Modic MT, Steinberg PM, Ross JS, Masyak TJ, Carter JR. Degenerative disk disease: Assessment of changes in vertebral body marrow with MR imaging. *Radiology* 1988; 166:193-199.
33. Durrleman S, Simon R. Flexible regression models with cubic splines. *Stat Med* 1989; 8:551-561.
34. Barth M, Diepers M, Weiss C, Thome C. Two-year outcome after lumbar microdiscectomy versus microscopic sequestrectomy: Part 2: Radiographic evaluation and correlation with clinical outcome. *Spine (Phila Pa 1976)* 2008; 33:273-279.
35. Barth M, Weiss C, Thome C. Two-year outcome after lumbar microdiscectomy versus microscopic sequestrectomy: Part 1: Evaluation of clinical outcome. *Spine (Phila Pa 1976)* 2008; 33:265-272.
36. Kast E, Oberle J, Richter HP, Borm W. Success of simple sequestrectomy in lumbar spine surgery depends on the competence of the fibrous ring: A prospective controlled study of 168 patients. *Spine (Phila Pa 1976)* 2008; 33:1567-1571.
37. McGirt MJ, Eustacchio S, Varga P, Villedic M, Trummer M, Gorenssek M, Ledic D, Carragee EJ. A prospective cohort study of close interval computed tomography and magnetic resonance imaging after primary lumbar discectomy factors associated with recurrent disc herniation and disc height loss. *Spine* 2009; 34:2044-2051.
38. Fountas KN, Kapsalaki EZ, Feltes CH, Smisson HF, 3rd, Johnston KW, Vogel RL, Robinson JS, Jr. Correlation of the amount of disc removed in a lumbar microdiscectomy with long-term outcome. *Spine (Phila Pa 1976)* 2004; 29:2521-2524; discussion 2525-2526.
39. Watters WC, 3rd, McGirt MJ. An evidence-based review of the literature on the consequences of conservative versus aggressive discectomy for the treatment of primary disc herniation with radiculopathy. *Spine J* 2009; 9:240-257.
40. Shin BJ. Risk factors for recurrent lumbar disc herniations. *Asian Spine J* 2014; 8:211-215.
41. Carragee EJ, Han MY, Suen PW, Kim D. Clinical outcomes after lumbar discectomy for sciatica: The effects of fragment type and anular competence. *J Bone Joint Surg Am* 2003; 85-A:102-108.
42. Morgan-Hough CV, Jones PW, Eisenstein SM. Primary and revision lumbar discectomy. A 16-year review from one centre. *J Bone Joint Surg Br* 2003; 85:871-874.
43. Crocker M, Jones TL, Rich P, Bell BA, Papadopoulos MC. The clinical value of early postoperative MRI after lumbar spine surgery. *Br J Neurosurg* 2010; 24:46-50.
44. Lebow RL, Adogwa O, Parker SL, Sharma A, Cheng J, McGirt MJ. Asymptomatic same-site recurrent disc herniation after lumbar discectomy: Results of a prospective longitudinal study with 2-year serial imaging. *Spine* 2011; 36:2147-2151.