

Retrospective Study



Percutaneous Endoscopic Lumbar Discectomy for Highly Migrated Lumbar Disc Herniation

Chao Liu, MD, Lei Chu MD, Hao-Chuan Yong, MD, Liang Chen, MD, PhD, and Zhong-Liang Deng, MD, PhD

From: The Second Affiliated Hospital of Chongqing Medical University
Chong Qing, China

Address Correspondence:
Zhong-Liang Deng, MD, PhD
Teh Second Affiliated Hospital of Chongqing Medical University
Chong Qing, China 400016
E-mail:
zhongliang.deng@yahoo.com

Disclaimer: There was no external funding in the preparation of this manuscript.
Conflict of interest: Each author certifies that he or she, or a member of his or her immediate family, has no commercial association (i.e., consultancies, stock ownership, equity interest, patent/licensing arrangements, etc.) that might pose a conflict of interest in connection with the submitted manuscript.

Manuscript received:
09-02-2015

Revised manuscript received:
05-18-2016

Accepted for publication:
06-29-2016

Free full manuscript:
www.painphysicianjournal.com

Background: Percutaneous endoscopic lumbar discectomy (PELD) has been growing in popularity for the treatment of lumbar disc herniation (LDH) due to its irreplaceable advantages over conventional open surgery. Compared with common lumbar disc herniations, discectomy of highly migrated LDH by PELD is known to be very difficult. Highly migrated lumbar disc herniation has long been a challenge for its specific characteristics. Three approaches for PELD have been applied to access a highly migrated LDH, including an interlaminar approach (IL), transforaminal approach (TF), and contralateral transforaminal approach (CTF). However, none of the existing research has systematically described the selection of the most appropriate procedure from the 3 approaches or the individualization of an operative procedure in different cases.

Objectives: The purpose of this study was to present a detailed surgical approach selection and individualization of procedure in the treatment of highly migrated LDH with PELD. We also mean to compare the outcomes of patients with highly migrated LDH treated with PELD by the 3 approaches.

Study Design: Single-center retrospective observational study.

Setting: An interventional pain management practice, a medical center, major metropolitan city, China.

Methods: In our retrospective analysis between March 2011 and March 2013, 73 patients with single level highly migrated LDH received PELD. Clinical outcomes were assessed with the visual analogue scale (VAS) score, the modified MacNab criteria, and the Oswestry disability index (ODI). Relevant data such as operation duration and fluoroscopy frequency of the 3 operative approaches were recorded.

Results: The mean operating time of IL was 56 minutes, compared with 64 minutes for TF and 112 minutes for CTF. The mean intraoperative fluoroscopy times were 5.5 for IL, 9.7 for TF, and 14.6 for CTF. In each group, the mean VAS and ODI after surgery and 3 months after surgery improved dramatically compared with preoperative counterparts. However, the difference between postoperative results and the results 3 months after surgery was not significant ($P > 0.05$). The overall excellent rate was 90.4% according to the modified MacNab criteria; there was no significant statistical difference between the 3 operative routes. Operative complications occurred in 3 patients (2 after IL and one after CTF, 3 of 73, 4.1%).

Limitations: This study is limited by its sample size.

Conclusion: In our research, PELD with all 3 approaches was similarly effective to highly migrated disc herniation. The CTF approach required the longest operation duration and the most intraoperative times. On the contrary, the least operation time and radiograph frequency was required with the IL approach. In addition, we came to a conclusion of surgery approach selection when it comes to varied HM-LDH.

Key words: Highly migrated, lumbar disc herniation, percutaneous endoscopic lumbar discectomy, minimally invasive treatment

Pain Physician 2017; 20:E75-E84

Procedure plays a very important role in the treatment of lumbar disc herniation (LDH), which has been treated by open surgery in the past (1-5). Percutaneous endoscopic lumbar discectomy (PELD) has been an increasingly popular surgical procedure to treat lumbar disc herniation since Kambin (6) proposed the concept of the Kambin triangle and accordingly applied the first PELD in 1973. This surgery is effective and minimally invasive, with an effective rate of 90% which is equivalent to traditional open surgery (7-9). On the other hand, highly migrated disc herniation has long been a challenge due to its specific characteristics. This challenge promoted the formation of 3 common operative routes for PELD (transforaminal [TF], interlaminar [IL], and contralateral transforaminal [CTF]). Meanwhile, surgical instrumentation and techniques have also improved dramatically. In addition, the application of new instruments has promoted the development of new surgical procedures such as intervertebral foraminoplasty. We performed this study since few of the existing studies have systematically described the selection of the most appropriate operative approach in highly migrated LDH or the individualization of operative procedures in different cases.

METHODS

Between March 2011 and March 2013, 73 patients with highly migrated LDH were treated with PELD in our hospital, 44 men and 29 women, with a mean age of 37.6 (range 24 - 56) years. Their course of disease was from 3 weeks to 28 months, average about 8 months (Table 1). Among all these cases, the lesion level of 5 patients was L3-4, 41 patients L4-5, and 27 patients L5-S1. Thirty-one patients received PELD by the TF approach (11 of whom underwent foraminoplasty to gain access to the migrated fragment), 15 by the CTF approach, and 27 by the IL approach. Inclusion criteria: (1) neurological signs including radiculopathy, sensory changes, motor weakness, and the presence of abnormal reflex; (2) symptoms corresponding with preoperative magnetic

resonance imaging (MRI) and computed tomography (CT) scans; (3) imaging examinations and disc radiography showing highly migrated herniation of a single level; (4) unsuccessful conservative treatment including root blocks and analgesics for at least 8 weeks; and (5) meeting our definition of highly migrated disc herniation, according to sagittal T2 weighted MRI, herniated disc reaches the lower edge of the superior pedicle or the lower edge of the inferior pedicle (10,11). Exclusion criteria: (1) central stenosis (less than 10 mm) or lateral recess stenosis (less than 3 mm) confirmed by MRI and CT scans; (2) a narrowing foramen (less than 7 mm); and (3) segmental instability confirmed by dynamic radiographs. All of the surgeries were performed by experienced surgeons.

Operative Technique

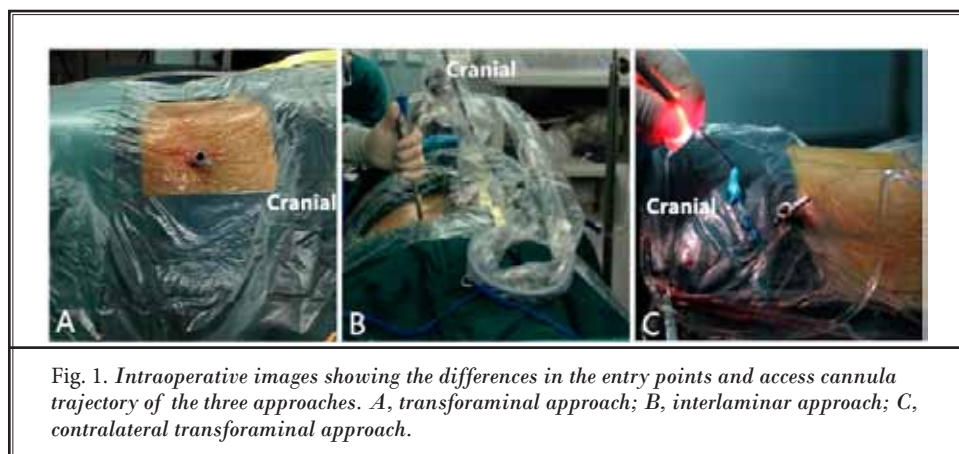
Our surgical procedures to remove a highly migrated LDH were based on conventional endoscopic approaches. All the procedures were performed in the prone position on a radiolucent table and under the guidance of C-arm fluoroscopy. Local anesthesia and sedation were applied. Continuous feedback was obtained from the patient during the entire procedure to prevent damage to neural structures. Figure 1 shows the differences in the entry points and access cannula trajectory of the 3 approaches.

Transforaminal PELD

TF-PELD was performed with an entry point 10 – 13 cm from the midline, a more lateral entry point could help achieve a wider manipulation angle and therefore make access to the migrated fragment easier. After an 18-plaque spinal needle was inserted into the disc, discography was performed using a 2 mL mixture of methylene blue and Iohexol. Then a small skin incision was made around the needle and sequential dilators were placed. A working cannula was placed and the endoscope was introduced. If the herniated fragment of the disc was not sequestered, it could be grabbed at the proximal end by forceps and removed. However, when

Table 1. General data of patients treated by the 3 approaches.

Approach	Gender		Age (Year)	Involved level		
	Male	Female		L3-4	L4-5	L5-S1
Transforaminal	18	13	38.5 ± 7.8	3	26	2
Contralateral transforaminal	11	4	37.1 ± 7.2	2	13	0
Interlaminar	15	12	37.5 ± 6.2	0	2	25

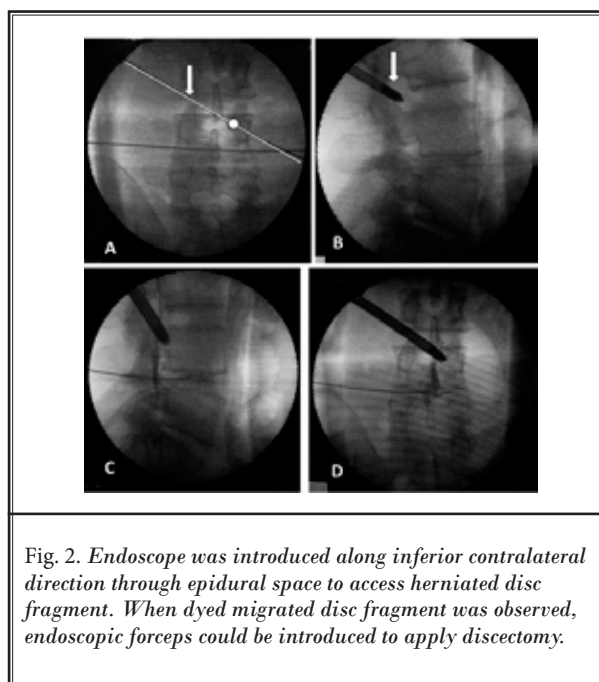


the migrated fragment was broken into several pieces, the epidural space was exposed to make sure all the fragments were removed. When a highly down migrated fragment of disc was blocked by the pedicle, or more space for manipulation, was needed for sequestered fragments, a partial pediclectomy was performed with burrs to make access.

Interlaminar PELD

The shoulder approach was used for the superior migration, while the axillar approach was used for the inferior migration. In addition, the entry point was closer to the lateral border of the interlaminar window for superior migration. On the other hand, the entry point was closer to the midline of the interlaminar window for inferior disc herniation.

An 18-gauge spinal needle was inserted into the disc with the conventional interlaminar approach and discography was performed using a 2 mL mixture of methylene blue and Iohexol. Then a small skin incision was made around the needle and sequential dilators were placed into the lateral edge of the interlaminar space. A working cannula was introduced and the final position was checked on the anteroposterior (AP) and lateral fluoroscopic images. The endoscope was introduced through the cannula and the ligamentum flavum was exposed by cleaning the soft tissues. After the exposed ligamentum flavum was opened, the working cannula was introduced into the epidural space through the ligamentum flavum, then the thecal sac and nerve root were exposed. With gentle retraction of the root, the herniated disc fragment was identified and then removed with forceps. Partial medial laminectomy could be performed with burrs when the access was blocked by an osseous structure of the interlaminar space.



Contralateral Transforaminal PELD

The entry point of CTF PELD was more lateral (approximately 14 cm from the midline for L4-5) than for ipsilateral TF-PELD to access a distally inferiorly migrated disc fragment. First, an 18-gauge spinal needle was introduced into the disc under fluoroscopic guidance. A 2 mL mixture of methylene blue and Iohexol was injected into the disc through the spinal needle to help identify the disc with fluoroscopy and direct vision. After a small incision around the spinal needle, sequential dilators were placed along the guide needle. Appropriate position of cannula is shown in Fig. 2. The

endoscope was introduced through the epidural space to access the migrated disc fragment. When the dyed migrated disc fragment was observed, endoscopic forceps were introduced to remove it.

After the procedures, all of the patients received an MRI within 24 hours to confirm complete decompression of the pinched nerve root and dural sac. Intraoperative fluoroscopy time and operation time were recorded.

RESULTS

Table 2 shows the mean operating and fluoroscopy times for the 3 approaches. The mean operating time for IL-PELD was 56 minutes, compared with 64 minutes for TF-PELD and 112 minutes for CTF-PELD. The mean fluoroscopy times were 5.5 minutes for IL-PELD, 9.7 minutes for TF-PELD, and 14.6 minutes for CTF-PELD.

The surgical effects assessed by VAS and ODI are shown in Figs. 3 and 4. For TF-PELD, the mean VAS scores for back and leg pain decreased from 5.81 to 1.97

and 7.16 to 2.00 after surgery, respectively. For IL-PELD, the mean VAS for back and leg pain decreased from 5.41 to 2.07 and 7.19 to 2.33 after surgery, respectively. For CTF-PELD, the mean VAS for back and leg pain decreased from 5.53 to 1.93 and 6.47 to 2.07 after surgery, respectively. The mean ODI after TF-PELD improved from 5.45 to 18.2 after surgery, compared with 55.0 to 13.1 for IL-PELD and 57.2 to 14.4 for CTF-PELD. To sum up, in each group, the mean VAS and ODI after surgery improved dramatically compared with preoperative counterparts. While, the results didn't differ dramatically 12 months after surgery ($P > 0.05$).

The modified MacNab (12) criteria were used to evaluate the postoperative outcomes (Table 3). During postoperative follow-up of 3 months, the rate of having a favorable outcome (excellent or good) was 90.4%, which implies an improvement during follow-up in all 3 groups, while the difference between the groups was not significant ($P > 0.05$). All in all, the clinical outcomes of all 3 approaches were similarly favorable.

Table 2. Operating time and fluoroscopy times of 3 approaches.

Approach	Operating time (minute)	Fluoroscopy times
Transforaminal	64±12	9.7±2.4
contralateral transforaminal	112±12	14.6±3.2
Interlaminar	56±10	5.5±2.5
P-value	<0.05	<0.05

*The difference between the 3 groups is significant ($P < 0.05$).

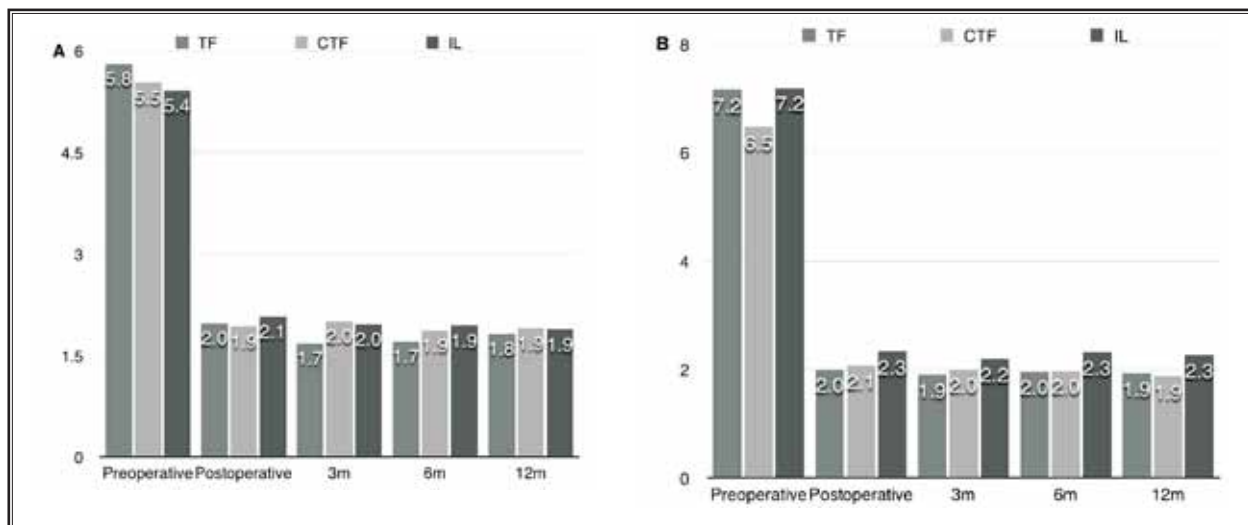


Fig. 3. The surgical results according to VAS back pain(A) and VAS leg pain(B) in TF, CTF and IL groups.

Complications

Technical success was defined as the ability to access the lesion and remove the herniated fragment using the approach. One failure was observed in our study. This patient, while receiving IL-PELD, developed severe insufferable head and neck pain and thereafter became anxious and uncooperative (Fig. 5). The surgery had to be halted for security reasons. Instead, the patient then received TF and foraminoplasty, and the highly migrated herniated nucleus was successfully removed. This patient was finally included in the TF group. The pain should be attributed to high intraoperative irrigation pressure which increased the pressure in the subarachnoid space. Postoperative MRI showed complete removal of the disc material in all the patients, no failure due to residual fragment was observed.

Another patient in the IL group developed dural injury and then had absolute bedrest after surgery for 3 days; no abnormal manifestations

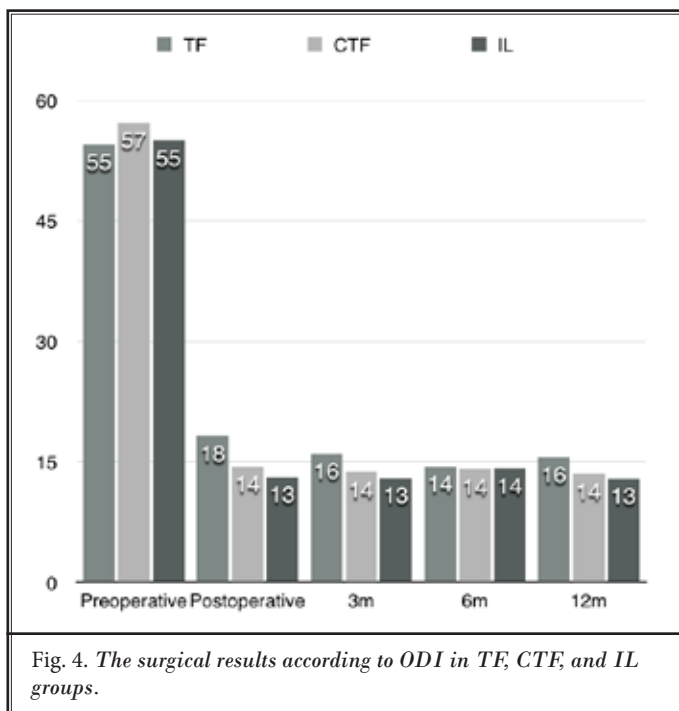


Fig. 4. The surgical results according to ODI in TF, CTF, and IL groups.

Table 3. Modified MacNab of the 3 approaches postoperative (3 months).

Approach	Case	Excellent	Good	Fair	Poor	Success rate
Transforaminal	31	14	13	4	0	87.1%
Contralateral transforaminal	15	8	6	0	1	93.3%
Interlaminar	27	15	10	2	0	92.6%

*The differences of results between each 2 groups are significant ($P > 0.05$).

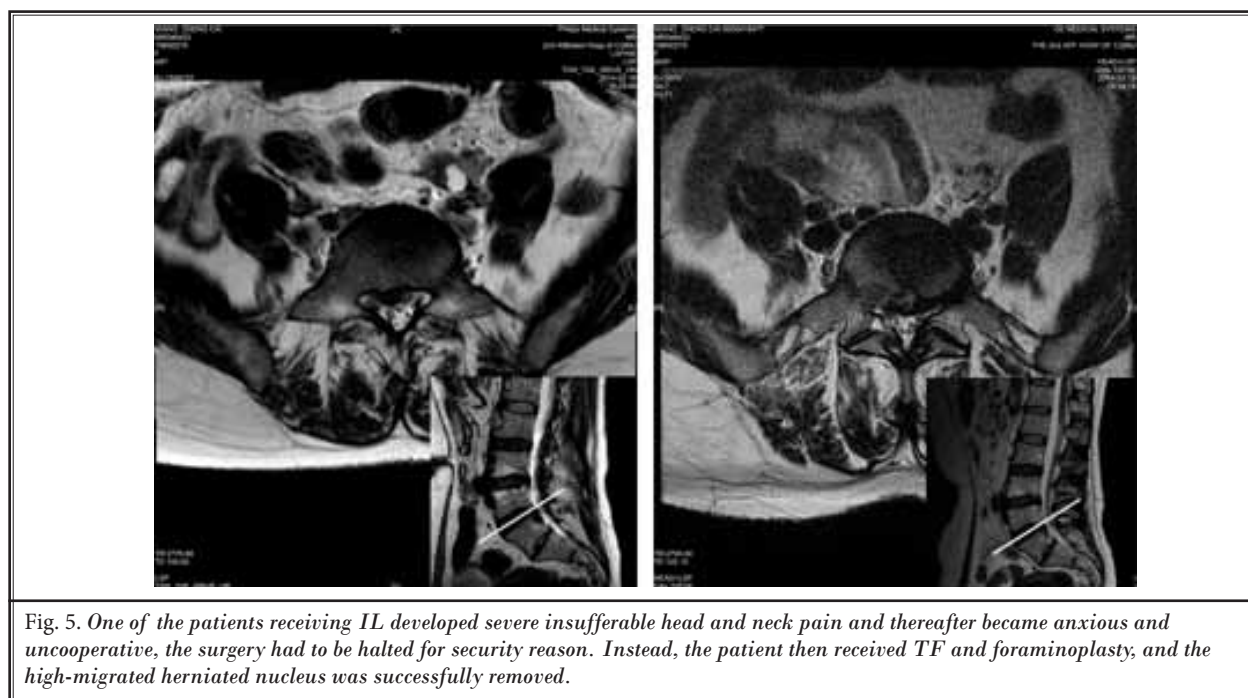


Fig. 5. One of the patients receiving IL developed severe insufferable head and neck pain and thereafter became anxious and uncooperative, the surgery had to be halted for security reason. Instead, the patient then received TF and foraminoplasty, and the high-migrated herniated nucleus was successfully removed.

were observed ultimately. The cauda equina nerve injury of one patient suffering L5-S1 highly migrated LDH in the CTF group was aggravated (increased dysesthesia of perineum) after CTF because of intraoperative mobilization of the cauda equina nerve, but the symptoms were gradually relieved over 3 months with conservative therapy.

In total, 3 surgery-related complications were observed among all the enrolled patients (2 after IL and one after CTF, 3 of 73, 4.1%).

Discussion

I. Features of the 3 approaches of PELD and relevant auxiliary techniques

TF-PELD

Transforaminal endoscopic surgery to optimize the route to the spinal canal under continuous visualization has been performed since the late 1990s (13). Currently, TF-PELD is the most widely used endoscopic procedure in the treatment of LDH. By the lateral approach, the spinal canal can be reached more efficiently under continuous visualization (4). However, limitations to the access to the resection of highly migrated herniated discs within the spinal canal still exist. The osseous edge of the foramen and the nerve can limit working mobility and removal of the migrated herniated disc (11,13-16). In addition, the posterior iliac crest and the anterior abdominal structures may block access.

IL-PELD

To overcome the anatomic limitations of TF-PELD at the L5-S1 level, an interlaminar endoscopic discectomy was applied. Yeung and Tsou suggested that TF-PELD can access all lumbar levels, even L5-S1. The anatomic structure of the L5-S1 level has a narrow foramen, a high pelvic wing, and a large facet joint, each of which blocks access to performing TF-PELD. On the other hand, with a wide interlaminar space, IL-PELD enables the removal of a herniated disc that was not successfully achieved using the TF technique (17). Because of the increased risk of cauda equina and S1 nerve root injury, it's difficult and unsafe to remove a shoulder disc herniation with the IL approach. Directly accessing the shoulder of the S1 nerve root can damage the nerve root because the S1 root emerges from the dural sac at the L5-S1 disc space. Sufficient medial facetectomy to create space is required.

Contralateral TF

In some cases, the route of PELD is obstructed by anatomic obstacles such as the pedicle so that conventional TF and IL approaches have no access to the targets. When an extruded disc migrates caudally and laterally to the interior side of the ipsilateral pedicle or lateral recess, the TF route is blocked by the pedicle. When such a case is treated by ipsilateral TF, foraminoplasty could give more access to the disc but it is time consuming and could cause excessive bleeding. In addition, the nerve root could be injured by too much manipulation in the intervertebral foramen (11,14,18). Considering the difficulties mentioned, Kim et al (19) introduced and described a novel contralateral approach to overcome these obstacles. Compared with ipsilateral TF, contralateral access allows a wider angle to reach the extruded disc because of a longer distance from the contralateral foramen to the herniated fragment. Therefore, this approach is likely to remove the distally, inferiorly migrated disc without too much difficulty.

Partial pediclectomy, facetectomy, laminectomy, and foraminoplasty could remove tissues such as foraminal ligaments and lamina to achieve a better visual window and overcome osseous barriers (20), but, they are time consuming and might cause bone bleeding, which cannot be easily controlled by radiofrequency coagulation or irrigation.

Suprailiac entry has been applied in TF-PELD of the L5-S1 level in order to give access to the foramen concealed by the iliac crest, which then enables removal of L5-S1 disc.

II. IL-PELD Versus TF-PELD

It's not difficult to remove a low-grade migrated disc herniation with PELD (11,21,22). But, discectomy of highly migrated disc herniations with endoscopy has been known to be very difficult. Open surgery was recommended for highly migrated LDH due to a high chance of failure through the TF route (21,22). Recently, removal of the highly migrated LDH with PELD has been reported occasionally (1,5,14,16,23). However, none of the existing research has systematically described the selection of the most appropriate procedure from the 3 approaches or the individualization of operative procedures in different cases. Lee et al (1) introduced an anatomic classification of disc migration and surgical approaches of PELD, but just one approach (TF) was included in their study. A systematic description of the treatment of highly migrated LDH is still lacking. We

hence described the approach selection, individualizing of procedure and cardinal techniques of the 3 routes in highly migrated LDH according to our technology and experience.

III. Clinical results

The 3 approaches were all effective in terms of the operative results according to preoperative and postoperative VAS and ODI. And the difference between the 3 approaches according to the modified MacNab criteria was not significant ($P > 0.05$). During postoperative follow-up, the results didn't differ significantly 3 months after surgery compared with postoperative results in each group ($P > 0.05$). Consequently, the efficacy of all the approaches was similarly favorable and constant.

Compared with the other 2 approaches, the IL approach has the shortest operative and fluoroscopy times. This should be attributed to its more simple anatomic structure. In addition, the surgical procedure for the IL approach, which is similar to a traditional open discectomy, also contributes to this effect. This finding implies that when IL and other approaches are equally feasible in one case, the IL approach may be preferable.

On the other hand, even though the CTF approach provides access for the removal of an inferiorly migrated disc, it is difficult and dangerous to approach the migrated fragment through the anterior space of the dural sac from the contralateral foramen. This opinion has been demonstrated by the longest operation and fluoroscopy times in our study. Furthermore, the aggravated cauda equina nerve injury of one patient in the CTF group was observed. Therefore, considering the difficulty and longer learning curve, we do not recommend the CTF approach when other approaches are available, especially for an inexperienced surgeon.

IV. Surgical approach selection

The TF approach is possible at all spinal levels, including L2-3, L3-4, and L5-S1 (18,20,24,25). Even though in some patients, high iliac crests seem to be an obstacle to the TF route, the application of a transiliac entry could give access to the foramen concealed by the iliac crest and therefore enable removal of the L5-S1 disc.

In addition, partial pediculectomy and facetectomy may help achieve the feasibility of a TF approach in cases with a narrow foramen. On the other hand, the TF approach poses a risk of exiting root injury with less-experienced surgeons. And techniques such as suprailiac entry and pediculectomy are time consuming and may

cause bleeding. Excessive manipulation in the foramen increases the risk of exiting root injury.

The IL approach is primarily performed for L5-S1 and L4-5 levels when the interlaminar space is sufficient. A narrow IL space may lead to increased difficulty of removing a migrated disc with an IL approach, and manipulation in a narrow space could injure the nerve root and cauda equina. However, sufficient medial facetectomy to create space may increase the access.

Even though several approaches could be feasible in a case, the preferable approach should be the most efficient, the safest, and the least time-consuming one.

Highly Down-migrated Lumbar Disc Herniation of L4-5

As the ipsilateral pedicle blocks the view of the highly down-migrated disc fragment, it's difficult to gain access to a downward migrated inferior fragment of disc with PELD through an ipsilateral TF approach, especially the one in the lateral recess. Furthermore, a surgeon has to choose a more cranial skin entry to remove a severely down-migrated fragment, increasing the risk of injuring the exiting nerve root.

Partial pediculectomy was recommended by Choi et al (20) to remove extremely down-migrated fragments, including partial resection of the superior facet tip of the inferior vertebra and expanding the foramen with a drill. But this technique is time consuming and might cause bone bleeding, which cannot be easily controlled by radiofrequency coagulation or irrigation. In addition, when ipsilateral TF-PELD is used to remove a highly down-migrated fragment, the more cranial skin entry and a working cannula inclining to the cranial side may increase the risk of injuring the exiting nerve roots.

To make access to highly down-migrated fragments, a CTF approach is another alternative which provides a longer distance from the contralateral foramen to the herniated segment and therefore enables the endoscope to remove the superior herniated disc. However this approach had the longest operative and fluoroscopy times and a case of aggravated cauda equina injury in our study indicating that it is difficult and dangerous to approach the target through anterior space of the dural sac from the contralateral foramen. So a CTF approach may not be preferable when other approaches are feasible.

Because of the anatomic features of the lumbar spine, ascending levels toward the inferior edge of the lamina overhang the disc space (26) (Fig. 6). In other

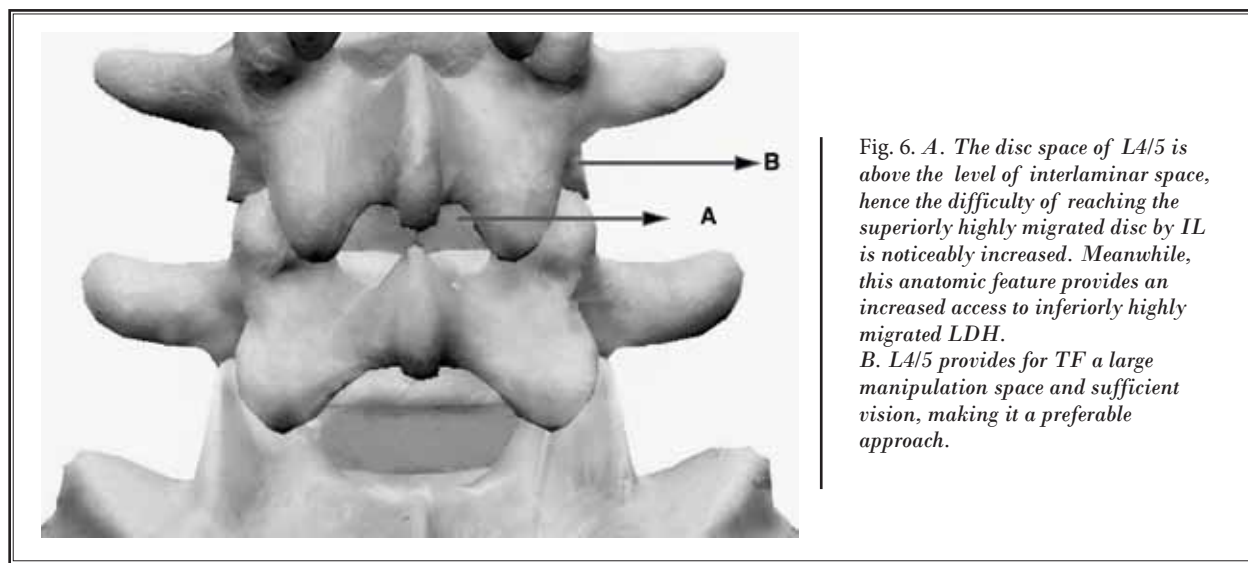


Fig. 6. *A. The disc space of L4/5 is above the level of interlaminar space, hence the difficulty of reaching the superiorly highly migrated disc by IL is noticeably increased. Meanwhile, this anatomic feature provides an increased access to inferiorly highly migrated LDH.*

B. L4/5 provides for TF a large manipulation space and sufficient vision, making it a preferable approach.

words, the disc space of L4-5 is above the level of its interlaminar space, making the removal of down-migrated fragments by IL-PELD less difficult. As opposed to the CTF approach, the IL-PELD approach may be applied comfortably even for less-experienced surgeons because the anatomy is similar to that of open surgery. With such favorable features, IL should be a preferable approach for highly down-migrated disc fragments of L4-5.

In addition, in some cases of inferior migrated shoulder disc herniation, it is difficult to approach the shoulder area of the nerve root with an IL approach. Approaching the shoulder of the L5 nerve root directly may injure the nerve root (27). In such a case, medial facetectomy should be considered.

Preferable approach: IL

Highly Up-migrated Lumbar Disc Herniation of L4-5

The most frequent locations of migrated lumbar herniations are lower levels, up-migrated herniation is relatively rare. However, it's a challenge for a surgeon to gain access to a highly up-migrated disc fragment of L4-5.

The inferior edge of the lamina of L4 overhangs the superior portion of the L4-5 disc space (26), increasing the difficulty of gaining access to the highly up-migrated disc via an IL approach. A narrow interlaminar space of L4-5 may also restrict the manipulation of surgical instruments. In addition, to gain access to the

superior migrated fragment, the shoulder approach was always used, and an extensive laminectomy may be necessary to approach the distal part of the disc material, which is more time-consuming, can cause bleeding, and is more invasive to the patient.

On the other hand, an anatomic feature of L4-5 is a large foramen, providing a large manipulation space and sufficient vision for TF-PELD (Fig. 6). Generally, the foramen of L4-5 is large enough so that a working cannula can be completely advanced into the anterior epidural space of a highly migrated disc. In addition, the cannula is placed in the upper wider part of the foramen to remove an up-migrated fragment. The up-migrated fragment is usually under the exiting root, and can be exposed with removal of the foraminal ligament and the ligamentum flavum. So additional foraminoplasty is always not needed. However, when the migrated fragment is broken into several pieces and more extensive manipulation is needed, foraminoplasty should be applied to gain enough access to the targets.

Considering that unnecessary central decompression may cause postoperative instability or a reduction in disc height (11), if the disc fragment is totally migrated without an intradiscal component, a cannula would remain in the epidural space without penetrating the annulus.

Preferable approach: TF

Highly Migrated Lumbar Disc Herniation of L5-S1

Similar to L4-5 level, a TF approach for a down-

migrated fragment at L5-S1 is blocked by the pedicle.

Moreover, Choi et al (27) described the anatomic characteristics of L5-S1 with the large facets joint overlapping the disc space cephalocaudally and laterally. The transverse process of L5 originates at a lower level from the vertebral body and it is broader with a bend, which is occasionally inferiorly directed. The intertransverse space of L5-S1 is the narrowest compared with other lumbar intertransverse spaces. Each of these peculiarities may hinder the TF access to the L5-S1 disc space. What's more, the iliac wing limits access of the instrumentation into the disc space, a high iliac crest may even block the TF access of L5-S1 in some cases.

Even though it may be possible to advance the working cannula into the foramen with the assistance of osseous resection, the ability to explore the spinal canal is very limited. Difficulty may further increase when trying to access the superior highly migrated fragment: the downward motion of a proximal working cannula and endoscope is obstructed by the iliac crest, so that a distal endoscope can't move upward and remove the superior fragment. As a result, it is very difficult to apply IL-PELD for migrated disc herniations of L5-S1, no matter up-migrated or down-migrated.

Nevertheless, another anatomic characteristic of L5-S1 is a large interlaminar space, with the greatest interlaminar distance and the maximum width of the interlaminar space, leading to a larger manipulation space. The spinal canal at the level of L5-S1 contains the dural sac with the sacral roots only, also contributing to a greater free space for manipulation. What's more, even though the inferior edge of the lamina of L5 overhangs the superior portion of L5-S1 disc space, it was less than that in the upper lumbar vertebrae.

Considering the above mentioned, IL-PELD is a preferable approach for highly migrated herniation of L5-S1, no matter up-migrated or down-migrated.

Even though the interlaminar space of L5-S1 is generally large enough for IL-PELD, sometimes it is difficult to approach the shoulder area of the S1 nerve root. Approaching the shoulder of the S1 nerve root directly may injure the nerve root because the S1 root emerges from the thecal sac at the L5-S1 disc space (28). Medial facetectomy should be taken into account in terms of a shoulder disc herniation.

Contralateral IL is feasible to access a migrated

fragment in the lateral recess, but not recommended considering the above mentioned disadvantages.

Preferable approach: IL

Ahn et al (29) reported the treatment of upper LDH by PELD, while there is no published research on the feasibility of PELD for highly migrated upper LDH. Five patients with herniations at L3-4 were included in our research. Considering the features of L3-4 such as a narrow interlaminar space, we applied PELD by the TF approach for these 3 patients. Two other patients received PELD by the CTF approach to access the fragment in the lateral recess. All of them achieved excellent or good results according to the modified MacNab criteria.

CONCLUSION

1. In the treatment of highly migrated LDH in our study, the efficacy of IL, TF, CTF were similarly favorable and constant.
2. With auxiliary techniques, multiple approaches may be feasible in one case. Even though, considering the operative time, difficulty, and safety, the TF approach is suitable for a superior highly migrated disc of L4-5. However, the IL approach is preferable in the treatment of an inferior migrated disc of L4-5, as well as a superior or inferior highly migrated disc of L5-S1. The CTF approach is an alternative to access an inferior migrated fragment, especially a distally inferiorly migrated fragment in the lateral recess, but it is not recommended when other approaches are feasible. Auxiliary techniques such as partial pediculectomy, facetectomy, laminectomy, and foraminoplasty could be applied to achieve a better visual window and overcome osseous barriers when it comes to obstacles such as a narrow foramen or a small interlaminar space. For highly migrated LDH of L3-4, the TF approach is preferable.
3. When IL and other approaches are equally feasible in one case, IL may be preferable to achieve shorter operative and fluoroscopy times.
4. To choose a suitable surgical approach of PELD to access a highly migrated LDH and individualize the surgical procedure in different cases, the features of a patient such as shape of the foramen, height of the iliac crest and location of the migrated fragment should be based on preoperative MRI and CT results.

REFERENCES

1. Lee S, Kim SK, Lee SH, Kim WJ, Choi WC, Choi G, Shin SW. Percutaneous endoscopic lumbar discectomy for migrated disc herniation: Classification of disc migration and surgical approaches. *Eurospine Journal* 2006; 16:431-437.
2. Ahn Y, Lee SH, Park WM, Lee HY. Posterolateral percutaneous endoscopic lumbar foraminotomy for L5-S1 foraminal or lateral exit zone stenosis. Technical note. *J Neurosurg* 2003; 99:320-323.
3. Hermantin FU, Peters T, Quartararo L, Kambin P. A prospective, randomized study comparing the results of open discectomy with those of video-assisted arthroscopic micro-discectomy. *J Bone Joint Surg Am* 1999; 81:958-965.
4. Kambin P, Casey K, O'Brien E, Zhou L. Transforaminal arthroscopic decompression of lateral recess stenosis. *J Neurosurg* 1996; 84:462-467.
5. Deen HG. Posterolateral endoscopic excision for lumbar disc herniation: Surgical technique, outcome, and complications in 307 consecutive cases. *Spine (Phila Pa 1976)* 2002; 27:722-731.
6. Kambin P, Sampson S. Posterolateral percutaneous suction-excision of herniated lumbar intervertebral discs. *Clin Orthop* 1986; 207:37-43.
7. Ahn Y, Lee SH, Lee JH, Kim JU, Liu WC. Transforaminal percutaneous endoscopic lumbar discectomy for upper lumbar disc herniation: Clinical outcome, prognostic factors, and technical consideration. *Acta Neurochir* 2009; 151:199-206.
8. Ebeling U, Reichenberg W, Reulen HJ. Results of microsurgical lumbar discectomy. Review on 485 patients. *Acta Neurochir* 1986; 81:45-52.
9. Hermantin FU, Peters T, Quartararo LA. A prospective, randomized study comparing the results of open discectomy with those of video-assisted arthroscopic microdiscectomy. *J Bone Joint Surg* 1999; 81:958-965.
10. Lee S, Kim SK, Lee SH, Kim WJ, Choi WC, Choi G, Shin SW. Percutaneous endoscopic lumbar discectomy for migrated disc herniation: Classification of disc migration and surgical approaches. *Eur Spine J* 2007; 16:431-437.
11. Kim CH, Chung CK, Woo JW. Surgical outcome of percutaneous endoscopic interlaminar lumbar discectomy for highly migrated disc herniation. *J Spinal Disord Tech* 2012 [Epub ahead of print].
12. MacNab I. Negative disc exploration: An analysis of the causes of nerve root involvement in sixty-eight patients (J). *J Bone Joint Surg* 1971; 53:891-903.
13. Ruetten S, Komp M, Godolias G. An extreme lateral access for the surgery of lumbar disc herniations inside the spinal canal using the full-endoscopic uniportal transforaminal approach: Technique and prospective results of 463 patients. *Spine (Phila Pa 1976)* 2005; 30:2570-2578.
14. Kim HS, Ju CI, Kim SW, Kim JG. Endoscopic transforaminal suprapedicular approach in high grade inferior migrated lumbar disc herniation. *J Korean Neurosurg Soc* 2009; 45:67-73.
15. Yeom KS, Choi YS. Full endoscopic contralateral transforaminal discectomy for distally migrated lumbar disc herniation. *J Orthop Sci* 2011; 16:263-269.
16. Tonogai I, Sairyo K, Higashino K, Sakai T, Katoh S, Yasui N. Minimally invasive endoscopic removal of a herniated nucleus pulposus that had migrated to the S1 nerve root foramen. *Minim Invasive Neurosurg* 2007; 50:173-177.
17. Ruetten S, Komp M, Merk H, Godolias G. Use of newly developed instruments and endoscopes: Full-endoscopic resection of lumbar disc herniations via the interlaminar and lateral transforaminal approach. *J Neurosurg Spine* 2007; 6:521-530.
18. Ruetten S, Komp M, Merk H, Godolias G. Full-endoscopic interlaminar and transforaminal lumbar discectomy versus conventional micro-surgical technique: A prospective, randomized, controlled study. *Spine (Phila Pa 1976)* 2008; 33:931-939.
19. Kim JS, Choi G, Lee SH. Percutaneous endoscopic lumbar discectomy via contralateral approach: A technical case report. *Spine (Phila Pa 1976)* 2011; 36:E1173-E1178.
20. Choi G, Lee SH, Lokhande P, Kong BJ, Shim CS, Jung B, Kim JS. Percutaneous endoscopic approach for highly migrated intracanal disc herniations by foraminoplasty technique using rigid working channel endoscope. *Spine (Phila Pa 1976)* 2008; 33:E508-E515.
21. Lee S, Kim SK, Lee SH, Kim WJ, Choi WC, Choi G, Shin SW. Percutaneous endoscopic lumbar discectomy for migrated disc herniation: Classification of disc migration and surgical approaches. *Eur Spine J* 2007; 16:431-437.
22. Lee SH, Kang BU, Ahn Y, Choi G, Choi YG, Ahn KU, Shin SW, Kang HY. Operative failure of percutaneous endoscopic lumbar discectomy: A radiologic analysis of 55 cases. *Spine (Phila Pa 1976)* 2006; 31:E285-E290.
23. Jasper GP, Francisco GM, Telfeian AE. Endoscopic transforaminal discectomy for an extruded lumbar disc herniation. *Pain Physician* 2013; 16:E31-E35.
24. Choi G, Kim JS, Lokhande P, Lee SH. Percutaneous endoscopic lumbar discectomy by transiliac approach: A case report. *Spine (Phila Pa 1976)* 2009; 34:443-446.
25. Yeung AT, Yeung CA. Minimally invasive techniques for the management of lumbar disc herniation. *Orthop Clin North Am.* 2007; 38:363-372.
26. John McCulloch. *Essentials of Spinal Microsurgery*. Lippincott-Raven Publishers, New York, 1998.
27. Choi G, Lee S-H, Raiturker PP, Lee S, Chae Y-S. Percutaneous endoscopic interlaminar discectomy for intracanalicular disc herniations at L5-S1 using a rigid working channel endoscope. *Operative Neurosurgery* 2006; 58:59-68.
28. Choi KC, Kim JS, Ryu KS, Kang BU, Ahn Y, Lee SH. Percutaneous endoscopic lumbar discectomy for L5-S1 disc herniation: Transforaminal versus interlaminar approach. *Pain Physician* 2013; 16:547-556.
29. Ahn Y, Lee SH, Lee JH, Kim JU, Liu WC. Transforaminal percutaneous endoscopic lumbar discectomy for upper lumbar disc herniation: Clinical outcome, prognostic factors, and technical consideration. *Acta Neurochir (Wien)* 2009; 151:199-206.