

Animal Study

## Comparison of Intrathecal Concentrations of Acyclovir following Epidural and Intravenous Administration in Rats

Jae Hun Kim, MD, PhD<sup>1</sup>, Mi Kyoung Lee, MD, PhD<sup>2</sup>, Jung Eun Kim, MD<sup>2</sup>, Se Hee Kim, MD<sup>2</sup>, and Sang Sik Choi, MD, PhD<sup>2</sup>

From: <sup>1</sup>Department of Anaesthesiology and Pain Medicine, Konkuk University Medical Center, Konkuk University School of Medicine, 120-1, Neungdong-ro, Gwangjin-gu, Seoul, Korea; <sup>2</sup>Department of Anaesthesiology and Pain Medicine, Korea University Guro Hospital, Guro-Dong 80, Guro-gu, Seoul, Korea

Address Correspondence: Sang Sik Choi, MD, PhD  
Department of Anaesthesiology and Pain Medicine  
Korea University Guro Hospital,  
Guro-Dong 80, Guro-gu  
Seoul, Korea  
E-mail: clonidine@empas.com

Disclaimer: There was no external funding in the preparation of this manuscript. Conflict of interest: Each author certifies that he or she, or a member of his or her immediate family, has no commercial association (i.e., consultancies, stock ownership, equity interest, patent/licensing arrangements, etc.) that might pose a conflict of interest in connection with the submitted manuscript.

Manuscript received: 10-06-2015  
Revised manuscript received: 11-25-2015  
Accepted for publication: 12-17-2015

Free full manuscript:  
[www.painphysicianjournal.com](http://www.painphysicianjournal.com)

**Background:** Herpes zoster is a disease caused by reactivation of varicella-zoster virus in sensory cranial nerves and dorsal root ganglion. Our presumption was that epidural administration of acyclovir near the viral burden could be more advantageous than intravenous (IV) administration. The cerebrospinal fluid (CSF) concentration of acyclovir after epidural administration was determined to be higher than that after IV administration in rats.

**Objective:** In this study, we tested the hypothesis that the concentration of acyclovir in CSF after epidural administration is higher than that achieved after IV administration in rats.

**Study Design:** A randomized controlled animal trial.

**Methods:** A total of 30 adult male Sprague-Dawley rats were used. The rats were randomly divided into 2 equal groups, epidural (Group Epi) and IV (Group IV) administration groups (n = 15). Group Epi was further subdivided into 3 groups according to acyclovir dosage; each group comprised 5 animals receiving injections at dosages of 0.3 mg, 0.6 mg, and 0.9 mg. Group IV was also subdivided into 3 groups receiving dosages of 3 mg, 6 mg, and 9 mg. We measured CSF and plasma acyclovir concentrations one hour after administration.

**Results:** In Group Epi, the median plasma concentrations of acyclovir were lower than that in CSF ( $P < 0.05$ ). In Group IV, the median plasma concentrations of acyclovir were significantly higher than that in CSF ( $P < 0.05$ ). The CSF concentrations of acyclovir in Group Epi were significantly higher than that in Group IV ( $P < 0.05$ ). The plasma concentrations of acyclovir in Group Epi were significantly lower than that in Group IV ( $P < 0.05$ ).

**Limitations:** There were no references of equivalent dosages of acyclovir between IV and epidural administration. However, it is obvious in this study that epidural administration of a low dose of acyclovir can more effectively increase its concentration in the intrathecal space than IV administration.

**Conclusions:** Epidural administration of acyclovir provides superior drug concentrations in the intrathecal space compared to IV administration.

**Key words:** Acyclovir, epidural injection, herpes zoster, varicella zoster virus

**Pain Physician 2016; 19:E613-E619**

**A**lthough herpes zoster is not a fatal disease in most cases, it can cause severe zoster-related pain, including both acute zoster pain and chronic postherpetic neuralgia pain (1,2). More than 95% of adults in developed countries are

seropositive for the varicella zoster virus and thus, are at risk of developing acute herpes zoster (3,4). Herpes zoster is a disease caused by the reactivation of latent varicella-zoster virus in sensory cranial nerves and dorsal root ganglion (2,5). The skin

vesicles of herpes zoster are caused by the peripheral delivery of the virus from adjacent sensory ganglia to the skin (6,7). Anatomic study of autopsy tissue in postherpetic neuralgia revealed degeneration of the dorsal horn and damage with accompanying fibrosis in the sensory ganglion (8). Thus, herpes zoster can induce damage to both the peripheral and central nervous system. It is well known that early treatment with antiviral agents can effectively reduce zoster-related pain and the progression to postherpetic neuralgia (9-11). Antiviral drug administration to the viral burden via oral or intravenous (IV) routes are only effective after their absorption. Therefore, high doses of the drug must be used, and the resulting high systemic levels of the drug could induce side effects. If the drug could be administered near the target area, such as the dorsal root ganglion, the source of reactivation in the spinal cord in the early stage of herpes zoster, then the drug might demonstrate effectiveness at smaller doses with decreased side effects. In this study, we tested the hypothesis that the concentration of acyclovir in cerebrospinal fluid after epidural administration is higher than that achieved after IV administration in rats.

## METHODS

This investigation was performed after approval by the Institutional Animal Care and Use Committee at the affiliated institution. Thirty male Sprague-Dawley rats, weighing 250 to 300 g, were purchased from Dual Laboratories, Inc. (Seoul, Korea). All rats were kept in a standardized environment at a constant temperature of 21°C, 12 hour light and dark cycle, and 55% humidity. Rats were allowed free access to water and food. They were acclimatized to the environment of the laboratory for 7 days before random allocation by use of a random number table into 2 groups: epidural (Group Epi) and IV (Group IV) administration groups. Each group was divided into 3 subgroups with 5 rats each according to the administered dose of acyclovir. Group Epi consisted of Group Epi 0.3, Group Epi 0.6, and Group Epi 0.9, with an administration dose of 0.3 mg, 0.6 mg, and 0.9 mg, respectively. Group IV consisted of Group IV 3, Group IV 6, and Group IV 9, with an administration dose of 3 mg, 6 mg, and 9 mg, respectively.

### Group Epi

For IV sampling, a 24G IV catheter (Jelco I.V. catheter, Smith Medical, Rossendale, Lancashire, UK) was inserted into the rat's tail vein using the Seldinger

technique. Anaesthesia was performed by intraperitoneal injection of 50 mg/kg phenobarbital, and after loss of consciousness, hair at the lower thoracic spine was removed and sterile dressing was performed. A skin incision at the T11 level was made, and laminectomy was conducted. A polyethylene catheter (PE-10 tubing, Becton Dickinson, USA) was inserted into the epidural space. The tip of catheter was gently advanced about 2 cm in the caudal direction. The catheter was fixed with fascia by suturing, and subcutaneous tissue and skin were sutured as well.

In each group, 100  $\mu$ L acyclovir at 3 mg/mL (Group Epi 0.3, n = 5), 6 mg/mL (Group Epi 0.6, n = 5), or 9 mg/mL (Group Epi 0.9, n = 5) was injected via epidural catheter.

### Group IV

For IV injection and sampling, a 24G IV catheter (Jelco I.V. catheter, Smith Medical, Rossendale, Lancashire, UK) was inserted into the rat's tail vein using the Seldinger technique.

In each group, acyclovir at 3 mg (Group IV 3, n = 5), 6 mg (Group IV 6, n = 5), or 9 mg (Group IV 9, n = 5), mixed with saline (2 mL), was injected via IV catheter.

### Blood Sampling and CSF Tapping

One hour after acyclovir injection in each group, blood and CSF samples were taken. The blood sample (1 mL) was gently drawn from the IV catheter. CSF (1 mL) was aspirated from the cisterna magna after careful dural puncture. After centrifugation at 3500 rpm and 4°C for 10 minutes, the upper layer was separated from the blood and CSF samples and stored in cryogenic freezer at -70°C.

Lastly, all rats were sacrificed under anaesthesia by transcardial perfusion with 4% paraformaldehyde in 0.1 M phosphate buffer. The positions of the catheter tip of all rats were identified with the naked eye, and the correct placement of the epidural catheter was confirmed by epidural injection of Evans blue (10%). After pre-treatment for deproteinization, quantitative analysis of the clinical specimen was performed by liquid chromatography-tandem mass spectrometry. In this analysis, the standard for acyclovir was USP acyclovir (Santec Chemicals Corporation in Fresh Meadows, NY, US) and internal standard was penciclovir (CalBiochem, San Diego, CA, US). The plasma and CSF acyclovir concentrations were measured using a calibration curve with the ratio of peak area of acyclovir to peak area of internal standard.

## Comparison of Intrathecal Concentrations of Acyclovir

Table 1. CSF and plasma concentrations of acyclovir one hour after epidural or IV administration.

Injection		Sampling		Acyclovir Concentration (ng/mL)	
Group	Dose	Site	Median	25 %	75%
Group Epi	0.3 mg	Plasma	137.1	73.6	156.5
		CSF	3636.5*	2298.7	4849.6
	0.6 mg	Plasma	156.6	149.3	181.6
		CSF	14980.5*	12440.2	15645.5
	0.9 mg	Plasma	236.5	214.6	242.4
		CSF	16639.2*	15993.5	21610.1
Group IV	3 mg	Plasma	670.9	585.4	926.0
		CSF	176.0*	159.0	206.9
	6 mg	Plasma	1805.5	1720.9	2158.5
		CSF	289.4*	252.3	297.3
	9 mg	Plasma	2909.1	2865.0	3860.1
		CSF	381.2*	340.7	431.5

Group Epi: Epidural administration group, Group IV: IV administration group. The data are expressed as medians, with twenty-fifth/seventy-fifth percentile. \*  $P < 0.05$ , compared with plasma concentration of acyclovir.

### Statistical Analysis

The results were analyzed by Sigastat ver. 11.0 (Systat Software Inc., USA). The comparison between the concentration of Group IV and Group Epi was analyzed by the Mann-Whitney Rank Sum Test.  $P < 0.05$  was considered statistically significant.

### RESULTS

The concentration of acyclovir in the blood and CSF one hour after injection is shown in Table 1.

All epidural catheters were placed correctly in the epidural space, which was confirmed by epidural injection of Evans blue (Fig. 1).

In Group Epi (Group Epi 0.3, Group Epi 0.6, and Group Epi 0.9), the median concentrations of acyclovir in the plasma were lower than that in CSF ( $P < 0.05$ ), as seen in Fig. 2 and Table 1. In Group IV (Group IV 3, Group IV 6, and Group IV 9), the median concentrations of acyclovir in the plasma were significantly higher than that in CSF ( $P < 0.05$ ), as seen in Fig. 3 and Table 1.

The CSF concentrations of acyclovir in Group Epi 0.3, Group Epi 0.6, and Group Epi 0.9 were significantly higher than that in Group IV 3, Group IV 6, and Group IV 9 ( $P < 0.05$ ), as seen in Fig. 4.

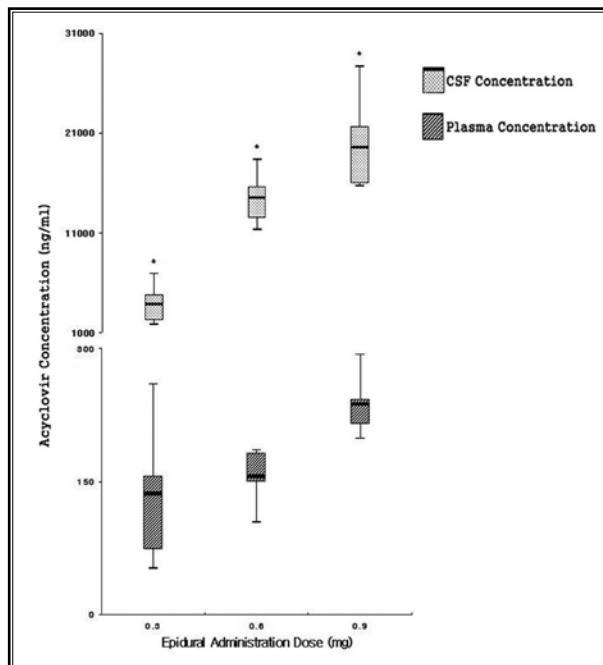
The plasma concentrations of acyclovir in Group Epi 0.3, Group Epi 0.6, and Group Epi 0.9 were significantly lower than that in Group IV 3, Group IV 6, and Group IV 9 ( $P < 0.05$ ).

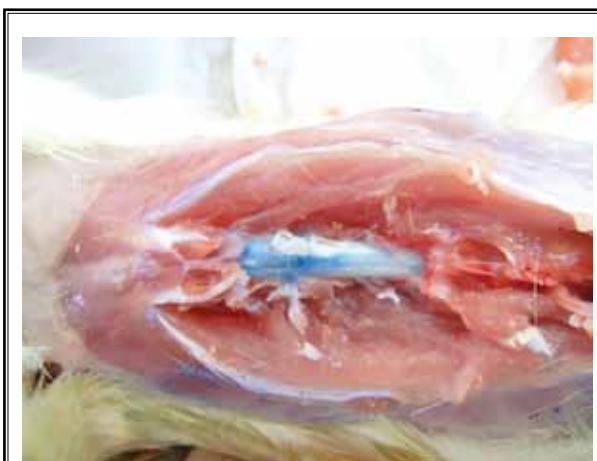

Fig. 1. Correct placement of the epidural catheter was confirmed by injection of Evans blue (10%) via epidural catheter. Evans blue staining of the epidural space is shown.

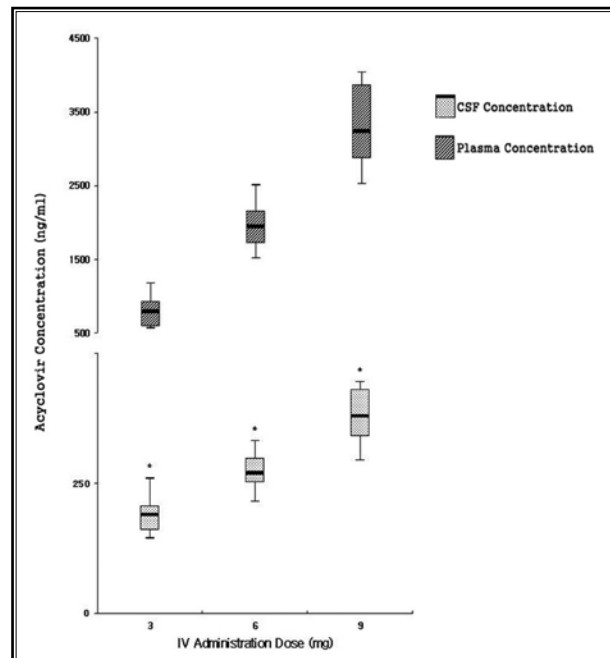
### DISCUSSION

The epidural administration of a lower concentration of acyclovir (one-tenth of IV) guarantees a higher concentration in the CSF than IV administration. Even one-thirtieth of the epidural dose resulted in a significantly higher concentration of acyclovir in the intrathecal space, as seen when comparing Group Epi



**Fig. 2. Comparison of acyclovir concentration in CSF and plasma at one hour after epidural injection in Group Epi.**

Group Epi: Epidural administration group. Values are expressed as Box plot. The upper hinge of the box indicates the seventy-fifth percentile of the data set, and the lower hinge indicates the twenty-fifth percentile. The line in the box indicates the median value of the data. The ends of the vertical lines indicate the minimum and maximum values. \*  $P < 0.05$ , compared with plasma concentration.



**Fig. 3. Comparison of acyclovir concentration in CSF and plasma at one hour after intravenous injection in Group IV.**

Group IV: IV administration group. Values are expressed as a Box plot. The upper hinge of the box indicates the seventy-fifth percentile of the data set, and the lower hinge indicates the twenty-fifth percentile. The line in the box indicates the median value of the data. The ends of the vertical lines indicate the minimum and maximum values.

\*  $P < 0.05$ , compared with plasma concentration.

0.3 and Group IV 9 (Fig. 4). Therefore, epidural administration of acyclovir effectively leads to its higher CSF concentrations.

The purpose of administering antiviral drugs is to transfer the drug to the target pathogen. In patients with herpes zoster, the virus persists in sensory ganglion, such as the dorsal root or cranial nerve ganglia (5,12). The viruses spread from the ganglion to neural tissue and its corresponding dermatome (12). Therefore, epidural administration of acyclovir can be a relatively direct route of administering the antiviral drug to the viral activation source. The virus destroys affected nerves and leads to an immune response that includes inflammation, haemorrhagic necrosis, and neuronal loss within the affected spinal ganglia (13-15). Early administration of the antiviral drug to the affected nerve can minimize these harmful responses. Thus, early treatment is important in reducing zoster-related pain and preventing complications (16,17). An-

tiviral drugs can effectively decrease the incidence of new lesion formation as well as accelerate healing and improve pain management (9). In addition, they can decrease the duration of viral shedding and may reduce neuronal damage (18). Their use is related to the reduced incidence, severity, and duration of zoster-related pain. If the virus is detected in the peripheral tissues, systemic administration of the antiviral may be more effective than epidural administration. Nevertheless, in varicella zoster infection, the virus spreads from the dorsal root ganglion or cervical sensory ganglion to the peripheral nerves and skin. Therefore, we hypothesized that epidural injection of acyclovir could effectively inhibit the regeneration of the herpes zoster virus and control the symptoms. Epidural administration of acyclovir may also effectively reduce the risk of complications within the spinal ganglia. However, further investigations regarding these hypotheses are necessary.

## Comparison of Intrathecal Concentrations of Acyclovir

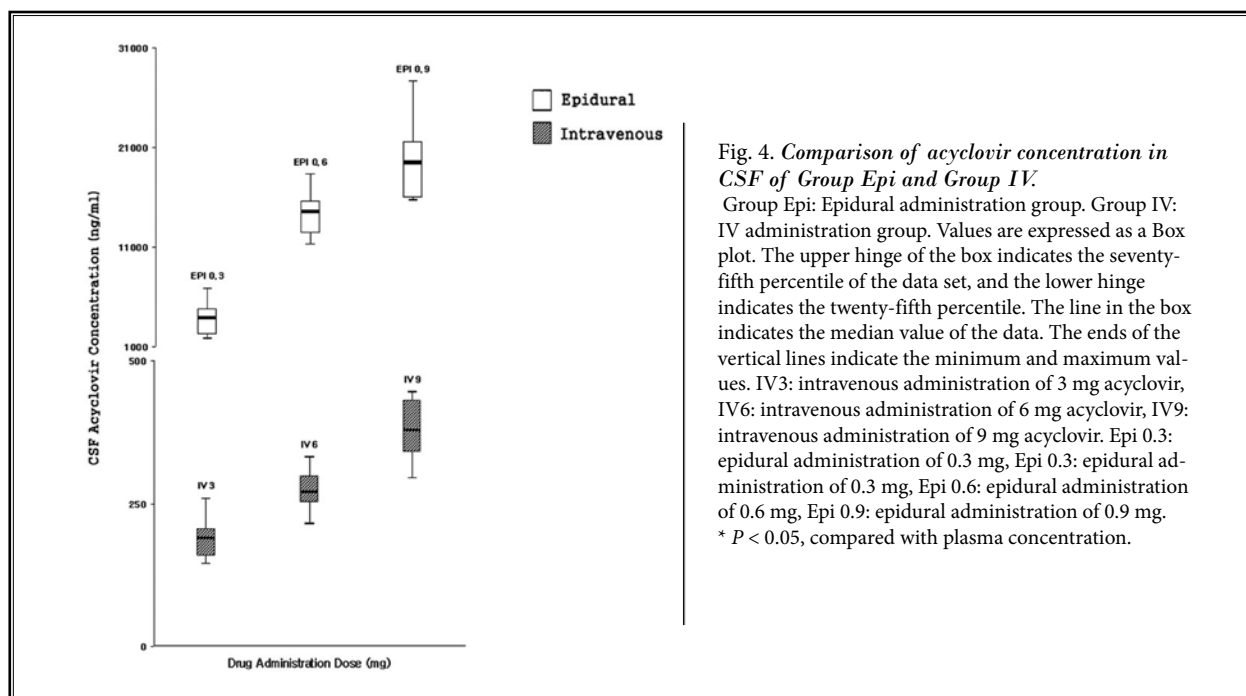


Fig. 4. Comparison of acyclovir concentration in CSF of Group Epi and Group IV. Group Epi: Epidural administration group. Group IV: IV administration group. Values are expressed as a Box plot. The upper hinge of the box indicates the seventy-fifth percentile of the data set, and the lower hinge indicates the twenty-fifth percentile. The line in the box indicates the median value of the data. The ends of the vertical lines indicate the minimum and maximum values. IV3: intravenous administration of 3 mg acyclovir, IV6: intravenous administration of 6 mg acyclovir, IV9: intravenous administration of 9 mg acyclovir. Epi 0.3: epidural administration of 0.3 mg, Epi 0.6: epidural administration of 0.6 mg, Epi 0.9: epidural administration of 0.9 mg. \*  $P < 0.05$ , compared with plasma concentration.

Side effects of acyclovir include dysarthria, involuntary movements, ataxia, disturbed consciousness, hyper-reflexia, and cerebral dysfunctions (confusion, hallucination, and lethargy) (19-21). The major route of elimination is through renal excretion. High concentrations of acyclovir in the serum can cause delirium and other reversible neurologic symptoms in patients with renal impairment or elderly patients (22). Low plasma concentrations of the drug can be correlated with low systemic toxicity, which is related to their maximal plasma levels. Therefore, administration of a decreased dose can reduce side effects. The results of this study show that epidural administration of a lower dose results in intrathecal levels similar to that achieved after IV administration. In a previous study using rats, there was no evidence of neurological (behavioral change or sensory-motor dysfunction) or histopathological abnormalities following the intrathecal administration of acyclovir (23). Administration of a lower dose of acyclovir into the epidural space can decrease the risks of side effects due to the relatively lower amount of acyclovir administered compared to that by the IV route. Compared to IV administration, epidural administration results in decreased serum levels of acyclovir in renally impaired or elderly patients, resulting in a safer treatment option for herpes zoster. Further studies regarding the safety of epidural administration must be

conducted in patients with herpes zoster.

In this study, the IV dose of acyclovir in rats was chosen based on the adult dosage of acyclovir (10 mg/kg) for herpes zoster. We found no references for an epidural dose of acyclovir. Therefore, we used the equianalgesic ratio (1/10) of epidural morphine and IV morphine in humans.

In epidural drug administration, intrathecal concentrations are related to injection methods (one-off vs. continuous), the dose of administration, lipophilicity, distribution into fatty tissue, and absorption into systemic circulation (24-27). Diffusion through the multiple meningeal barriers between the epidural and intrathecal space is the main process controlling drug elimination, and the most important factor for drug transportation from the epidural to intrathecal space (25,27,28). Lipophilic drugs remain longer in the epidural space, with negligible access to the intrathecal space (27,29,30). They have rapid vascular uptake in the epidural space (27). However, the hydrophilic character of morphine is consistent with its slow clearance in the intrathecal space (26). The main excretory pathway in the intrathecal space is absorption through blood vessels, and hydrophilic drugs have slow vascular uptake (26,27,31). Therefore, hydrophilicity increases drug potency and bioavailability in the intrathecal space (28,32). In this study, the high concentration of

acyclovir in the intrathecal space is consistent with its low molecular weight and hydrophilic character. The molecular weight of acyclovir is 225.21 g/mol, lower than morphine (285.34 g/mol). The low molecular weight of acyclovir allows it to easily diffuse through multiple meningeal barriers. Once in intrathecal space, the hydrophobic character of acyclovir allows it to be maintained at high concentrations. Therefore, epidural administration can be an effective option for acyclovir administration in the intrathecal space, spinal cord, and spinal nerve.

This study has some limitations. There were no references of equivalent dosages of acyclovir between IV and epidural administration. However, it is obvious in the present study that epidural administration of a low dose of acyclovir can more effectively increase its concentration in the intrathecal space than IV administration. In this study, we did not measure the pharmacokinetics of IV/epidural administration of acyclovir in rats. To our knowledge, there is no literature regarding epidural administration of acyclovir in animals or humans. Therefore, this is the first study about epidural administration of acyclovir. Further investigation of the pharmacokinetics is needed.

To administer acyclovir epidurally in humans, several investigations are necessary. First, the safety of

acyclovir in the epidural space should be determined in humans. Second, the dose of administration in the epidural space needed for treatment should be investigated. Third, the effectiveness of epidural administration for treatment of herpes zoster should be studied. The present study simply shows the potential use of intrathecal administration of acyclovir in the treatment of herpes zoster.

## CONCLUSION

Epidural administration of acyclovir at a lower dose than IV provides superior drug concentrations in the intrathecal space.

## Conflict of Interest Statement

The authors declare that they have no conflicts of interest.

We have no financial or funding support of this work.

## Authors' Contributions

MKL and SSC designed the experiments. JHK, MKL, SHK, and SSC performed the experiments. JEK and SSC analyzed the data. JHK and SSC wrote the manuscript. All authors contributed to editing the manuscript.

## REFERENCES

- Hillebrand K, Bricout H, Schulze-Rath R, Schink T, Garbe E. Incidence of herpes zoster and its complications in Germany, 2005-2009. *J Infect* 2015; 70:178-186
- Reda H, Greene K, Rice FL, Rowbotham MC, Petersen KL. Natural history of herpes zoster: Late follow-up of 3.9 years (n = 43) and 7.7 years (n = 10). *Pain* 2013; 154:2227-2233.
- Kim KH. Herpes zoster vaccination. *Korean J Pain* 2013; 26:242-248.
- Johnson RW. Herpes zoster and postherpetic neuralgia. *Expert Review of Vaccines* 2010; 9:21-26.
- Thyregod HG, Rowbotham MC, Peters M, Possehn J, Berro M, Petersen KL. Natural history of pain following herpes zoster. *Pain* 2007; 128:148-156.
- Kinchington PR, Goins WF. Varicella zoster virus-induced pain and post-herpetic neuralgia in the human host and in rodent animal models. *Journal of Neurovirology* 2011; 17:590-599.
- Gilden D, Mahalingam R, Nagel MA, Pugazhenthai S, Cohrs RJ. Review: The neurobiology of varicella zoster virus infection. *Neuropathology and Applied Neurobiology* 2011; 37:441-463.
- Watson CP, Deck JH, Morshead C, Van der Kooy D, Evans RJ. Post-herpetic neuralgia: Further post-mortem studies of cases with and without pain. *Pain* 1991; 44:105-117.
- Whitley RJ, Volpi A, McKendrick M, Wijck A, Oaklander AL. Management of herpes zoster and post-herpetic neuralgia now and in the future. *J Clin Virol* 2010; 48:S20-S28.
- Benzon HT, Chekka K, Darnule A, Chung B, Wille O, Malik K. Evidence-based case report: The prevention and management of postherpetic neuralgia with emphasis on interventional procedures. *Reg Anesth Pain Med* 2009; 34:514-521.
- Kim JH. Risk factor and prevention of postherpetic neuralgia. *Korean J Pain* 2015; 28:167-168.
- Schmader KE, Dworkin RH. Natural history and treatment of herpes zoster. *The Journal of Pain* 2008; 9:S3-S9.
- Amlie-Lefond C, Kleinschmidt-DeMasters BK, Mahalingam R, Davis LE, Gilden DH. The vasculopathy of varicella-zoster virus encephalitis. *Annals of Neurology* 1995; 37:784-790.
- Kleinschmidt-DeMasters BK, Gilden DH. Varicella-Zoster virus infections of the nervous system: Clinical and pathologic correlates. *Archives of Pathology & Laboratory Medicine* 2001; 125:770-780.
- Oaklander AL. Mechanisms of pain and itch caused by herpes zoster (shingles). *The Journal of Pain* 2008; 9:S10-S18.
- Kim SR, Khan F, Ramirez-Fort MK, Downing C, Tyring SK. Varicella zoster: An update on current treatment options and future perspectives. *Expert Opinion on Pharmacotherapy* 2014; 15:61-71.

17. Chen N, Li Q, Yang J, Zhou M, Zhou D, He L. Antiviral treatment for preventing postherpetic neuralgia. *Cochrane Database Syst Rev* 2014; 2:CD006866.
18. Cohen JI. Clinical practice: Herpes zoster. *N Engl J Med* 2013; 369:255-263.
19. Hellden A, Lycke J, Vander T, Svensson JO, Odar-Cederlof I, Stahle L. The aciclovir metabolite CMMG is detectable in the CSF of subjects with neuropsychiatric symptoms during aciclovir and valaciclovir treatment. *The Journal of Antimicrobial Chemotherapy* 2006; 57:945-949.
20. Almond MK. Aciclovir and valaciclovir neurotoxicity in patients with renal failure. *Nephrology, Dialysis, Transplantation* 2003; 18:2680; author reply 2680-2681.
21. Strumia S, De Mitri P, Bionda E. Neurotoxicity of acyclovir and valacyclovir in a hemodialyzed patient. *European Journal of Neurology* 2004; 11:68-69.
22. Bean B, Aeppli D. Adverse effects of high-dose intravenous acyclovir in ambulatory patients with acute herpes zoster. *The Journal of Infectious Diseases* 1985; 151:362-365.
23. Kim H, Choi YL, Lee DK, Choi SS, Lee IO, Kong MH, Kim NS, Lim SH, Lee M. The neurological safety of intrathecal acyclovir in rats. *Pain Physician* 2012; 15:E107-E113.
24. Ratajczak-Enselme M, Estebe JP, Dollo G, Chevanne F, Bec D, Malinovsky JM, Ecoffey C, Le Corre P. Epidural, intrathecal and plasma pharmacokinetic study of epidural ropivacaine in PLGA-microspheres in sheep model. *Eur J Pharm Biopharm* 2009; 72:54-61.
25. McQuay HJ, Sullivan AF, Smallman K, Dickenson AH. Intrathecal opioids, potency and lipophilicity. *Pain* 1989; 36:111-115.
26. Ummenhofer WC, Arends RH, Shen DD, Bernards CM. Comparative spinal distribution and clearance kinetics of intrathecally administered morphine, fentanyl, alfentanil, and sufentanil. *Anesthesiology* 2000; 92:739-753.
27. Bernards CM, Shen DD, Sterling ES, Adkins JE, Risler L, Phillips B, Ummenhofer W. Epidural, cerebrospinal fluid, and plasma pharmacokinetics of epidural opioids (part 1): Differences among opioids. *Anesthesiology* 2003; 99:455-465.
28. Sjostrom S, Hartvig P, Persson MP, Tamsen A. Pharmacokinetics of epidural morphine and meperidine in humans. *Anesthesiology* 1987; 67:877-888.
29. Coda BA, Brown MC, Schaffer RL, Donaldson G, Shen DD. A pharmacokinetic approach to resolving spinal and systemic contributions to epidural alfentanil analgesia and side-effects. *Pain* 1995; 62:329-337.
30. Glass PS, Estok P, Ginsberg B, Goldberg JS, Sladen RN. Use of patient-controlled analgesia to compare the efficacy of epidural to intravenous fentanyl administration. *Anesthesia and Analgesia* 1992; 74:345-351.
31. Bernards CM. Sophistry in medicine: Lessons from the epidural space. *Reg Anesth Pain Med* 2005; 30:56-66.
32. Nordberg G, Hedner T, Mellstrand T, Dahlstrom B. Pharmacokinetic aspects of epidural morphine analgesia. *Anesthesiology* 1983; 58:545-551.

