

Brief Commentary

e Multi-Modal Treatment Approach to Painful Rib Syndrome: Case Series and Review of the Literature

Andrew Germanovich, DO¹, and Francis Michael Ferrante, MD²

From: ¹Desert Pain and Rehabilitation, Rancho Mirage, CA; ²Department of Anesthesiology, University of California Los Angeles, Santa Monica, CA

Address Correspondence: Andrew Germanovich, DO Staff Physician Desert Pain and Rehabilitation 71780 San Jacinto Dr Bldg D Rancho Mirage, CA 92270 E-mail: Ukster1@yahoo.com

Disclaimer: There was no external funding in the preparation of this manuscript. Conflict of interest: Each author certifies that he or she, or a member of his or her immediate family, has no commercial association (i.e., consultancies, stock ownership, equity interest, patent/licensing arrangements, etc.) that might pose a conflict of interest in connection with the submitted manuscript.

Manuscript received: 03-26-2015
Revised manuscript received: 07-28-2015
Accepted for publication: 08-02-2015

Free full manuscript: www.painphysicianjournal.com

Background: Mechanical chest wall pain is a common presenting complaint in the primary care office, emergency room, and specialty clinic. Diagnostic testing is often expensive due to similar presenting symptoms that may involve the heart or lungs. Since the chest wall biomechanics are poorly understood by many clinicians, few effective treatments are offered to patients with rib-related acute pain, which may lead to chronic pain.

Objective: This case series and literature review illustrates biomechanics involved in the pathogenesis of rib-related chest wall pain and suggests an effective multi-modal treatment plan using interventional techniques with emphasis on manual manipulative techniques.

Study Design: Case series and literature review.

Setting: Pain clinic in an academic medical center.

Results: This is a case series of 3 patients diagnosed with painful rib syndrome using osteopathic palpatory physical examination techniques. Ultrasound-guided intercostal nerve blocks were followed by manual manipulation of mechanically displaced ribs as a part of our multi-modal treatment plan. A review of the literature was undertaken to clarify nomenclature used in the description of rib-related pain, to describe the biomechanics involved in the pathogenesis of mechanical rib pain, and to illustrate the use of effective manual manipulation techniques.

Limitation: This review is introductory and not a complete review of all manual or interventional pain management techniques applicable to the treatment of mechanical rib-related pain.

Conclusions: Manual diagnostic and therapeutic skills can be learned by physicians to treat biomechanically complex rib-related chest wall pain in combination with interventional image-guided techniques. Pain physicians should learn certain basic manual manipulation skills both for diagnostic and therapeutic purposes.

Key words: Chest wall pain, rib pain, intercostal neuralgia, slipping rib syndrome, chest pain, intercostal nerve block, chest trauma

Pain Physician 2016; 19:E465-E471

Pain arising from the chest wall is often a frightening experience due to real or imagined life-threatening conditions involving the heart or lungs, which often leads to extensive and costly diagnostic testing. In many cases no attributable cause is ever found. Mechanical chest wall disorders are a

frequent cause of pain but are not often recognized as such, as they are poorly understood.

Rib dysfunction has long been recognized as a potential etiology of chest wall and upper abdominal pain (1). In 1922 Davies-Colley coined the term "slipping rib syndrome" in his description of rib dysfunction.

tion as an etiology of anterior chest wall pain (2). In 1977 Heinz and Zavala proposed a “hooking maneuver” during physical examination to confirm the diagnosis (3). In 1980 Wright wrote a detailed review on the subject in *Lancet*, documenting an incidence of 1% – 5%, but admitted that the underlying mechanism was poorly understood (4). Real-time ultrasound imaging has been used to document changes in rib positioning in relation to painful episodes (5). Terminology used to describe rib dysfunction during review of the literature includes slipped rib syndrome, Tietze’s syndrome, clicking rib syndrome, and painful rib syndrome (6,7). Regardless of the nomenclature, no effective treatments have been proposed to manage the pain other than intercostal nerve blocks or surgical rib resection (8-10). This is unfortunate as it has been estimated that the pain secondary to untreated rib dysfunction will become chronic in 87% of patients (11). We present a case series of 3 patients with painful rib syndrome and suggest a multimodal treatment scheme.

CASE PRESENTATIONS

Internal Review Board approval was obtained to review medical records.

Patient 1 was a 62 year-old-woman with acute onset of severe posterior and anterior lower chest wall pain on the right, following a fall in a bathtub 6 weeks prior. Computed tomography (CT) of the chest, magnetic resonance imaging (MRI) of the thoracic spine, and extensive metabolic work up were normal. This patient failed medication therapy and was unable to tolerate physical therapy secondary to pain. Osteopathic examination revealed ribs 6 – 9 in exhalation dysfunction on the right with pain on deep inspiration. An ultrasound-guided intercostal nerve block was performed at these levels at the posterior rib angles (7 cm lateral from spinous process) using 3 mL of 0.25% bupivacaine via 22 gauge, 50 mm laser-etched block needle. Osteopathic manual manipulation was utilized to replace affected ribs into a neutral position 30 minutes after the intercostal neural blockade. Pain relief was complete after a one month follow-up visit.

Patient 2 was a 72 year-old-woman who presented with left lateral chest wall pain of few months duration. She denied any history of trauma. The onset of pain occurred after episodes of frequent coughing associated with a respiratory tract infection. A CT of the abdomen, MRI of the thoracic spine, and abdominal ultrasound were negative for acute pathology. Physical examination revealed restriction of rib 10 on inspira-

tion. Ultrasound-guided intercostal nerve blockade of the left 9, 10, and 11 ribs was performed using the same materials and technique as above. Manual manipulation was used to mobilize rib 10 into a neutral position after 30 minutes. The patient was pain-free at the follow-up visit.

Patient 3 was a 30 year-old-man with a 5 year history of persistent left anterior chest wall pain. He denied any history of trauma, injury, or pulmonary infections prior to the onset of pain. Radiographic imaging, MRI, electromyography, and other work-up did not reveal any abnormalities in the neck or chest. Prior treatments included thoracic epidurals, costochondral joint injections, physical therapy, and pharmacotherapy. Physical examination revealed right rib 5 exhalation dysfunction. Ultrasound-guided intercostal neural blockade of the left 4 – 6 ribs was performed using the same medications and technique as above. Manual mobilization of rib 5 was performed 30 minutes after the intercostal nerve block. The patient was pain-free during the follow-up visit for the first time in 5 years.

Review of anatomy

Twelve sets of ribs correspond with 12 thoracic vertebral segments. Each rib is composed of a bony segment which articulates posteriorly at the costovertebral articulations and anteriorly at costochondral articulations. Ribs 1, 11, and 12 are considered atypical since they lack costal grooves and have a single articular surface posteriorly. Ribs 1 through 7 attach to the sternum and are referred to as “true” ribs. Ribs 8 – 10 are false ribs since they do not directly attach to the sternum, but rather converge into a single cartilaginous mass. Ribs 11 and 12 are often called floating ribs and do not attach to the sternum. The heads of ribs 2 – 9 articulate with one vertebra above, one below, and with the transverse process of the corresponding vertebral body at the rib angle via synovial joints. These joints allow for rib gliding and rotational motion during ventilation.

Efficient ventilation involves over 100 joints in the thorax composed of bony, cartilaginous, and ligamentous structures. During inhalation, the thoracic cage widens its vertical, transverse, and anteroposterior dimensions with contraction of the diaphragm. Ribs 1 and 2 move in a more vertical orientation like a water pump handle when the chest is viewed in profile. Ribs 3 – 10 move primarily in a “bucket handle” motion more prominent in the coronal axis when the chest movement is viewed anteroposteriorly. The pump handle motion increases the sagittal diameter of the chest in

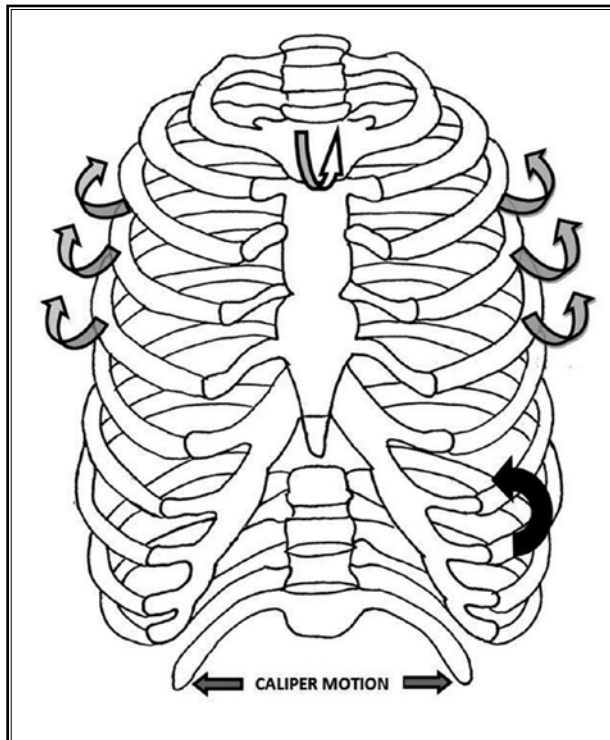


Fig. 1. Gray curved arrows – “bucket handle” motion of true ribs during inspiration laterally. Gray and white arrow – “pump handle” motion of upper ribs and sternum. Straight arrows – caliper motion of ribs 11 and 12 during inspiration. Single black curved arrow – slippage of inferior rib superiorly in slipping rib syndrome.

the upper thoracic region, while the bucket handle motion increases the coronal diameter in the lower thoracic region. Floating ribs 11 and 12 are entirely different and behave in a caliper or lobster claw-like motion in the transverse plane during ventilation (Fig. 1).

Contraction of the diaphragm elevates lower ribs on inspiration. In addition to the diaphragm, other principal muscles of inspiration are the external intercostals which during contraction elevate the bony ribs laterally, and internal intercostals which elevate the chondral portion of the ribs medially to produce the bucket handle motion (Fig. 2). Contraction of the rectus abdominis, external and internal obliques, transversus abdominis, and internal intercostals allows for expiration by depressing the ribs.

In osteopathic literature the nomenclature for rib dysfunction describes an abnormal motion of ribs in a cephalad or caudad direction and whether the rib is less or more prominent anteroposteriorly during ventilation. Rib dysfunction may be secondary to subluxation

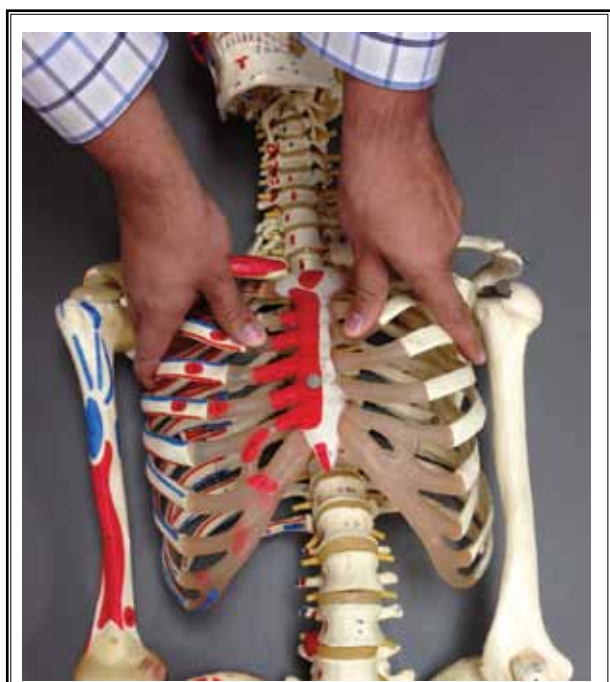

Fig. 2. Alternate hand placement for assessment of pump-handle motion at the head of the patient.

(most common with the first rib), external rib torsion, anteroposterior compression, lateral compression, or lateral flexion of a single rib or a group of ribs (12).

Rib dysfunction is named according to restriction of motion (12). Strong contraction of the rectus abdominis during a cough leads to a rapid change of rib position from inhalation (the large intercostal space between the ribs anteriorly) to exhalation (the small intercostal space between the ribs anteriorly). If a true rib gets “stuck” in this exhaled position, it will not rise with the rest of the ribs during inhalation. This restriction of motion is termed “exhalation dysfunction.” Exhalation dysfunction may be a result of persistent or harsh coughing.

The opposite is true for “inhalation dysfunction.” When one actively inspires forcefully or when one is struck into the chest wall during inspiration such as during falls or contact sports, the rib may get stuck in an elevated position and not return to a normal exhaled position with the rest of the ribs during passive exhalation. This leads to constant stretching of internal and external intercostal muscles and compression of the neurovascular bundle at the inferior intercostal space during normal breathing. This can lead to severe disabling nociceptive pain secondary to stretch injury

of the musculature and neuropathic pain secondary to compression of the neurovascular bundle. The associated soft tissue edema due to tissue irritation may be what Tietze observed in 1921 and what is now described as Tietze's syndrome (6).

Slipped rib syndrome describes slipping of costal cartilage of ribs 8, 9, and 10 behind or in front of the rib above due to weak interchondral joints (Fig. 1). This was shown to occur in patients with upper abdominal and lower anterior chest wall pain using high resolution ultrasound (5). This mechanism may explain chest wall pain due to dysfunction of ribs 8, 9, and 10, but not pain due to dysfunction of ribs 1 through 7 which have strong individual costosternal joints.

DIAGNOSIS

To diagnose rib dysfunction, a patient is placed supine on an examination table and instructed to breathe deeply while the physician stands on one side of the patient. For diagnosis of ribs 3 through 6 the physician's hands are placed on the upper anterior chest wall of the patient either from below (Fig. 3) or above (Fig. 2). The thumbs palpate the costochondral articulation of ribs to evaluate for anteroposterior movement of the pump handle motion and the hand digits 2 through 5 are placed on the body of ribs 3 through 6 at the midaxillary line to evaluate for the bucket handle motion. The same principle can be applied to assess the motion of ribs 7 through 10, where bucket handle mo-

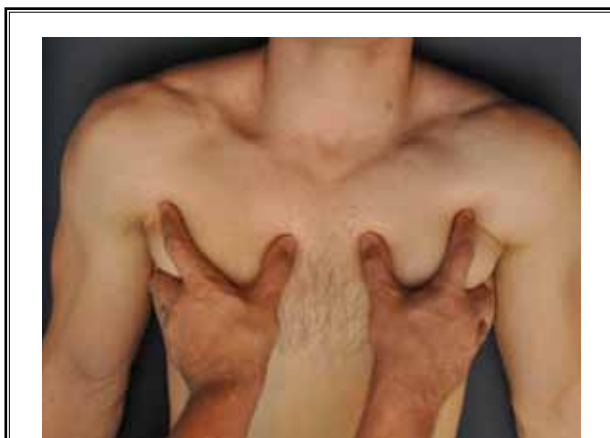


Fig. 3. Hand placement for palpation of upper rib motion. Thumbs are placed on sterno-costal joints. Index fingers on the bony aspect of the ribs anteriorly to assess pump-handle motion. Digits 3 – 5 are placed laterally to assess for bucket handle motion of lower ribs near mid-axillary line.

tion at the midaxillary line is more predominant during cephalad and caudad rib movements on inspiration and expiration (Fig. 4).

The dysfunctional rib will be more static compared to others during ventilation. Asymmetry of rib excursion will often accompany the painful symptoms. A rib with exhalation dysfunction on the symptomatic side will have less cephalad movement on inhalation laterally and may be more depressed anteriorly compared to ribs above and below. A rib with inhalation dysfunction on the symptomatic side will have less caudad movement on exhalation laterally and may be more prominent anteriorly compared to ribs above and below. This lack of movement can be visualized with inspiratory and expiratory chest x-rays.

TREATMENT

An intercostal nerve block with local anesthetic was first described in 1907 by Braun in the textbook *Die Lokalanästhesie* (14) and the first ultrasound guided intercostal nerve block was reported by Vaghadia et al in 1988 (13). With modern high resolution ultrasound, intercostal nerve blocks with local anesthetic are not difficult to perform but neither do they offer prolonged pain relief when used as monotherapy for persistent mechanical rib dysfunction. Manual therapy can be intolerable in the acute or subacute phase of painful rib syndrome. An ideal treatment approach should involve both treatment modalities for an optimal outcome.

Once a proper diagnosis of rib dysfunction has been made and the patient has received an intercostal nerve block to prevent pain and guarding, manual reduction of the rib can be performed using simple techniques of osteopathic manipulative medicine (OMM) (14).

For inhalation rib dysfunction of right ribs 2 to 6, the patient is placed supine on the examination table while resting his upper thorax on the physician's flexed right knee. The patient's thorax is slightly bent to the right side to decrease rib tension of the right chest wall. The physician's thumb and index finger are firmly placed on the superior border of the dysfunctional rib. The patient is then asked to inhale deeply. As the dysfunctional rib attempts to move more cephalad and become more pronounced with inhalation, it is resisted by the physician's hand. As the patient exhales, firm gentle pressure is applied caudally and into the chest. This is repeated through 5 to 6 ventilation cycles (Fig. 5). The same principle is applied to inhalation dysfunction of ribs 7 to 10 with more emphasis on the bucket handle motion by placing the hand more laterally. The patient

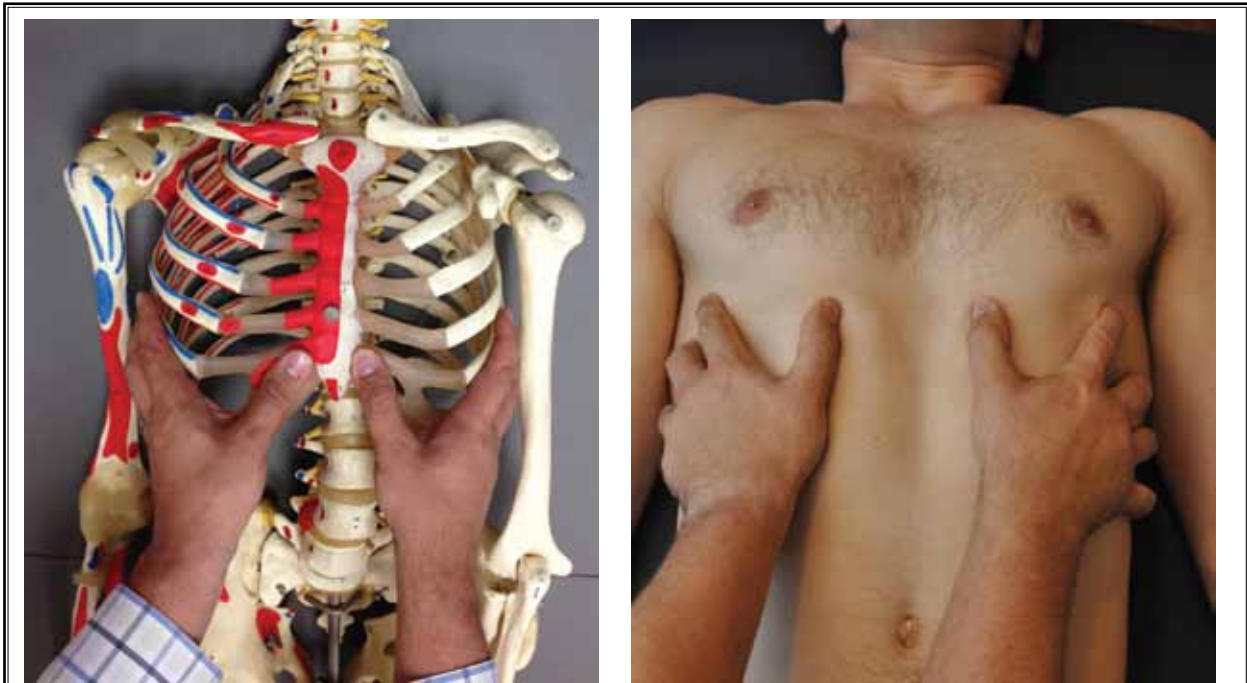

Fig. 4 and B *Assessment of motion for lower ribs, where bucket-handle rib mechanics predominate.*

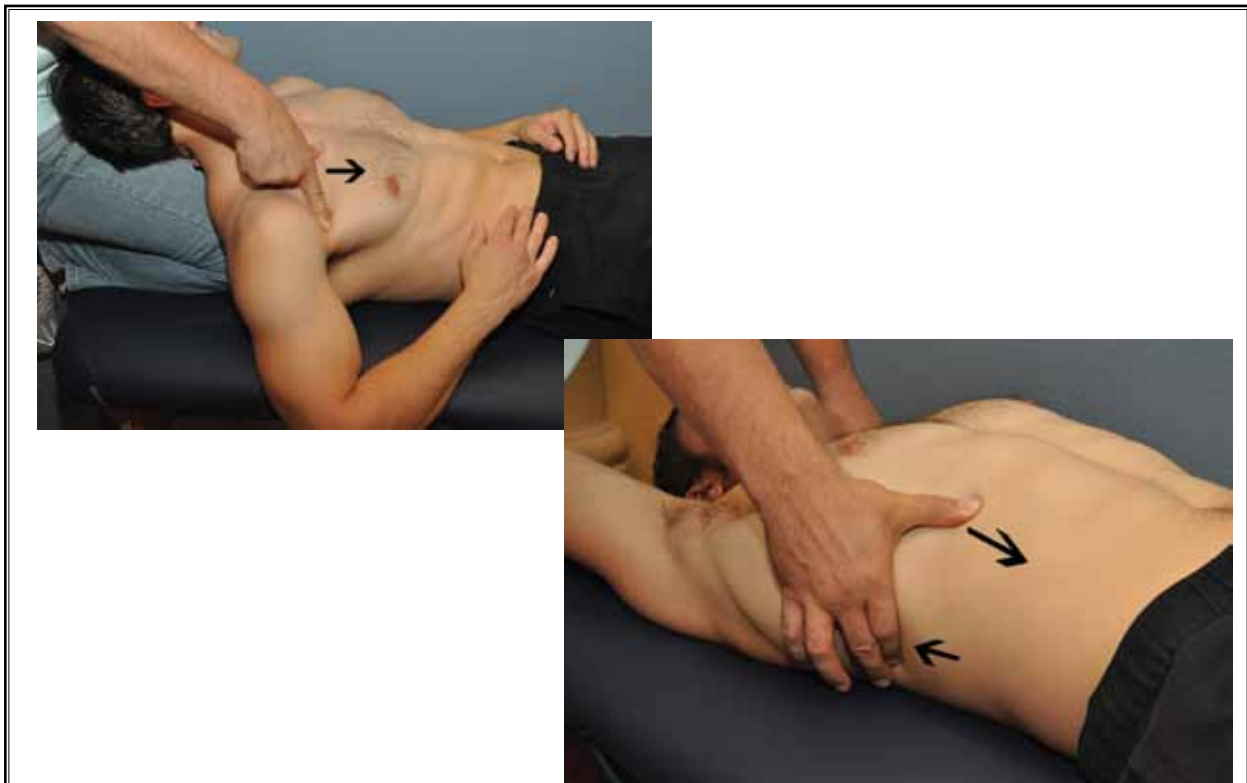

Fig. 5 A and B. *Manual treatment of inhalation rib dysfunction of upper and lower ribs.*

is asked to inhale and exhale deeply. During inhalation the bucket handle of the inhaled rib is resisted and during exhalation the physician applies caudad pressure with the thumb and resists cephalad motion of the rib posteriorly (Fig. 5).

Exhalation dysfunction leads to a persistent caudal static position of the rib anteriorly and a cephalad position posteriorly near articulation with transverse processes. These are more common and more challenging to treat. More than one technique may be required.

For treatment of exhalation dysfunction of right ribs 2 – 5, the patient is placed in a lateral position with right side up. The physician's thumb and first finger of the right hand rest against the superior border of the exhaled rib posteriorly. During inhalation, caudad migration of the rib posteriorly is enhanced with pressure applied caudally. Since

the rib motion is reciprocal anteriorly and posteriorly for upper ribs, isometric contraction of the pectoralis minor muscle by the patient (which attaches to the coracoid process and ribs 3 – 5) will pull these ribs cephalad anteriorly (Fig. 6).

For treatment of exhalation dysfunction of right ribs 6 – 10, the physician's thumb and first finger of the right hand rest against the superior border of the exhaled rib posteriorly. The left hand is positioned over the inferior border of the exhaled rib anteriorly. During inhalation, cephalad pressure is applied on the rib with the left hand anteriorly and caudad pressure is applied with the right hand posteriorly. During exhalation the rib is held static. Usually at least 5 deep slow breathing cycles are required.

Discussion

It is unfortunate that manual manipulation is not taught at allopathic medical schools in the United States. Manual therapy is cost-effective as a diagnostic and therapeutic treatment modality. In our 3 cases however, manual therapy alone was difficult to perform, and the patients could not undergo physical therapy secondary to intense pain with rib movement. Intercostal nerve blocks facilitate rib mobilization with sensory blockade (which decreases patient guarding) and motor blockade of external and internal intercostals (which may be acutely inflamed during rib dysfunction and resist rib mobilization during treatment). We propose that the combination therapy is superior to either treatment alone. All our patients experienced immediate temporary pain relief from ultrasound guided intercostal nerve blocks. This window of opportunity was used to mobilize dysfunctional ribs using simple techniques that are intuitive when used with anatomical models to treat the underlying biomechanical cause of the pain.

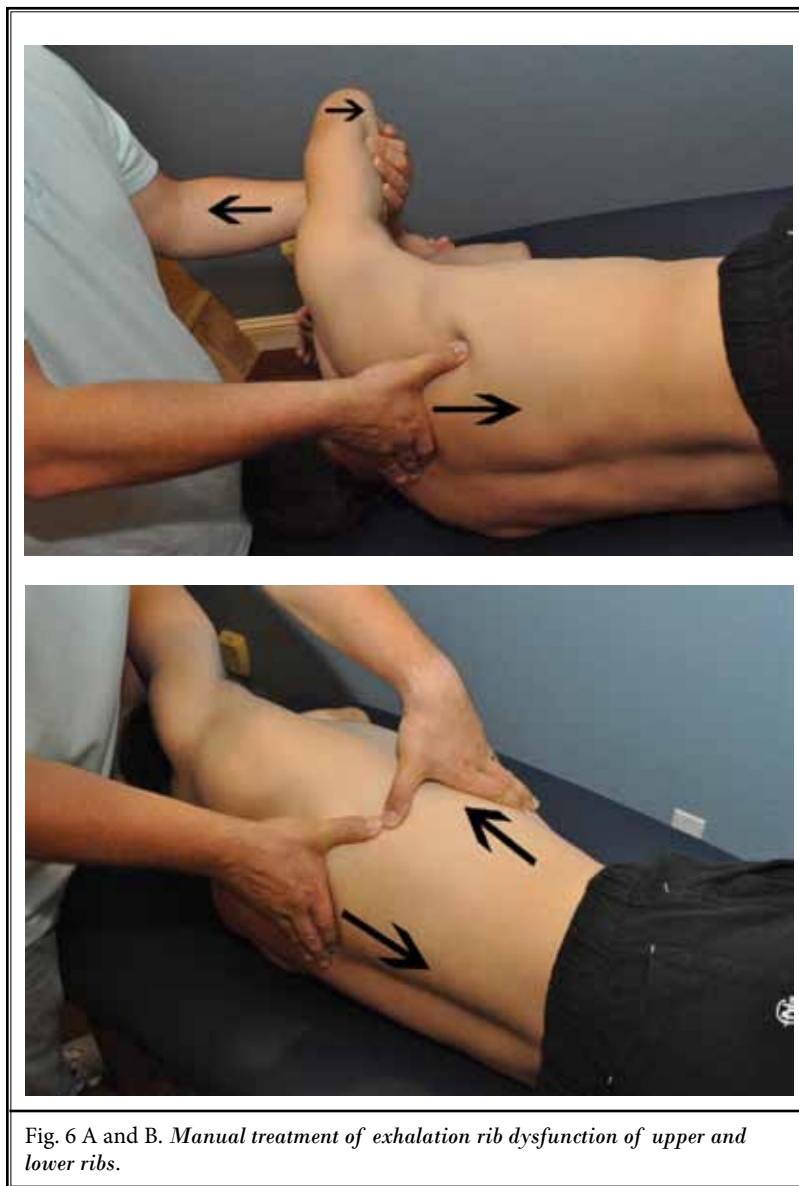


Fig. 6 A and B. Manual treatment of exhalation rib dysfunction of upper and lower ribs.

To our knowledge there are no cases in the literature that combine these techniques and we believe if they are employed more widely, this can be of great

benefit to the patients and to cost-conscious health care systems.

REFERENCES

1. Cyriax E. On various conditions that may simulate the referred pains of visceral disease and a consideration of these from the point of view of cause and effect. *Practitioner* 1919; 102:314-322.
2. Davies-Colley R. Slipping rib. *British Medical Journal* 1922; 1:432.
3. Heinz G, Zavala D. Slipping rib syndrome: Diagnosis using the "hooking maneuver." *JAMA* 1977; 237:794-795.
4. Wright J. Slipping-rib syndrome. *Lancet* 1980; 2:632-634.
5. Meuwly JY, Wicky S. Slipping rib syndrome. A place for sonography in the diagnosis of a frequently overlooked cause of abdominal or low thoracic pain. *J Ultrasound Med* 2002; 21:339-343.
6. Tietze A. "Über eine eigenartige Häufung von Fällen mit Dystrophie der Rippenknorpel." *Berliner Klinische Wochenschrift* 1921; 58:829-831.
7. Mynors JM. Clicking rib. *Lancet* 1973; 1:674.
8. Abbou S, Herman J. Slipping rib syndrome. *Postgrad Med* 1989; 86:75-78.
9. Dmitriev AE, Kriukov BN. [Tietze's syndrome]. *Khirurgiia* 1990; 9:7-10.
10. Copeland G, Machin D, Shennan J. Surgical treatment of the slipping rib syndrome. *Br J Surg* 1984; 71:522-523.
11. Scott EM, Scott BB. Painful rib syndrome-a review of 76 cases. *Gut* 1993; 34:1006-1008.
12. Ward R. *Foundations for Osteopathic Medicine*. Lippincott Williams & Wilkins, Philadelphia, 2003.
13. Vaghadia H, Jenkins LC. Use of a Doppler ultrasound stethoscope for intercostal nerve block. *Canadian Journal of Anaesthesia* 1988; 35:86-89. {
14. Braun H. *Die Lokalanästhesie, ihre wissenschaftliche Grundlagen und praktische Anwendung: ein Hand- und Lehrbuch*, J. A. Barth, 1914.

