

Retrospective Evaluation

Radiofrequency Neurolysis for Lumbar Pain Using a Variation of the Original Technique

Jorge F. Ramírez León, MD, José G. Rugeles Ortiz, MD, Enrique Osorio Fonseca, MD, Carolina Ramírez Martínez, MD, and Gabriel Oswaldo Alonso Cuéllar, DVM, MSc

From: Research Team from Centro de Columna, Bogotá, Colombia

Address Correspondence: Jorge Felipe Ramírez León Carrera 45 # 104-76 Bogotá, Colombia E-mail: jframirezl@yahoo.com

Disclaimer: The authors declare to have received external funding in the preparation of this research from Elliquence LLC. Conflict of interest: Dr. Ramirez, Dr. Ramirez and Dr. Rugeles are consultant for Elliquence. Dr. Osorio and Dr. Alonso report no conflicts.

Manuscript received: 09-02-2015 Accepted for publication: 10-14-2015

Free full manuscript: www.painphysicianjournal.com

Background: Zygapophysial joint arthrosis is a pathology related with axial lumbar pain. The most accepted treatment, after failure of medical management, is the thermal denervation of the medial branch. Nonetheless, the placement of the heat probe remains a challenge to surgeons, even when using the fluoroscope. Using a variation of Shealy's and Bogduk's original techniques, which includes ablation of the medial branch and the nerves present in the joint capsule, we hypothesize that we can obtain similar outcomes to those found in the literature.

Objective: To present the results attained over the last 8 years in the treatment of axial lumbar pain from zygapophysial joints degeneration, by employing a variation of the lumbar medial branch neurotomy technique, called 360-degree facet rhizotomy with radiofrequency.

Study Design: Retrospective evaluation.

Setting: Spine Center – Minimally Invasive Surgery in Bogotá, Colombia.

Methods: A medical chart review was conducted for patients diagnosed with axial lumbar pain from zygapophysial joint arthrosis and treated with 360-degree facet rhizolysis with a high frequency radiofrequency energy source between 2008 and 2014. Data were evaluated under modified MacNab and pre- and postoperative visual analog scale (VAS) criteria.

Results: We obtained a total of 73 patients. The average population age was 58.6 years. The preoperative VAS obtained was 7.3, which changed to 1.7 one year after the procedure. The MacNab criteria 12 months after the surgery gave satisfactory outcomes (excellent and good) from 91.7% of the patients.

Limitations: This retrospective study includes inherent limitations and only offers one year follow-up data.

Conclusions: Thermal therapy for zygapophysial joint arthrosis constitutes a safe and effective technique. The one year follow-up data presented here show that the ablation of the medial branch and nerves present in the joint capsule leads to satisfactory results in a high percentage of patients.

Key words: Zygapophysial joint, lumbar axial pain, high frequency radiofrequency, facet arthrosis, neurolysis, thermal therapy, facet joint thermocoagulation

Pain Physician 2016; 19:155-161

Aspects such as population explosion, increase in longevity, and unhealthy habits, among other events, have led to an increase in spine degenerative diseases (1). From this phenomenon, back pain became an important reason for consultation

with a physician in the adult population around the world (2,3) and one of the symptoms that generates higher costs to health care systems (4). Any traumatic, degenerative, or congenital change in any anatomical structures of the spine (disc, facets, foramen, vertebral

end plates, ligaments, muscles, etc.) can lead to an architecture imbalance and thereby to the presentation of chronic lumbar pain. The multifactorial nature of low back pain turns it into a major clinical challenge, making it difficult to attain the exact diagnosis and appropriate treatment (5). Specifically, the articular facets or zygapophysial joints (ZJs) are essential to the stability of the mobile segment of the spine and their primary function is to limit the range of motion of the spinal segment from horizontal forces and axial torsion. It is currently acknowledged that ZJs are a potential source of pain by being an area extensively covered by nociceptors, innervated by the brachial plexus of the dorsal branch (6), with free and encapsulated nerve terminations in the joint capsule (7), and nerves which can contain P-substance (8). Facet joint capsule degeneration, also known as "facet syndrome" or zygapophysial joint pain constitutes a pathology that presents itself mainly with an axial low back pain, and in advanced cases pain can radiate to the buttocks and legs. Its prevalence has been estimated between 25% and 45% (9) and is considered a factor that can contribute to lumbar pain in 15% to 25% of patients (10). Even though the reports of this pathology state that the single factor of lumbar pain does not exceed 4% (11), studies in cadavers showed facet arthrosis present in 100% of the specimens from people older than 60 years and concluded from their results that the probability to have facet arthrosis after 30 years of age could be 57% (12).

The notion of the joint facet as a source of lower back pain was first mentioned by Goldthwait in 1911 (13), but not until 1933 was the term "facet syndrome" used (14). The evolution of the medial branch neurolysis technique for facet arthrosis treatment started in 1971 when Rees (15) – by causing a lesion on the facet with a scalpel – obtained an improvement of 99.9% in lumbar pain. Then, with electrodes similar to those used in the treatment of trigeminal neuralgia, Shealy employed thermal energy in causing nerve ablation of the medial branch, thereby developing the "facet denervation" technique and reporting success rates of 79% (16) and 82% (17). Subsequent anatomical studies of Bogduk and Long (18,19) showed technical inaccuracies in Shealy's (16,17) description, and renamed the technique lumbar medial branch neurotomy. Both techniques, Shealy's description and Bogduk and Long's variation, have been amply described in the literature (20-22).

Nevertheless, despite the anatomical studies and fluoroscopy implementation, the surgeon still faces

the challenge of identifying the appropriate position for the probe over the nerve to apply heat on the exact point of the medial branch (23,24). Therefore, by employing the notions of nerve thermal ablation and collagen shrinking effect by radiofrequency, the authors proposed a change to the original technique that involves placing the probe first on the dorsal and lateral end of the superior articular process of the ZJ and then, with a circular movement apply heat upon a wider zone. This technique was named 360-degree facet rhizotomy. The technique also involves — aside from the medial branch neurotomy — the ablation of nerves present around the joint capsule resulting from neurogenesis due to joint degeneration, which are potential pain generators.

The purpose of this article is to present the results obtained, in one year of follow-up, in the treatment of axial lumbar pain from ZJ arthrosis by employing the 360-degree facet rhizotomy with radiofrequency (RF) technique.

METHODS

Participants

A retrospective study was conducted on the clinical charts of patients whose reason for consultation was axial lumbar pain from facet arthrosis and who were surgically intervened by employing 360-degree facet rhizolysis with RF. The inclusion criteria were medical charts of patients with more than 3 months of lumbar pain, with no response to medical treatment, including diagnostic facet blocks with less than a week of improvement, and clinical and imaging background for lumbar ZJ degeneration (Fig. 1). The study excluded medical charts of patients showing symptoms and imaging consistent with discopathy, radiculopathy, stenosis, spondylolisthesis, and previous surgery, and those medical charts without fully completed assessment criteria.

Procedure

The patient was placed in a prone position with legs flexed and abdominal support for spine alignment (Fig. 2). Between 5 and 10 mL of local anesthesia, 1% lidocaine, were applied and supplemented with light sedation. General anesthesia was not used in any case to be able to communicate with the patient throughout the procedure, making it safer and preventing nerve injury.

The RF Disc-FX® System (Elliquence LLC, NYC) was

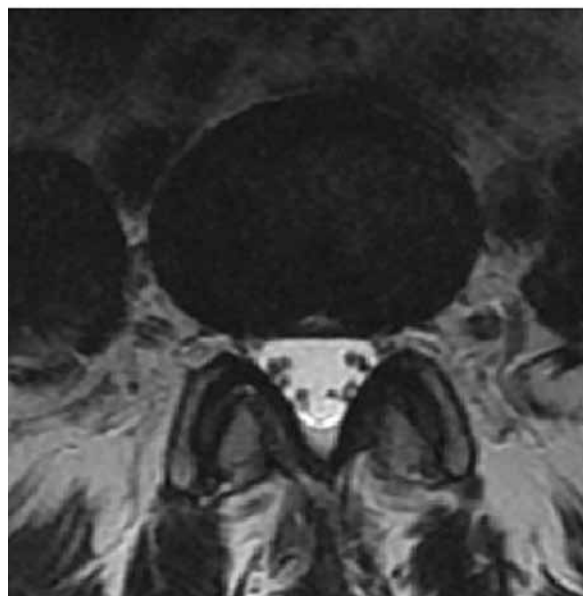


Fig. 1. Facet joint degeneration on level L4-L5.

used for the procedure. The point of entry was determined under fluoroscopic guidance, locating the lateral end zone of the pedicle of the affected level (Fig. 3). A 0.5 cm incision was made on the skin, through it, the dilator and the cannula of the system were advanced up to the superior articular process of the joint (Fig. 4).

Once the position of the cannula was assured, the dilator was removed and replaced with an RF electrode. The RF electrode tip was then located on top of the joint capsule, performing a capsulotomy. In order to achieve the ablation of the neurogenesis caused by the arthrosis and the collagen shrinkage of the capsule, 4 RF shots are performed in a circle (360 degrees) (Fig. 4). In that way, both the medial and lateral branch of the dorsal ramus were ablated (Fig. 5). All the procedures were performed bilaterally, left and right ZJ, but only over the levels showing osteoarthritis in imaging studies, which had been positive in the diagnostic blocks.

The same surgical team performed the technique under fluoroscopic view, employing the RF power generator Surgimax (Elliquence LLC, NYC) in default mode: bipolar hemo, at a standard 25 intensity for 6 seconds each shot.

Measures

Data were gathered from patients. Before the surgery patients were asked to rate their pain using a 0 to 10 scale (visual analog scale [VAS] score). Then,

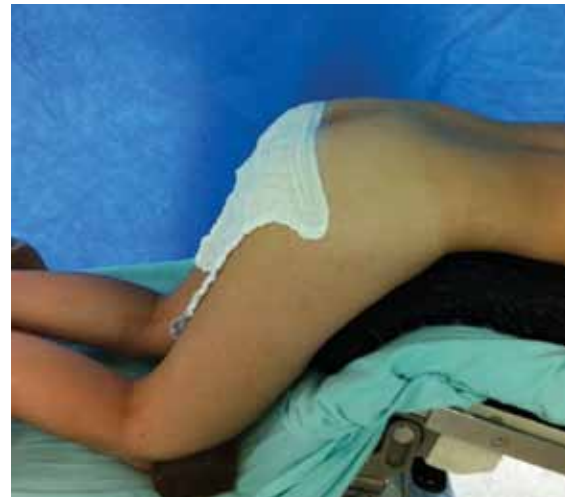

Fig. 2. Patient position for denervation using radiofrequency. Patient placed in prone position.

at 3 months and 12 months after of the procedure, patients were asked to establish 2 types of evaluation pain perception (VAS) and improvement evaluation (MacNab criteria). Success is based on an excellent and good outcome on the MacNab criteria (25). Medical chart collection and data gathering were conducted by a company independent from the researchers.

Statistical Analysis

Data analysis was performed with the statistical software R 3.1.1 for Windows 8. Demographic parameters and descriptive statistics of the variables were established.

RESULTS

From January 2008 to January 2014, 101 bilateral procedures were performed in 73 patients with lumbar pain. Gender distribution was 24 men (33%) and 49 women (67%). The average population age was 58.6 years (standard deviation [SD] = 11.14) in a 34.3 to 85.6 years range.

The average pre-operative VAS score was 7.3. Then, 3 months after the surgery, the average VAS score was 2.1, and last, 12 months after the surgery, we obtained a 1.7 average VAS score. By the modified MacNab criteria, the sample percentage with satisfactory results (excellent-good) was 87.5% at the 3-month follow-up, and 91.7% at the 12-month follow-up (Table 1).

There were no reports of infection, dural tear, vascular injury, or any other intraoperative or postop-

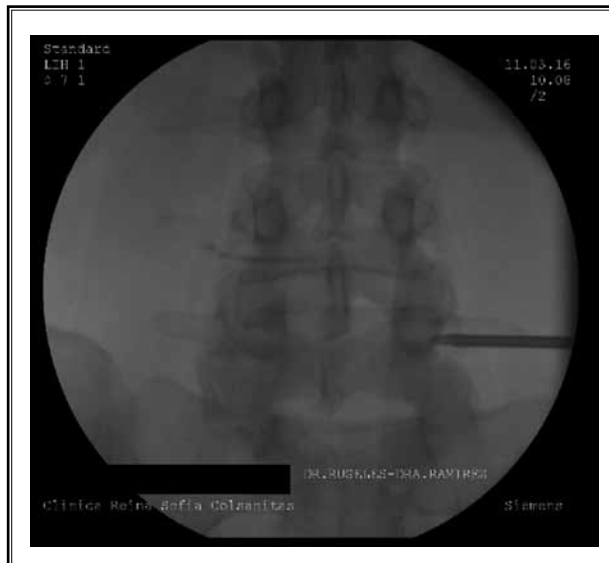


Fig. 3. Fluoroscopic view of the point of entry into the ZJ. Dilator and cannula placement on the lateral zone of the pedicle.

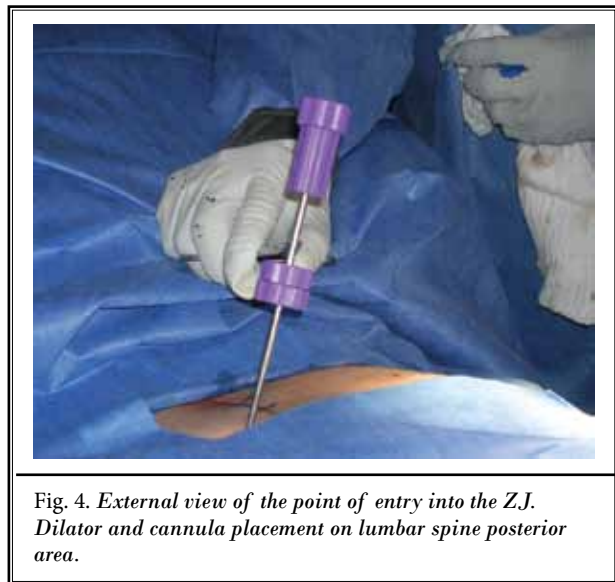

Fig. 4. External view of the point of entry into the ZJ. Dilator and cannula placement on lumbar spine posterior area.

erative complications. There was no reports of repeat surgery.

Discussion

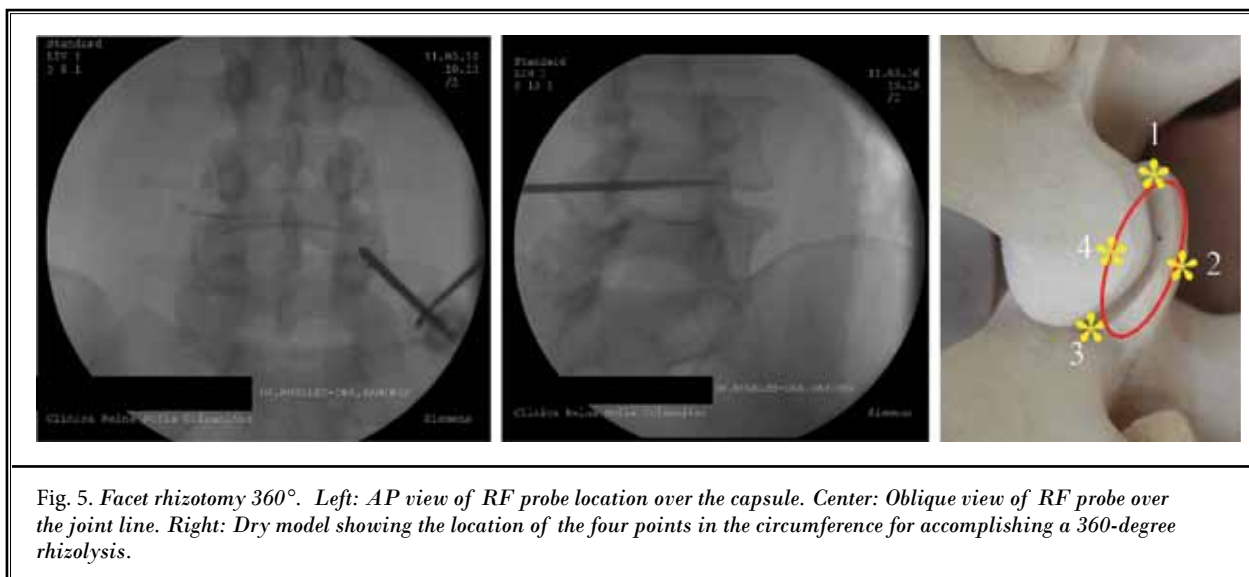
Facet syndrome, or ZJ pain, is a degenerative disease that affects the joint capsule and presents itself with axial lumbar pain. In advanced stages, it may cause nerve entrapment with radiating pain to the gluteal area and posterior area of the thigh above the knee, which worsens with extension (26). The potential of the ZJ as a unique source of lumbar pain has been demonstrated in several histological studies (6-8,27,28). The impact of this pathology on health care systems was evidenced in a study that evaluated the main causes of interventions for pain by Medicare and placed facet joint interventions as the second most common type of procedures performed in US pain management centers from 1998 to 2003 (29). Whereas the initial therapy for facetogenic pain corresponds to a non-specific treatment with analgesic drugs, anti-inflammatory drugs, physical support, and blocks (30), if satisfactory results are not obtained, the first surgical alternative must be the medial branch denervation with thermocoagulation (31,32).

The results obtained in this retrospective study showed an important improvement in lumbar pain perception of the patients treated with a variation of medial branch denervation, called 360 degrees facet

rhizotomy with radiofrequency (RF) technique, in one year of follow-up. The results obtained in this case series were comparable to other studies found in the literature using the original technique. Yilmaz et al (33) reported improvement — on a 100 scale — from 75.2 preoperative to 24.6, 12 months after the operation. Likewise, Proschek et al (34) obtained a reduction in VAS from preoperative 7.5 to postoperative 3.4 in 20 patients. Park et al (35) moved from 6.57 preoperative VAS to 1.48, 3 days later and 1.79, 3 months later. Now, regarding the percentage of patients that reported improvement after the procedure, Gofeld et al (21), mentioned a criterion similar to MacNab, and reported that 68.4% of the 119 patients treated with ZJ denervation with RF presented with pain relief that lasted between 6 and 24 months. Tzaan and Tasker (36) presented an experience of 118 procedures in 90 patients with 78% satisfactory results in an average follow-up of 5.6 months, similar to the results obtained by Martinez-Suarez et al (37) who reported an improvement of 74.7% in patients with a follow-up of 6 months. Recently, McCormick et al (38), in a long-term study with 62 patients, showed a function and pain improvement > 50%.

Among the reports more similar to this study, we should note the results of Civelek et al (39) with 90% improvement 12 months after the procedure, and Tomé-Bermejo et al (40) who obtained 89% improvement maintained for 6 months in 66% of patients.

The effectiveness of the medial branch ablation was proven with RCTs. The results of a randomized double-blind trial by van Kleef et al (31) showed in 31 patients



a 67% success rate (10/15) in the patients treated using RF versus 38% (6/16) relief in the control group (with a sham treatment), and displaying statistically significant differences between the 2 groups in Oswestry and VAS criteria. Comparable results, using similar experimental designs, were presented subsequently by van Wijk et al (32) and Nath et al (41). Both studies showed a statistically significant reduction in the pain scale values reported by the patients before and after surgery.

With respect to complications, most studies – as well as this series – did not report adverse effects related with the surgical procedure (33,35,37,39-42). Some studies reported complications, Kornick et al (43) showed a complication rate of 7% (6/92) in a 5-year retrospective study and Roy et al (44) reported that localized pain and numbness occurred after the surgery in 6 out of 34 patients (18%). In both studies the complications were treated medically and resolved to satisfaction.

Minimally invasive techniques have proven their effectiveness and safety in the relief of lumbar pain caused by different pathologies (45-50), including ZJ pain or facet syndrome (20,28,31,32,41). Despite the different results and arguments found in the literature (26,30), medial branch neurotomy using RF is currently the best option for the treatment of pain of facet joint origin (9). Similarly, the results obtained in this case series determine that the variation in the technique at-

Table 1. Results of the modified MacNab criteria at the 3- and 12-month follow-ups.

	3 mo		12 mo	
Excellent	67.1%	49	83.6%	61
Good	20.5%	15	8.2%	6
Fair	8.2%	6	8.2%	6
Poor	4.1%	3	0.0%	0
Improvement (E + G)	87.7%	64	91.8%	67

tains similar or superior results to those reported in the literature for the conventional technique. In addition, considering that no complication occurred, 360-degree facet rhizolysis may be established as a safe procedure. Last, it must be mentioned that the success of the technique and its safety margin depend on an excellent and exact diagnosis, a specific indication, and the appropriate performance of the technique.

Conflict of Interest

The authors declare to have received financial support in this research from Elliquence LLC.

REFERENCES

- Szpalski M, Gunzburg R, Melot C, Aebi M. The aging of the population: A growing concern for spine care in the twenty-first century. In: Aebi M, Gunzburg R, Szpalski M (eds). *The Aging Spine*. Springer, Berlin, 2003, pp 1-8.
- Hoy D, Bain C, Williams G, March L, Brooks P, Blyth F, Woolf A, Vos T, Buchbinder R. A systematic review of the global prevalence of low back pain. *Arthritis Rheum* 2012; 64:2028-2037.
- Manchikanti L, Singh V, Falco FJE, Benyamin RM, Hirsch JA. Epidemiology of low back pain in adults. *Neuromodulation* 2014; 17:3-10.
- Martin B, Deyo RA, Mirza SK, Turner JA, Comstock BA, Hollingworth W, Sullivan SD. Expenditures and health status among adults with back and neck problems. *JAMA* 2008; 299:656-664.
- Deyo RA, Weinstein JN. Low back pain. *N Engl J Med* 2001; 344:363-370.
- Masini M, Paiva WS, Araujo AS, Jr. Anatomical description of the facet joint innervation and its implication in the treatment of recurrent back pain. *J Neurosurg Sci* 2005; 49:143-146.
- Bogduk N, Wilson AS, Tynan W. The human lumbar dorsal rami. *J Anat* 1982; 134:383-397.
- Ohtori S, Takahashi K, Chiba T, Yamagata M, Sameda H, Moriya H. Substance P and calcitonin gene-related peptide immunoreactive sensory DRG neurons innervating the lumbar facet joints in rats. *Auton Neurosci* 2000; 86:13-17.
- Falco FJ, Manchikanti L, Datta S, Sehgal N, Geffert S, Onyewu O, Zhu J, Coubarous S, Hameed M, Ward SP, Sharma M, Hameed H, Singh V, Boswell MV. An update of the effectiveness of therapeutic lumbar facet joint interventions. *Pain Physician* 2012; 15:E909-E953.
- Binder DS, Nampiaparampil DE. The provocative lumbar facet joint. *Curr Rev Musculoskelet Med* 2009; 2:15-24.
- Schwarzer AC, Aprill C, Derby R, Fortin JD, Kine G, Bogduk N. Clinical features of patients with pain stemming from the lumbar zygapophysial joints. Is the lumbar facet syndrome a clinical entity? *Spine* 1994; 19:1132-1137.
- Eubanks JD, Lee MJ, Cassinelli E, Ahn NU. Prevalence of lumbar facet arthrosis and its relationship to age, sex, and race: An anatomic study of cadaveric specimens. *Spine* 2007; 32:2058-2062.
- Goldthwait JE. The lumbosacral articulation: An explanation of many cases of lumbago, sciatica, and paraplegia. *Boston Med and Surg J* 1911; 164:365-372.
- Ghormley RK. Low back pain with special reference to the articular facets, with presentation of an operative procedure. *JAMA* 1933; 101:773.
- Rees WES. Multiple bilateral subcutaneous rhizolysis of segmental nerves in the treatment of the intervertebral disc syndrome. *Ann Gen Pract* 1971; 16:126-127.
- Shealy CN. Facet denervation in the management of back and sciatic pain. *Clin Orthop Relat Res* 1976; 115:157-164.
- Shealy CN. Percutaneous radiofrequency denervation of spinal facets. Treatment for chronic back pain and sciatica. *J Neurosurg* 1975; 43:448-451.
- Bogduk N, Long DM. The anatomy of the so-called 'articular nerves' and their relationship to facet denervation in the treatment of low back pain. *J Neurosurg* 1979; 51:172-177.
- Bogduk N, Long DM. Percutaneous lumbar medial branch neurotomy. A modification of facet denervation. *Spine* 1980; 5:193-200.
- Bogduk N. Evidence-informed management of chronic low back pain with facet injections and radiofrequency neurotomy. *Spine J* 2008; 8:56-64.
- Gofeld M, Jitendra J, Faclier G. Radiofrequency denervation of the lumbar zygapophysial joints: 10-year prospective clinical audit. *Pain Physician* 2007; 10:291-300.
- Varlotta GP, Lefkowitz TR, Schweitzer M, Errico TJ, Spivak J, Bendo JA, Rybak L. The lumbar facet joint: A review of current knowledge: Part II: diagnosis and management. *Skeletal Radiol* 2011; 40:149-157.
- Bogduk N, Macintosh J, Marsland A. Technical limitations to the efficacy of radiofrequency neurotomy for spinal pain. *Neurosurgery* 1987; 20:529-535.
- Kanchiku T, Imajo Y, Suzuki H, Yoshida Y, Nishida N, Taguchi T. Percutaneous radiofrequency facet joint denervation with monitoring of compound muscle action potential of the multifidus muscle group for treating chronic low back pain: A preliminary report. *J Spinal Disord Tech* 2014; 27:E262-E267.
- MacNab I. Negative disc exploration. An analysis of the causes of nerve-root involvement in sixty-eight patients. *J Bone Joint Surg Am* 1971; 53:891-903.
- Poetscher AW, Gentil AF, Lenza M, Ferretti M. Radiofrequency denervation for facet joint low back pain: A systematic review. *Spine* 2014; 39:E842-E849.
- Eisenstein SM, Parry CR. The lumbar facet arthrosis syndrome. Clinical presentation and articular surface changes. *J Bone Joint Surg Br* 1987; 69:3-7.
- Elder BD, Vigneswaran K, Athanasiou KA, Kim DH. Biomechanical, biochemical, and histological characterization of canine lumbar facet joint cartilage. *J Neurosurg Spine* 2009; 10:623-628.
- Manchikanti L. The growth of interventional pain management in the new millennium: A critical analysis of utilization in the medicare population. *Pain Physician* 2004; 7:465-482.
- Cohen SP, Raja SN. Pathogenesis, diagnosis, and treatment of lumbar zygapophysial (facet) joint pain. *Anesthesiology* 2007; 106:591-614.
- van Kleef M, Barendse GA, Kessels A, Voets HM, Weber WE, de Lange S. Randomized trial of radiofrequency lumbar facet denervation for chronic low back pain. *Spine* 1999; 24:1937-1942.
- van Wijk RM, Geurts JW, Wynne HJ, Hammink E, Buskens E, Lousberg R, Knape JT, Groen GJ. Radiofrequency denervation of lumbar facet joints in the treatment of chronic low back pain: A randomized, double-blind, sham lesion-controlled trial. *Clin J Pain* 2005; 21:335-344.
- Yilmaz C, Kabatas S, Cansever T, Gulsen S, Coven I, Caner H, Altinors N. Radiofrequency facet joint neurotomy in treatment of facet syndrome. *J Spinal Disord Tech* 2010; 23:480-485.
- Proschek D, Kafchitsas K, Rauschmann M, Kurth A, Vogl T, Geiger F. Reduction of radiation dose during radiofrequency denervation of the lumbar facet joints using the new targeting system SabreSource: A prospective study in 20 patients. *Arch Orthop Trauma Surg* 2010; 130:1103-1110.
- Park SJ, Ji C, Kwon JY, Ha KY. The effect of radiofrequency neurotomy on chronic low back pain. *Asian Spine J* 2007; 1:88-90.
- Tzaan WC, Tasker RR. Percutaneous radiofrequency facet rhizotomy experience with 118 procedures and reappraisal of its value. *Can J Neurol Sci* 2000; 27:125-130.
- Martinez-Suarez JE, Cambolor L, Salva S, De Jongh WA. Termocoagulación facetaria lumbar. Experiencia en 252 pacientes. *Revista de la Sociedad Española del Dolor* 2005; 12:425-428.
- McCormick ZL, Marshall B, Walker J,

- McCarthy R, Walega DR. Long-term function, pain and medication use outcomes of radiofrequency ablation for lumbar facet syndrome. *Int J Anesth* 2015; 2:028.
39. Civelek E, Cansever T, Kabatas S, Kircelli A, Yilmaz C, Musluman M, Ofluoglu D, Caner H. Comparison of effectiveness of facet joint injection and radiofrequency denervation in chronic low back pain. *Turk Neurosurg* 2012; 22:200-206.
40. Tomé-Bermejo F, Barriga-Martín A, Martín JLR. Identifying patients with chronic low back pain likely to benefit from lumbar facet radiofrequency denervation: A prospective study. *J Spinal Disord Tech* 2011; 24:69-75.
41. Nath S, Nath CA, Pettersson K. Percutaneous lumbar zygapophysial (facet) joint neurotomy using radiofrequency current, in the management of chronic low back pain. A randomized double-blind trial. *Spine* 2008; 33:1291-1297.
42. Mikeladze G, Espinal R, Finnegan R, Routon J, Martin D. Pulsed radiofrequency application in treatment of chronic zygapophyseal joint pain. *Spine J* 2003; 3:360-362.
43. Kornick C, Kramarich SS, Lamer TJ, Todd Sitzman B. Complications of lumbar facet radiofrequency denervation. *Spine* 2004; 29:1352-1354.
44. Roy C, Chatterjee N, Ganguly S, Sen-gupta R. Efficacy of combined treatment with medial branch radiofrequency neurotomy and steroid block in lumbar facet joint arthropathy. *J Vasc Interv Radiol* 2012; 23:1659-1664.
45. Ruetten S, Komp M, Merk H, Godolias G. Recurrent lumbar disc herniation after conventional discectomy: A prospective, randomized study comparing full-endoscopic interlaminar and transforaminal versus microsurgical revision. *J Spinal Disord Tech* 2009; 22:122-129.
46. Dasenbrock HH, Juraschek SP, Schultz LR, Witham TF, Sciubba DM, Wolinsky JP, Gokaslan ZL, Bydon A. The efficacy of minimally invasive discectomy compared with open discectomy: A meta-analysis of prospective randomized controlled trials. *J Neurosurg Spine* 2012; 16:452-462.
47. Rasouli MR, Rahimi-Movaghar V, Shokraneh F, Moradi-Lakeh M, Chou R. Minimally invasive discectomy versus microdiscectomy/open discectomy for symptomatic lumbar disc herniation. *Cochrane Database Syst Rev* 2014; 9:CD010328.
48. Ahn Y, Lee SH. Outcome predictors of percutaneous endoscopic lumbar discectomy and thermal annuloplasty for discogenic low back pain. *Acta Neurochir (Wien)* 2010; 152:1695-1702.
49. Yeung AT, Tsou PM. Posterolateral endoscopic excision for lumbar disc herniation: Surgical technique, outcome and complications in 307 consecutive cases. *Spine* 2002; 27:722-731.
50. Hoogland T, van den Brekel-Dijkstra K, Schubert M, Miklitz B. Endoscopic transforaminal discectomy for recurrent lumbar disc herniation: A prospective, cohort evaluation of 262 consecutive cases. *Spine* 2008; 33:973-978.

