

Observational Study

## Percutaneous Vertebroplasty Combined with Percutaneous Pediculoplasty for Lytic Vertebral Body and Pedicle Lesions of Metastatic Tumors

Zhen-Yong Ke, MD, Yang Wang, PhD, Yue-Long Zhong, MD, Liang Chen, PhD, and Zhong-Liang Deng, MD, PhD

From: Department of Orthopaedics, Second Affiliated Hospital of Chongqing Medical University, China.

Address Correspondence: Zhong-Liang Deng, MD, PhD  
76 Lin Jiang Road  
Yu Zhong District  
Chong Qing  
China Chong Qing, China  
E-mail:  
zhongliang.deng@yahoo.com

Disclaimer: There was no external funding in the preparation of this manuscript. Conflict of interest: Each author certifies that he or she, or a member of his or her immediate family, has no commercial association (i.e., consultancies, stock ownership, equity interest, patent/licensing arrangements, etc.) that might pose a conflict of interest in connection with the submitted manuscript.

Manuscript received: 09-14-2014  
Revised manuscript received: 01-17-2015  
Accepted for publication: 02-26-2015

Free full manuscript:  
www.painphysicianjournal.com

**Background:** Percutaneous pediculoplasty (PP) consists of the injection of Poly(methyl methacrylate) (PMMA) into the fractured pedicle or lytic vertebral pedicle lesions, as a technique derived from vertebroplasty.

**Objectives:** To evaluate the short-term analgesic effect of percutaneous vertebroplasty (PV) and percutaneous pediculoplasty (PP) in patients with lytic vertebral body and pedicle lesions of metastatic tumors.

**Study Design:** Single-center retrospective observational study.

**Setting:** An interventional pain management practice, a medical center, major metropolitan city, China.

**Methods:** Single-center retrospective observational study of all patients managed with PV and PP for painful vertebral body and pedicle metastatic tumors between 2007 and 2013. For each patient, symptom duration and pain intensity were recorded. PP was performed under local analgesia, in the prone position, with C-arm fluoroscopy guidance. The mixture of PMMA and Doxorubicin was delivered into the vertebral body with a non-beveled needle for the initial treatment followed by the mixture delivery into the lytic pedicle during needle withdrawal.

**Results:** Nine patients (5 women, 4 men) were enrolled in the study with a mean age of 65.9 years (range 57 – 75). Technical success was defined as the ability to access the lesion using the approach. A positive clinical response for pain relief was achieved in these patients in whom vertebroplasty and pediculoplasty had been performed. Pain level was not significantly reduced in 3 patients in whom just vertebroplasty has been performed because the medial wall of the pedicle was destroyed by the metastatic lesion.

**Limitations:** This study is limited by its sample size.

**Conclusions:** PV and PP via the transpedicular approach for infiltrated vertebral bodies and infiltrated pedicles of metastatic tumors may be considered a valid therapeutic option.

**Key words:** Percutaneous pediculoplasty, percutaneous vertebroplasty, lytic pedicular lesions, bone cement

**Pain Physician 2015; 18:E347-E353**

**P**ercutaneous vertebroplasty (PV) was initially introduced in France in 1984 by the interventional neuroradiologist Herve Deramond (1), and has been widely used to treat pain related to benign spine disease, osteoporotic compression fractures,

as well as malignant lesions such as metastases. It most importantly leads to immediate pain relief (2-4). Percutaneous pediculoplasty (PP) consists of the injection of Poly(methyl methacrylate) (PMMA) into the fractured pedicle or lytic vertebral pedicle lesions,

as a technique derived from vertebroplasty. The first PP was reported by Gailloud et al (5) in 2002 for the treatment of lytic pedicular lesions, a plasmocytoma, and a vertebral hemangioma, and subsequent reports have documented its safety and efficacy.

The primary objective of this study was to evaluate the analgesic effect of the PV and PP based on changes in a visual analog scale (VAS) pain score before and after the procedure. The second purpose of this study was to verify the effect and feasibility of the PP technique in the treatment of painful pedicular metastatic tumors.

## METHODS

A prospective observational cohort study was conducted of the patients presenting with lytic vertebral body and pedicle lesions of metastatic tumors. These patients underwent the procedure between 2007 and 2013. The indication for treatment was established on the basis of a detailed correlation between clinical history, particular current symptoms, and computed tomography (CT) or magnetic resonance imaging (MRI) findings, after evaluating the various treatment options and possible contraindications.

Patients had to meet the following 3 inclusion criteria: (1) vertebral body and pedicular metastases were confirmed by radionuclide bone scanning, MRI, or CT; (2) a pain intensity score > 5 on VAS; (3) pain totally or partially refractory to analgesic treatment in patients with a life expectancy > 3 months; and (4) the medial wall of the pedicle was not completely destroyed by the metastatic lesion.

Informed consent was obtained from the patients after detailed discussion of the procedure's related risks and benefits. The patient was placed on the angiography table in the prone position. Local anesthetic with lidocaine, 1% or 2%, was used to infiltrate the subcutaneous tissue and the periosteum of the targeted pedicle at the intended needle entry site.

After local anesthesia, an 11-gauge non-beveled needle was advanced into the pedicle of the targeted vertebral body under antero-posterior (AP) view and lateral views.

The needle was introduced with a transpedicular oblique approach to reach the junction of the anterior and middle thirds of the vertebra at the midline with use of AP fluoroscopic image guidance. Care was taken to keep the needle away from the inside margin of the pedicle to avoid breaching the central canal. After several bone samples had been taken from the targeted vertebral body with an 18-gauge biopsy needle, then,

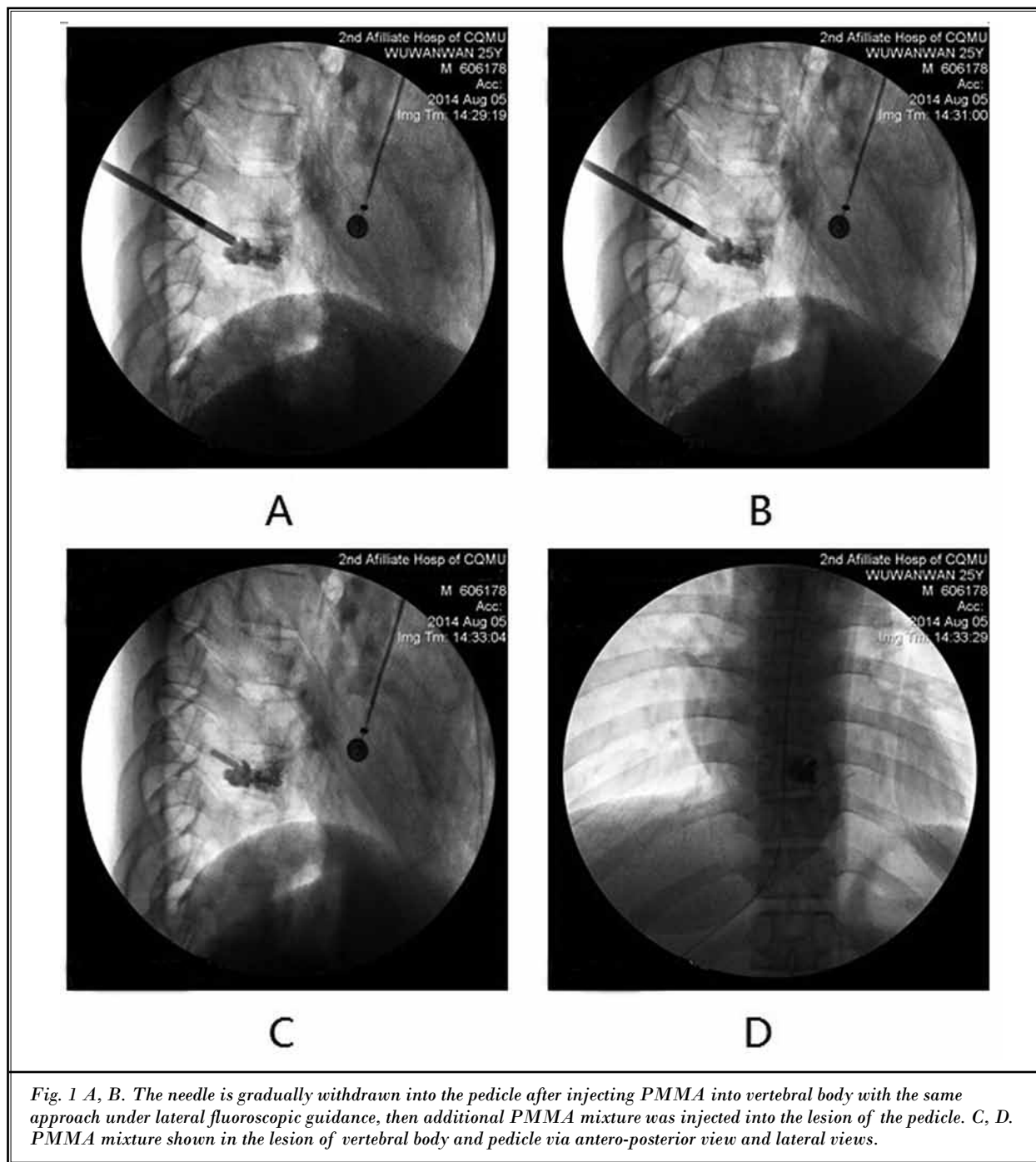
to increase the anti-tumor effect, PMMA powder was mixed with Doxorubicin powder, and liquid methyl-methacrylate monomer added until a toothpaste-like consistency was obtained. Under alternative AP and lateral fluoroscopic guidance, approximately 6 mL of the mixture was injected from the transpedicular oblique approach, and then the needle was gradually withdrawn into the pedicle. An additional 1 – 1.5 mL of PMMA mixture was injected into the lesion of the pedicle (Fig. 1). If the lesions involved bilateral pedicles, the procedure was completed through bilateral pedicle puncture.

For each patient, we collected patient gender and age. Meanwhile, pain level (pain intensity on a 10-point VAS) was recorded at 24 hours before the procedure and post-procedure follow-up intervals at 30 minutes, 24 hours, and one week. The preoperative VAS score was determined with the patient resting in bed before and after the procedure.

## RESULTS

Nine patients (5 women, 4 men) were enrolled in the study with a mean age of 65.9 years (Table 1). Technical success was defined as the ability to access the lesion using the approach established at previous x-rays and CT scans. Technical success was achieved in all cases (Fig.2). This approach allowed us to move bone trochar into the targeted vertebral and pedicle lesions easily. No asymptomatic foraminal leak in these patients were observed.

A positive clinical response for pain relief was achieved in these patients in whom vertebroplasty and pediculoplasty had been performed. Among these patients with pain relief, the mean VAS score at baseline was  $7.50 \pm 1.04$  and  $1.50 \pm 1.04$  within 30 minutes after the procedure,  $1.83 \pm 0.75$  at 24 hours, and  $2.16 \pm 0.75$  at one week (Table 2). Improvements at each follow-up interval and overall were statistically significant. Meanwhile, pain level was not significant reduced in 3 patients in whom just vertebroplasty has been performed because the medial wall of the pedicle was destroyed by the metastatic lesion. Pain level decreased by one point in 2 patients and by 3 points in one patient. Among these patients with no remarkable pain relief, the mean VAS score at baseline was  $8.00 \pm 1.00$  and  $6.33 \pm 0.57$  within 30 minutes after the procedure,  $5.00 \pm 1.00$  at 24 hours, and  $5.66 \pm 1.15$  at one week. The overall procedure was well tolerated by the patients. No catastrophic complications were encountered during the follow-up intervals.



*Fig. 1 A, B. The needle is gradually withdrawn into the pedicle after injecting PMMA into vertebral body with the same approach under lateral fluoroscopic guidance, then additional PMMA mixture was injected into the lesion of the pedicle. C, D. PMMA mixture shown in the lesion of vertebral body and pedicle via antero-posterior view and lateral views.*

## Discussion

PP was first described by Gailloud et al to treat a lytic L5 vertebral body/pedicle lesion (5). Pediculoplasty was derived from vertebroplasty on the basis of the same pathologic mechanism, and has been de-

scribed as an adjuvant to vertebroplasty rather than a dedicated primary treatment. This percutaneous cementoplasty method was initially used to treat lesions of the vertebral pedicle. Only a few cases of

Table 1. Clinical data.

Patient no.	Age	Gender	Vertebral Level	Pedicle Lesions	Augmentation range	Preprocedure (VAS)	30 min. (VAS)	24 hours (VAS)	1 week (VAS)
1	67	F	L1 + L3	Left Pedicle (L3)	L1+L3+Left Pedicle(L3)	8	2	3	3
2	76	M	L3 + L4	Left Pedicle (L4)	L3 + L4 + Left Pedicle	7	1	1	2
3	77	F	T11 + T12	Left Pedicle (T11)	T11 + T12	8	7	6	7
4	59	F	T11 + L2 + L3	Bilateral (L2)	T11 + L2 + L3	9	6	4	5
5	64	M	T12 + L1	Bilateral (L1)	T12 + L1 + Bilateral (L1)	7	1	2	1
6	84	M	L4	Right Pedicle (L4)	L2 + Right Pedicle (L4)	8	2	2	2
7	81	M	T11 + T12 + L1	Left Pedicle (T11/T12)	T11 + T12 + L1	7	6	5	5
8	71	M	T10	Right Pedicle (T10)	T10 + Right Pedicle	9	3	2	3
9	82	F	T9	Right Pedicle (T9)	T9 + Right Pedicle	6	0	1	2

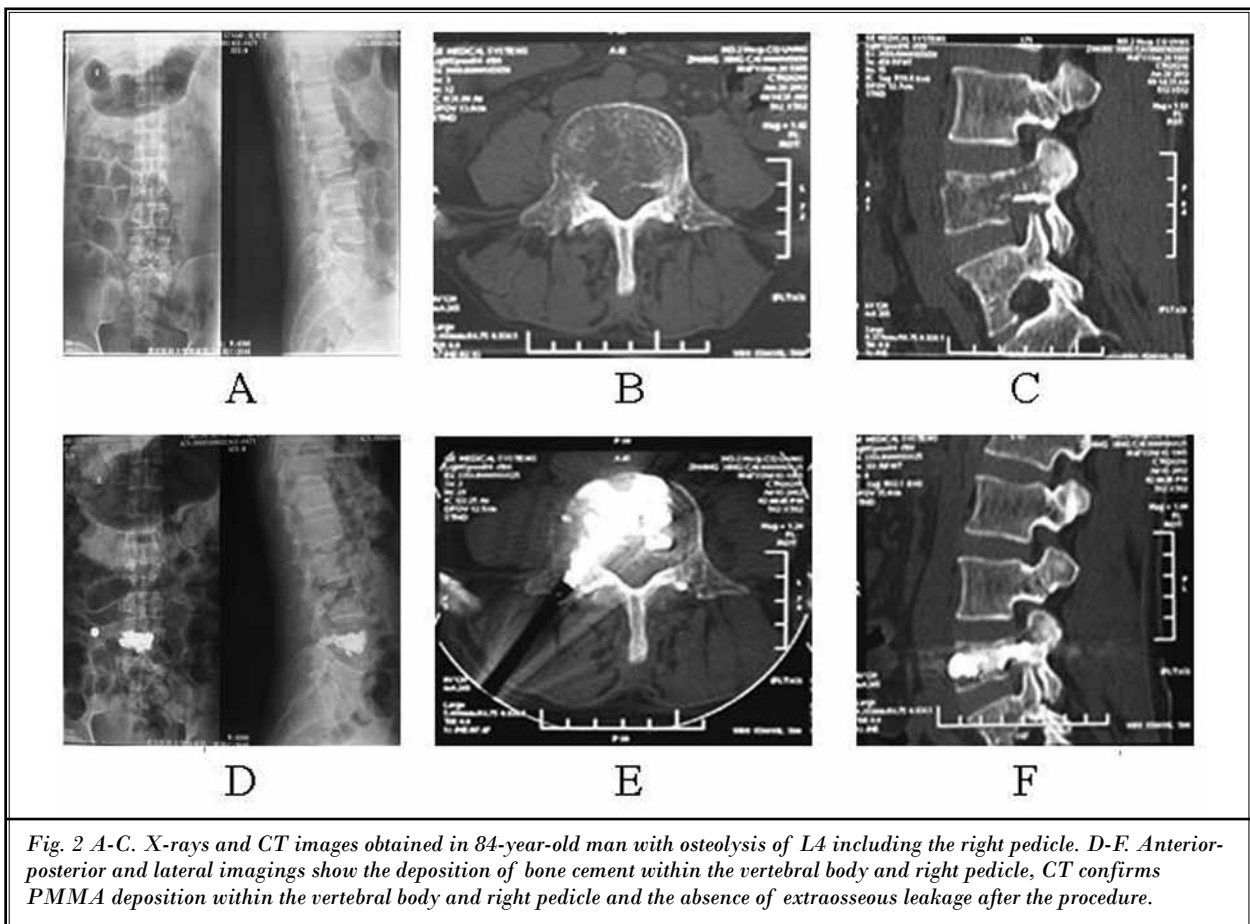


Fig. 2 A-C. X-rays and CT images obtained in 84-year-old man with osteolysis of L4 including the right pedicle. D-F. Anterior-posterior and lateral imagings show the deposition of bone cement within the vertebral body and right pedicle, CT confirms PMMA deposition within the vertebral body and right pedicle and the absence of extraosseous leakage after the procedure.

Table 2. *Visual Analogue Scale scores (PP or/and PVP).*

	Patient no.	Age	Preprocedure	30 minute post	24-hour post	one week post
PVP	3, 4, 7	72.33 ± 11.71	8.00 ± 1.00	6.33 ± 0.57	5.00 ± 1.00	5.66 ± 1.15
PVP+PP	1, 2, 5, 6, 8, 9	74.00 ± 8.07	7.50 ± 1.04	1.50 ± 1.04	1.83 ± 0.75	2.16 ± 0.75

pediculoplasty for lesions of the vertebral pedicle have been published up until now in the English literature (5-10). PP and PV have been shown to be efficacious in the immediate relief of pain associated with various spine conditions, including osteoporotic vertebral and pedicular compression fractures (8), vertebral hemangioma involving the neural arch (9), traumatic pedicle fracture (6), and lytic lesions involving both the pedicle and vertebral body (5,7). Singh et al (6) reported one case about performing fluoroscopically guided PP in the setting of traumatic or non-neoplastic pedicle fractures. For the treatment of lytic vertebral pedicle lesions of metastatic tumors, 51 pedicles were treated in 32 consecutive patients (7). Clinically effective pain relief was obtained in these cases. Eyheremendy et al (8) described 5 cases of osteoporotic vertebral and pedicular compression fractures that were treated with PV and bilateral pediculoplasty. Complete pain relief was reported by these patients. Fuwa et al (9) reported a case of symptomatic hemangioma which was mainly located in the neural arch, which was successfully treated with PP using polymethylmethacrylate. To our knowledge, the relative contraindications of PV and PP for lytic vertebral body and pedicle lesions of metastatic tumors are defined as follows: (1) neurologic symptoms in the treated vertebral segment, (2) partial/complete loss of the posterior edge in the treated malignant fractures, (3) tumor extension to the spinal canal, and (4) the medial wall of the pedicle was destroyed by the metastatic lesion.

PP is performed with different imaging methods and approaches. There are a lot of technical difficulties for PP, including the immediate proximity of neural structures (the spinal cord, nerve roots), the small volume of the pedicle itself, and the difficulty in fluoroscopic visualization of relatively small-volume cement deposition. In these cases, the authors showed the different ways to avoid the cement leakage.

There are 2 main access routes for performing vertebroplasty: the transpedicular route (bipedicular or unipedicular) (9,10), and the direct lateral route (6). Martin et al (7) used an alternative access route to per-

form PV of vertebral bodies with pedicle lysis by placing the vertebroplasty needle via the diseased pedicle into the vertebral body. This route makes it possible to treat infiltrated vertebral bodies and infiltrated pedicles with percutaneous injection of PMMA cement. Similar to Martin et al, in many cases, PMMA was delivered into the vertebral body for the initial treatment of the vertebral body, then cement was delivered into the pedicle during needle withdrawal, rather than actively injecting the pedicle directly.

Singh et al (6) chose a uni-pedicular approach, despite the bilateral pedicle fractures in their case, to preserve pedicle access for possible future neurosurgical spine stabilization in the event of pediculoplasty failure, and the difficulty in actively visualizing PMMA deposition in the lateral plane after cement delivery to the contralateral pedicle. Eyheremendy et al (8) reported the bilateral pediculoplasty with use of polymethylmethacrylate for treatment of pedicular compression fractures. Gailloud et al (5) showed that for lesions involving both the pedicle and the vertebral body, a double-needle unipedicular technique is advocated.

Martin et al (7) showed that the bevel of the needle should point medially to avoid penetration of the spinal canal when passing through the pedicle, and after treatment of the vertebral body, the needle is withdrawn gently into the pedicle, then pediculoplasty is performed with the bevel pointing laterally to avoid cement delivery into the spinal canal. Unlike other pediculoplasty cases reporting the use of beveled needles, Singh et al (6) used a 10.5 G non-beveled externally threaded needle instead of a standard 11 G or 13 G beveled vertebroplasty needle and a lower pressure injection to deliver a very small controlled volume into this small volume osseous structure. In all of these cases, a relatively thick consistency PMMA for pediculoplasty was used to further ensure a slow controlled cement delivery.

In recent years, pediculoplasty has been used to treat vertebral hemangioma involving the neural arch and osteoporotic and traumatic pedicle fracture, but

literature on the use of percutaneous stabilization in pedicle lesions in such patients is still lacking. Our study suggested that the patients (PV and PP) experienced almost immediate and dramatic pain relief after osteoplasty for the duration of follow-up. The patients got early and rapid pain reduction after the operation, and this outcome is comparable to the results presented in the Martin et al study. These patients' pain (PV, not PP) was reduced but not was significant because of the patients with lytic pedicle lesions. The other treatment should be considered in these patients whose medial wall of the pedicle was destroyed by the metastatic lesion. The conventional treatment modalities presently available for spinal metastases are chemotherapy, radiation therapy (RT), and surgery. Antitumor chemotherapy currently plays a relatively limited role in the treatment of spinal metastases. More recent radiation studies confirmed the utility of this modality for the treatment for spinal metastases (11-13). According to the tissues to be resected, operative methods for spinal decompression are classified into palliative surgery, intratumoral curettage, and En bloc surgery (14). The most suitable method is selected upon consideration of anatomical location, compression of neural tissue, necessity of spinal stabilization, general condition, and so on. Meanwhile, radiofrequency ablation, spinal endoscopy, and other modern forms of minimally invasive surgery will have more applications in the treatment of spinal metastatic tumors. Radiofrequency heat ablation has proven to be an effective method for the

treatment of malignant and benign tumors, including spinal lesions (15-18). Another less invasive option for the treatment of metastatic spine disease is minimally invasive surgery, including endoscopic video-assisted thoracoscopic surgery (VATS) and mini-open minimal access spine surgery (MASS) (19-20).

In the present study, we used a transpedicular oblique approach with a non-beveled needle to perform PV of vertebral bodies with pedicle lysis, placed the vertebroplasty needle via the diseased pedicle into the vertebral body (reach the junction of the anterior and middle thirds of the vertebra at the midline). This approach makes it possible to treat infiltrated vertebral bodies and infiltrated pedicles easily, through withdrawal of the needles into the pedicle after vertebroplasty of vertebral bodies. Meanwhile, the cement leakage did not occur in our patients because we choose patients whose medial wall of the pedicle was not completely destroyed by the metastatic lesion.

## CONCLUSION

In conclusion, due to the technical feasibility, the low complication rate, and the immediate relief of symptoms, PV and PP via the transpedicular approach for infiltrated vertebral bodies and infiltrated pedicles of metastatic tumors may be considered a valid therapeutic option. However, more patients and longer follow-up are necessary to confirm our experience, and more further study is still necessary to evaluate the primary mechanical outcomes of PMMA treatment of vertebral body and pedicle metastasis.

## REFERENCES

- Galibert P, Dermond H, Rosat P, Le Gars D. Preliminary note on the treatment of vertebral angioma by percutaneous acrylic vertebroplasty [in French]. *Neurochirurgie* 1987; 33:166-168.
- Belkoff SM, Mathis JM, Jasper LE, Deramond H. The biomechanics of vertebroplasty. The effect of cement volume on mechanical behavior. *Spine* 2001; 26:1537-1541.
- Liebschner MA, Rosenberg WS, Keaveny TM. Effects of bone cement volume and distribution on vertebral stiffness after vertebroplasty. *Spine* 2001; 26:1547-1554.
- Serra L, Mehrabi Kermani F, Panagiotopoulos K, De Rosa V, Vizioli L. Vertebroplasty in the treatment of osteoporotic vertebral fractures: Results and functional outcome in a series of 175 consecutive patients. *Minim Invasive Neurosurg* 2007; 50:12-17.
- Gailloud P, Beauchamp N, Martin JB, Murphy KJ. Percutaneous pediculoplasty: Polymethylmethacrylate injection into lytic vertebral pedicle lesions. *J Vasc Interv Radiol* 2002; 13:517-521.
- Singh J, Baker MD, Morris PP, Whitlow CT. Percutaneous pediculoplasty for traumatic pedicle fracture. A technical case report. *Interv Neuroradiol*. 2012; 18:221-226.
- Martin JB, Wetzel SG, Seium Y, Dietrich PY, Somon T, Gailloud P, Payer M, Kelekis A, Ruefenacht DA. Percutaneous vertebroplasty in metastatic disease: Transpedicular access and treatment of lysed-pedicles – initial experience. *Radiology* 2003; 229:593-597.
- Eyheremendy EP, De Luca SE, Sanabria E. Percutaneous pediculoplasty in osteoporotic compression fractures. *J Vasc Interv Radiol* 2004; 15:869-874.
- Fuwa S, Numaguchi Y, Kobayashi N, Saida Y. Percutaneous pediculoplasty for vertebral hemangioma involving the neural arch: A case report. *Cardiovasc Intervent Radiol* 2008; 31:189-192.
- Erkan S, Wu C, Mehdod AA, Cho W, Transfeldt EE. Biomechanical comparison of transpedicular versus extrapedicular vertebroplasty using polymethylmethacrylate. *J Spinal Disord Tech* 2010; 23:180-185.
- Maranzano E, Latini P. Effectiveness

- of radiation therapy without surgery in metastatic spinal cord compression: final results from a prospective trial. *Int J Radiat Oncol Biol Phys* 1995; 32:959-967.
12. Baskar R, Lee KA, Yeo R, Yeoh KW. Cancer and radiation therapy: Current advances and future directions. *Int J Med Sci* 2012, 9:193-199.
  13. Gerszten PC, Ozhasoglu C, Burton SA, Vogel WJ, Atkins BA, Kalnicki SM. Cyber knife frameless stereotactic radiosurgery for spinal lesions: Clinical experience in 125 cases. *Neurosurgery* 2004, 55:89-99.
  14. Tomita K, Kawahara N, Baba H, Tsuchiya H, Nagata S, Toribatake Y. Total en bloc spondylectomy for solitary spinal metastasis. *Int Orthop* 1994; 18:291-298.
  15. Groenemeyer DH, Schirp S, Gevargez A. Image-guided radiofrequency ablation of spinal tumors: Preliminary experience with an expandable array electrode. *Cancer J* 2002; 8:33-39.
  16. Woertler K, Vestring T, Boettner F, Winkelmann W, Heindel W, Lindner N. Osteoid osteoma: CT-guided percutaneous radiofrequency ablation and follow-up in 47 patients. *J Vasc Interv Radiol* 2001; 12:717-722.
  17. Dupuy DE, Hong R, Oliver B, Goldberg SN. Radiofrequency ablation of spinal tumors: Temperature distribution in the spinal canal. *AJR* 2000; 175:1263-1266.
  18. Nour SG, Aschoff AJ, Mitchell IC, Emancipator SN, Duerk JL, Lewin JS. MR imaging-guided radio-frequency thermal ablation of the lumbar vertebrae in porcine models. *Radiology* 2002; 224:452-462.
  19. Molina CA, Gokaslan ZL, Sciubba DM. A systematic review of the current role of minimally invasive spine surgery in the management of metastatic spine disease. *Int J Surg Oncol* 2011:598148. doi:10.1155/2011/598148.
  20. Smith ZA, Yang I, Gorgulho A, Raphael D, De Salles AA, Khoo LT. Emerging techniques in the minimally invasive treatment and management of thoracic spine tumors. *J Neurooncol* 2012; 107:443-455.

