

## Non-Randomized Study

## Fluoroscopically Guided Infiltration of the Cervical Nerve Root: An Indirect Approach Through the Ipsilateral Facet Joint

Alexios Kelekis, MD, PhD<sup>1</sup>, Dimitrios K Filippiadis, MD, PhD<sup>1</sup>, Georgios Velonakis, MD<sup>1</sup>, Jean-Baptist Martin, MD, PhD<sup>2</sup>, Nikolaos Oikonomopoulos, MD<sup>1</sup>, Elias Brountzos, Prof<sup>1</sup>, and Nikolaos Kelekis, Prof<sup>1</sup>

From: <sup>1</sup>Second Radiology Department, University General Hospital "ATTIKON," Athens, Greece; and <sup>2</sup>Geneva Imaging Center, Geneva, Switzerland

Dr. A. Kelekis is Assistant Professor of Diagnostic and Interventional Radiology, 2nd Radiology Department, University General Hospital "ATTIKON," Athens, Greece. Dr. Filippiadis is an Interventional Radiologist-Consultant, 2nd Radiology Department, University General Hospital "ATTIKON," Athens, Greece. Dr. Velonakis is a Fellow, 2nd Radiology Department, University General Hospital "ATTIKON," Athens, Greece. Dr. Martin is an Interventional Neuroradiologist, CIRG Geneva Imaging Center, Geneva, Switzerland. Dr. Oikonomopoulos is a Radiologist, 2nd Radiology Department, University General Hospital "ATTIKON," Athens, Greece. Dr. Brountzos is a Professor of Interventional Radiology, 2nd Radiology Department, University General Hospital "ATTIKON," 1 Rimini str 12462 Athens, Greece. Dr. N. Kelekis is a Professor of Radiology, Head of 2nd Radiology Department, University General Hospital "ATTIKON," Athens, Greece.

Address Correspondence:  
Alexios Kelekis MD, PhD  
Ass. Professor of Diagnostic and Interventional Radiology  
2nd Radiology Department  
University General Hospital "ATTIKON,"  
1 Rimini str 12462 Athens/GR  
Email: akelekis@med.uoa.gr

Disclaimer on P. 296

Manuscript received: 07-22-2013  
Revised manuscript received: 02-11-2014  
Accepted for publication: 04-08-2014

Free full manuscript:  
www.painphysicianjournal.com

Transforaminal infiltrations in the cervical spine are governed by a higher rate of vascular puncture than in the lumbar spine. The purpose of our study is to assess the safety and efficacy of percutaneous, fluoroscopically guided nerve root infiltrations in cases of cervical radiculopathy. An indirect postero-lateral approach was performed through the ipsilateral facet joint.

During the last 2 years, 25 patients experiencing cervical radiculopathy underwent percutaneous, fluoroscopically guided nerve root infiltrations by means of an indirect postero-lateral approach through the ipsilateral facet joint. The intra-articular position of the needle (22-gauge spinal needle) was fluoroscopically verified after injection of a small amount of contrast medium which also verified dispersion of the contrast medium periradicularly and in the epidural space. Then a mixture of long-acting glucocorticosteroid diluted in normal saline (1.5/1 mL) was injected intra-articularly. A questionnaire with a Numeric Visual Scale (NVS) scale helped assess pain relief, life quality, and mobility improvement.

A mean of 2.3 sessions was performed in the patients of our study. In the vast majority of our patients 19/25 (76%), the second infiltration was performed within 7 – 10 days of the first one.

Comparing the pain scores prior (mean value  $8.80 \pm 1.080$  NVS units) and after (mean value  $1.84 \pm 1.405$  NVS units), there was a mean decrease of  $6.96 \pm 1.695$  NVS units [median value 7 NVS units ( $P < 0.001$ ) in terms of pain reduction, effect upon mobility, and life quality. There were no clinically significant complications noted in our study.

Fluoroscopically guided transforaminal infiltrations through the ipsilateral facet joint seem to be a feasible, efficacious, and safe approach for the treatment of patients with cervical radiculopathy. This approach facilitates needle placement and minimizes risk of complications.

**Key words:** Infiltrations, cervical spine, facet joint, transforaminal, pain, mobility, corticosteroid, fluoroscopy

**Pain Physician 2014; 17:291-296**

Intervertebral disc herniation and/or degenerative changes of the facet joints in the cervical spine are important and common causes of cervicobrachialgia (pain in the neck with radiation to the upper extremity

along the distribution of a specific nerve root). These kind of symptoms account for 203 out of 1,000 cases in people between the ages of 50 and 54 years old (1). Therapeutic armamentarium includes as a first

step a course of conservative therapy (analgesics, myorelaxants, NSAIDs, and physiotherapy). Infiltrations of the nerve root can also be performed either in combination with this conservative therapy course or performed solely as an intermediate step between conservative and other minimally invasive or surgical therapies (2). These infiltrations are performed under imaging guidance with a percutaneous transforaminal or interlaminar approach. Percutaneous infiltrations outweigh oral administration because they provide a direct and increased concentration of the medication at the inflammation site and in addition they seem to be not affected by the impaired blood flow in the compressive disc area. Corticosteroids provide an anti-inflammatory effect, a direct neural membrane stabilization effect, as well as modulation of peripheral nociceptor input (3).

During the last decade (2000 – 2010), there has been an annual increase of 70% and 92% in the number of spinal infiltrations performed for first time or as a repetitive session, respectively (4). Although the reported rate of clinically significant complications is very low (~1%), they can be quite serious with reports of transient or permanent paraplegia, brain infarction, arterial dissection, or death (1,5-13). Potential pathophysiologic explanations for the occurrence of such complications include intra-arterial injection of particulate corticosteroids (which potentially act as emboli) or inadvertent arterial puncture (with subsequent dissection or endothelial vasospasm induced by corticosteroids) (1,5-13). Specifically for the cervical spine, arterial punctures, despite imaging guidance, range between 4.1% – 19.4% depending on the approach (interlaminar or transforaminal) (14,15).

The purpose of this study is to assess the safety and efficacy of percutaneous, fluoroscopically guided nerve root infiltrations in cases of cervical radiculopathy. The approach was an indirect posterolateral one performed through the ipsilateral facet joint.

## **METHODS**

All patients were informed about the technique itself as well as possible benefits and complications and signed a written consent form. IRB approval was obtained. The principles of national legislation and the Declaration of Helsinki were followed.

### **Patient Selection and Evaluation**

During the last 2 years we prospectively studied and compared a group of 25 consecutive patients expe-

riencing cervical radiculopathy due to either intervertebral disc herniation and/or degenerative changes to intervertebral disc/facet joint complex (diagnosed with magnetic resonance imaging [MRI]) with no neurologic deficit.

Patients underwent a series of fluoroscopically guided percutaneous cervical nerve root infiltrations at the level of interest (as determined by the MRI and the distribution of pain along the course of a specific nerve root in the upper arm). Each patient underwent physical examination and coagulation laboratory tests at least 24 hours prior to the infiltration. Before each procedure the patient underwent a thorough clinical examination, in correlation with medical records, evaluation of all imaging studies was performed. Preoperational imaging included x-rays and multiplane MRI (T1W, T2W, STIR). Exclusion criteria for the procedure included response to conservative treatment; untreatable coagulopathy; active, systemic, or local infections; and patient's unwillingness to consent to the procedure.

### **Percutaneous Infiltration Procedure**

Infiltration was performed on an outpatient basis and fluoroscopic control, with a 9 cm 22G spinal needle and the patient sitting in the fluoroscopy unit (Fig. 1). After appropriate preoperative preparation, draping, and strict sterilization of the area of interest, the spinal needle under fluoroscopic guidance (on true lateral projection) was inserted at a lateral-posterolateral approach towards the facet joint of interest (Fig. 2). Once inside the joint, injection of a small amount of contrast medium verified the intra-articular needle positioning as along with the intra-articular and epidural dispersion (Fig. 3). Once the desired position was achieved, a mixture of long-acting glucocorticoid (cortivasol [Altim 3.75 mg/1.5 mL], Sanofi Aventis, France) and normal saline was injected (1.5/1 mL). The patient remained in the hospital for 60 minutes and was then discharged.

### **Outcome Measures**

Pain and mobility were recorded prior to and at the end of the infiltration series with clinical evaluation and an inventory containing a 0 – 10 unit Numeric Visual Scale (NVS). This inventory included a 10cm scale from 0 to 10 which the patient subjectively assigns his/her pain on a score of minimum 0 (no pain) to maximum 10 (worst pain patient can imagine) (16). In addition, the inventory contains questions concerning the pain itself and its influence upon the patient's activities



Fig. 1. Percutaneous infiltration was performed under extensive local sterility measures in the angio-suite with the patient in a sitting position.

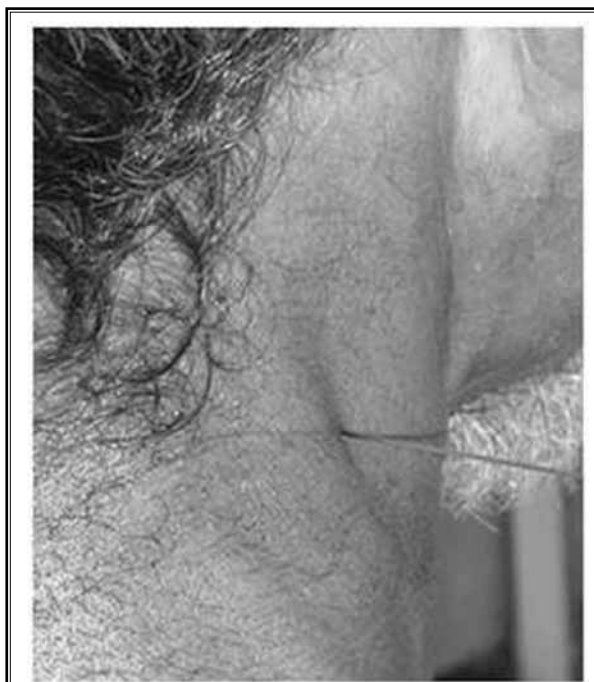

Fig. 2. Image of the patient during the infiltration after removal of the sterile cover.

(sleep, occupation and housework, walking) and mobility impairment (16).

The end point was one year post treatment. Patients were followed one week after the first injection for a subsequent treatment and then if asymptomatic, in 3 – 6 and 12 months. Follow-up consisted of clinical visits (general, clinical, and neurological condition; pain reduction; and mobility improvement according to NVS scale) one week after the session. If pain reduction was more than 80%, follow-up was rescheduled. In all other cases, a second infiltration was performed with subsequent re-visit one week afterwards. The maximum number of sessions performed was 3 – 4 per 12 months. Questions asked during the follow-up period concerned the pain reduction and mobility improvement and whether the procedure had decreased or totally relieved the symptoms they were treated for.

### Statistical Analysis

Data were summarized using mean value, median value, and standard deviation. NVS pain scores prior to and post infiltrations were compared using Paired

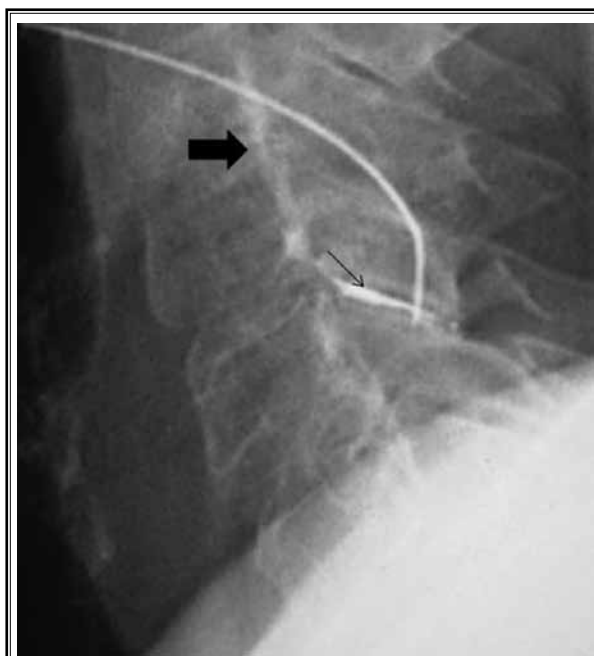


Fig. 3. Lateral fluoroscopic view: needle is located intra-articularly. Notice the dispersion of the contrast medium from the facet joint (thin arrow) inside the epidural space (thick arrow).

Samples t-Test and Wilcoxon Signed Rank Test. *P* values less than 0.05 were considered to indicate a statistically significant difference. Statistical analyses were performed with IBM SPSS Statistics 21.

## RESULTS

A total of 58 fluoroscopically guided infiltrations were performed on the 25 patients in our study with a mean of 2.3 sessions per patient. In the vast majority of

our patients (19/25; 76%), the second infiltration was performed within 7 – 10 days of the first one. Levels of interest included C3-C4 (1/25 [4%]), C4-C5 (8/25 [32%]), C5-C6 (12/25 [48%]), and C6-C7 (4/25 [16%]).

Comparing the pain scores prior to (mean value  $8.80 \pm 1.080$  NVS units, median value 9 NVS units) and after the session series (mean value  $1.84 \pm 1.405$  NVS units, median value 2 NVS units), there was a mean decrease of  $6.96 \pm 1.695$  NVS units (median value 7 NVS units [ $P < 0.001$ ]) in terms of pain reduction, effect upon mobility, and life quality (Figs. 4, 5).

No complications (minor or major) were noted in our study population. Satisfactory distribution of contrast medium within the cervical facet joint of interest was shown in all cases (i.e. a true intra-articular injection was performed in all cases – technical success 100%).

## DISCUSSION

The purpose of this study is to assess the safety and efficacy of an indirect, fluoroscopically guided approach through the ipsilateral facet joint in patients with cervical nerve root radiculopathy.

The common pathway in the pathophysiologic mechanisms described for the potential complications of transforaminal infiltrations is arterial puncture, most commonly of the small intraforaminal arteries (medullary feeding, segmental, or radicular arteries) which arise from vertebral arteries and contribute to anterior artery distribution in an inconsistent course (1).

Various approaches have been described in the literature in order to minimize this inadvertent arterial puncture including an “indirect” cervical nerve root

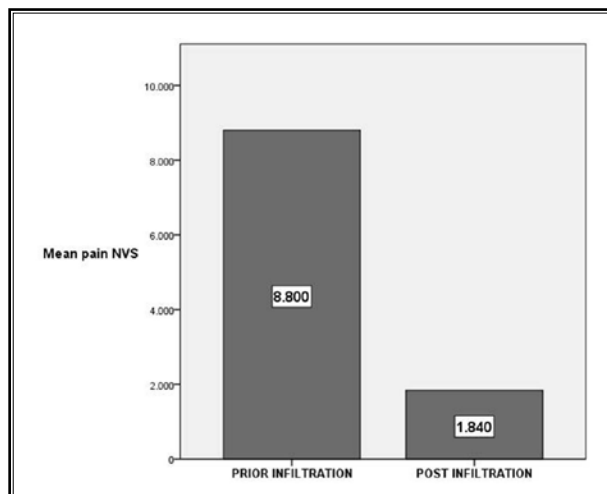


Fig. 4. Chart illustrating the mean self-reported pain scores of the patients included in our study prior and after the end of the infiltrations course. There was a mean decrease of  $6.96 \pm 1.695$  NVS units (median value 7 NVS units [ $P < 0.001$ ]) in terms of pain reduction, effect upon mobility, and life quality.

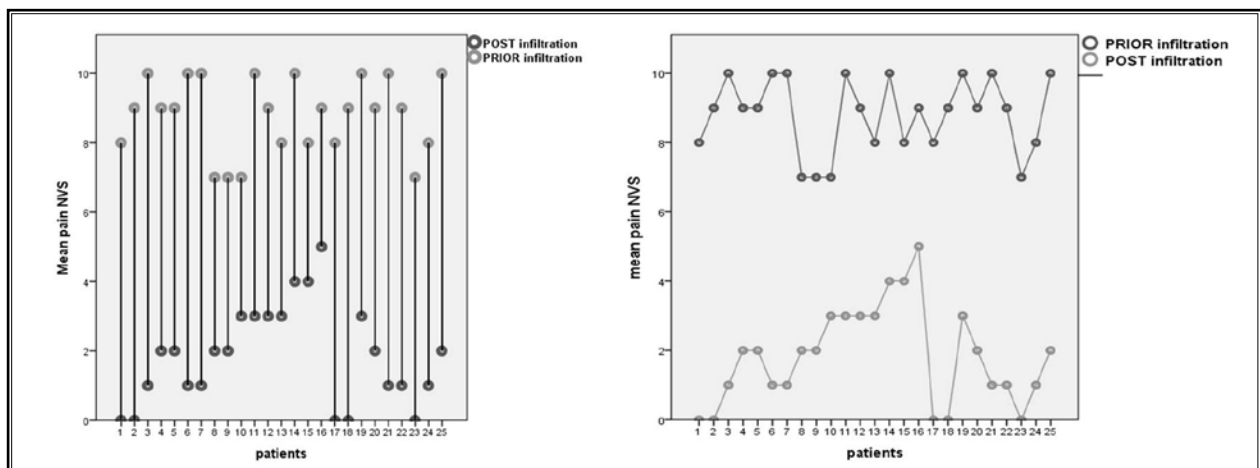


Fig. 5. Charts illustrating the self-reported pain scores for each patient included in our study prior and after the end of the infiltrations course.

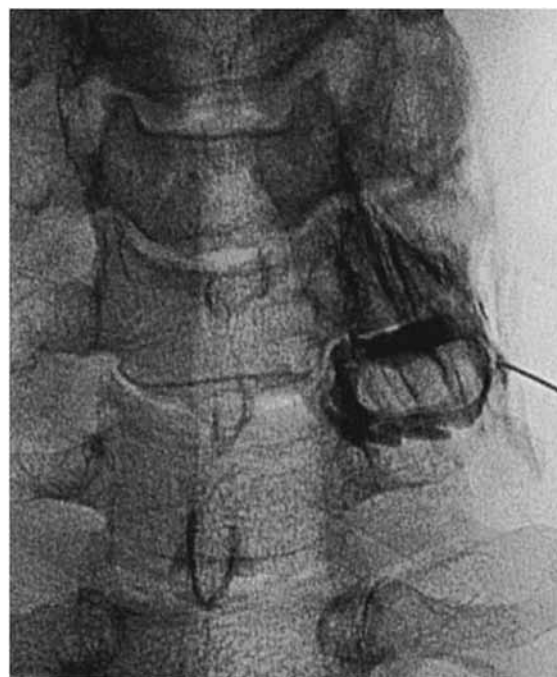injection technique with a dorsal approach or modified dorsal direct approach (1,17,18).

Our approach seems to be very safe since it is lateral to posterolateral and final needle position is intra-articular. The efficacy of the approach is based upon puncture of the facet joint capsule with subsequent distribution of the corticosteroid intra-articularly, periradicularly, and within the epidural space (Fig. 6). More specifically, the more medially the needle is located inside the facet joint the higher the chances for desired injectate distribution.

Another advantage of our approach is the fluoroscopic guidance, which allows a real time evaluation of inadvertent arterial puncture with subsequent intra-arterial contrast medium injection, a fact not true whenever axial imaging (computed tomography [CT] or MRI) are used for guidance of such procedures. A combination of A-P and lateral projections defines in maximum detail the facet joint of interest. Since the puncture is performed in a lateral position, it is impossible to reach the contralateral facet joint. The joints are projected one on top of the other for a true lateral projection. Once through the capsule, there is a tactile feedback that can be confirmed with contrast medium injection and A-P projection. If one is not in the correct plane one touches bone above or below the facet line. The foramen is anterior to this approach. Control of depth can be achieved with A-P projection, which is redundant once the learning curve is achieved. Concerning the needle's size, 22G needles were chosen on the basis of enhanced steering; thinner needles are not so easy to precisely steer. 22G needles are standard use in our department for facet and foraminal infiltrations.

Success rates concerning pain reduction and mobility improvement in the patients of our study are found within the accepted range as reported in the literature (19-21). True intra-articular injections are governed by higher and longer lasting efficacy as opposed to periarthral ones (22). The choice of corticosteroid is another controversial issue. Particulate corticosteroids (obviously depending on the aggregate size) may act as emboli but their use seems to be governed by higher and longer lasting success rates; although in the literature one can find studies reporting no differences among the use of particulate and non-particulate steroids (5,22). Our approach seems to combine the higher efficacy of particulate corticosteroids and the higher safety profile of the preferred route, since the needle is located intra-articularly and away from the surrounding vessels.

There is good evidence for cervical nerve root pain



*Fig. 6. AP fluoroscopic view: needle is located intra-articularly. Notice the dispersion of the contrast medium inside the joint as well as at the level of the foramen.*

treated by epidural or transforaminal infiltrations and fair evidence for intra-articular cervical facet joint injections (23-25). Although not encountered in our study, dural puncture or spinal cord injection are distinct possibilities. To achieve dural puncture, though, one has to pass through the facet in order to access the epidural space and then the cord. Since the facet is not in one plane passing through it is rather difficult.

Limitations of our study include the small number of patients and the lack of a control group who would undergo fluoroscopically guided cervical infiltrations by means of a direct transforaminal approach as well as of a conventional interlaminar epidural infiltration.

## **CONCLUSION**

Infiltrations of cervical nerve roots by means of an indirect approach through the ipsilateral facet joint performed under fluoroscopic guidance seem to be a feasible, efficacious, and safe approach for the treatment of patients with cervical radiculopathy. This approach facilitates needle placement and minimizes the risk of complications and vascular puncture in the cervical spine.

## Disclaimer

There was no external funding in the preparation of this manuscript. Conflict of interest: Each author certifies that he or she, or a member of his or her immediate family, has no commercial association (i.e., consultancies, stock ownership, equity interest, patent/licensing arrangements, etc.) that might pose a conflict of interest in connection with the submitted manuscript.

## REFERENCES

- Sutter R, Pfirmann CW, Zanetti M, Hodler J, Peterson CK. CT-guided cervical nerve root injections: Comparing the immediate post-injection anesthetic-related effects of the transforaminal injection with a new indirect technique. *Skeletal Radiol* 2011; 40:1603-1608.
- Kelekis A, Filippiadis D. Percutaneous therapy versus surgery in chronic back pain: how important is imaging in decision-making? *Imaging in Medicine* 2013; 5:187-196.
- Abdi S, Datta S, Trescot AM, Schultz DM, Adlaka R, Atluri SL, Smith HS, Manchikanti L. Epidural steroids in the management of chronic spinal pain: A systematic review. *Pain Physician* 2007; 10:185-212.
- Manchikanti L, Buenaventura RM, Manchikanti KN, Ruan X, Gupta S, Smith HS, Christo PJ, Ward SP. Effectiveness of therapeutic lumbar transforaminal epidural steroid injections in managing lumbar spinal pain. *Pain Physician* 2012; 15:E199-E245.
- Dreyfuss P, Baker R, Bogduk N. Comparative effectiveness of cervical transforaminal injections with particulate and nonparticulate corticosteroid preparations for cervical radicular pain. *Pain Med* 2006; 7:237-242.
- Scanlon GC, Moeller-Bertram T, Romanowsky SM, Wallace MS. Cervical transforaminal epidural steroid injections. More dangerous than we think? *Spine* 2007; 32:1249-1256.
- Suresh S, Berman J, Connell DA. Cerebellar and brainstem infarction as a complication of CT-guided transforaminal cervical nerve root block. *Skeletal Radiol* 2007; 36:449-452.
- Rozin L, Rozin R, Koehler SA, Shakir A, Ladhani S, Barmada M, Dominick J, Wecht CH. Death during transforaminal epidural steroid nerve root block (C7) due to perforation of the left vertebral artery. *Am J Forensic Med Pathol* 2003; 24:351-355.
- Brouwers PJAM, Kottink EJBL, Simon MAM, Prevo RL. A cervical anterior spinal artery syndrome after diagnostic blockade of the right C6-nerve root. *Pain* 2001; 91:397-399.
- Rosenkranz M, Grzyska U, Niesen W, Fuchs K, Schummer W, Weiller C, Röther J. Anterior spinal artery syndrome following periradicular cervical nerve root therapy. *J Neurol* 2004; 251:229-231.
- Karasek M, Bogduk N. Temporary neurologic deficit after cervical transforaminal injection of local anesthetic. *Pain Med* 2004; 5:202-205.
- Tiso RL, Cutler T, Catania JA, Whalen BS, Pharm BCPS. Adverse central nervous system sequelae after selective transforaminal block: The role of corticosteroids. *Spine J* 2004; 4:468-474.
- Wallace MA, Fukui MB, Williams RL, Ku A, Baghai P. Complications of cervical selective nerve root blocks performed with fluoroscopic guidance. *AJR* 2007; 188:1218-1221.
- Furman MB, Giovanniello MT, O'Brien EM. Incidence of intravascular penetration in transforaminal cervical epidural steroid injections. *Spine* 2003; 28:21-25.
- Manchikanti L, Malla Y, Wargo BW, Cash KA, Pampati V, Fellows B. A prospective evaluation of complications of 10,000 fluoroscopically directed epidural injections. *Pain Physician* 2012; 15:131-140.
- Erginousakis D, Filippiadis DK, Malagari A, Kostakos A, Broutzos E, Kelekis NL, Kelekis A. Comparative prospective randomized study comparing conservative treatment and percutaneous disk decompression for treatment of intervertebral disk herniation. *Radiology* 2011; 260:487-493.
- Wolter T, Mohadjer M, Berlis A, Knoeller S. Cervical CT-guided, selective nerve root blocks: Improved safety by dorsal approach. *Am J Neuroradiol* 2009; 30:336-337.
- Wolter T, Knoeller S, Berlin A, Hader C. CT-guided cervical selective nerve root block with a dorsal approach. *Am J Neuroradiol* 2010; 31:1831-1836.
- Vallee JN, Feydy A, Carlier RY, Mutschler C, Mompoin D, Vallee CA. Chronic cervical radiculopathy: Lateral-approach periradicular corticosteroid injection. *Radiology* 2001; 218:886-892.
- Slipman CW, Lipetz JS, Jackson HB, Rogers DP, Vresilovic EJ. Therapeutic selective nerve root block in the nonsurgical treatment of atraumatic cervical spondylosis: A retrospective analysis with independent clinical review. *Arch Phys Med Rehabil* 2000; 81:741-746.
- Lee JW, Park KW, Chung SK, Yeom JS, Kim KJ, Kim HJ, Kang HS. Cervical transforaminal epidural steroid injection for the management of cervical radiculopathy: A comparative study of particulate versus non-particulate steroids. *Skeletal Radiol* 2009; 38:1077-1082.
- Kelekis AD, Somon T, Yilmaz H, Bize P, Broutzos EN, Lovblad K, Ruefenacht D, Martin JB. Interventional spine procedures. *Eur J Radiol* 2005; 55:362-383.
- Diwan S, Manchikanti L, Benyamin RM, Bryce DA, Geffert S, Hameed H, Sharma ML, Abdi S, Falco FJ. Effectiveness of cervical epidural injections in the management of chronic neck and upper extremity pain. *Pain Physician* 2012; 15:E405-E434.
- Falco FJ, Manchikanti L, Datta S, Wargo BW, Geffert S, Bryce DA, Atluri S, Singh V, Benyamin RM, Sehgal N, Ward SP, Helm S 2nd, Gupta S, Boswell MV. Systematic review of the therapeutic effectiveness of cervical facet joint interventions: An update. *Pain Physician* 2012; 15: E839-E868.
- Manchikanti L, Abdi S, Atluri S, Benyamin RM, Boswell MV, Buenaventura RM, Bryce DA, Burks PA, Caraway DL, Calodney AK, Cash KA, Christo PJ, Cohen SP, Colson J, Conn A, Cordner H, Coubarous S, Datta S, Deer TR, Diwan S, Falco FJ, Fellows B, Geffert S, Grider JS, Gupta S, Hameed H, Hameed M, Hansen H, Helm S 2nd, Janata JW, Justiz R, Kaye AD, Lee M, Manchikanti KN, McManus CD, Onyewu O, Parr AT, Patel VB, Racz GB, Sehgal N, Sharma ML, Simopoulos TT, Singh V, Smith HS, Snook LT, Swicegood JR, Vallejo R, Ward SP, Wargo BW, Zhu J, Hirsch JA. An update of comprehensive evidence-based guidelines for interventional techniques in chronic spinal pain. Part II: Guidance and recommendations. *Pain Physician* 2013; 16:S49-S283.