

Case Series

Case Series on Variable Presentation of Ligamentum Flavum Stimulation Following Percutaneous Cylindrical Spinal Cord Stimulator Lead Implants

Susie S Jang, MD¹, Jeffrey E. Arle, MD, PhD², Jatinder S. Gill, MD¹, and Thomas T. Simopoulos, MD¹

From:¹Department of Anesthesia, Critical Care and Pain Medicine, Beth Israel Deaconess Medical Center, Boston, MA; ²Department of Neurosurgery, Beth Israel Deaconess Medical Center, Boston, MA

Address Correspondence:
Dr. Susie S Jang
Beth Israel Deaconess Medical Center
330 Brookline Avenue
FD-407
Boston, MA 02215
E-mail: sjang@bidmc.harvard.edu

Disclaimer: Presented in part at the 2012 American Society of Interventional Pain Physicians in Arlington, VA.
Conflict of interest: Each author certifies that he or she, or a member of his or her immediate family, has no commercial association (i.e., consultancies, stock ownership, equity interest, patent/licensing arrangements, etc.) that might pose a conflict of interest in connection with the submitted manuscript.

Manuscript received: 10-16-2013
Accepted for publication: 01-22-2014

Free full manuscript:
www.painphysicianjournal.com

Background: Stimulation-evoked discomfort secondary to ligamentum flavum stimulation (LFS) is a technological limitation of percutaneous spinal cord stimulator (SCS) lead implants. There is a paucity of literature describing the clinical presentation and time periods at which this side effect may present following insertion of cylindrical lead(s).

Objective: To describe a series of 5 patients who presented at varying time periods after SCS lead placement with LFS.

Study Design: Retrospective case series.

Methods: We performed a chart review of online medical records of patients with symptoms consistent with LFS at an academic interventional pain clinic identified over 7 consecutive years (2006 - 2013).

Results: LFS most frequently presented within months of implantation of cylindrical leads. One patient complained of LFS during the temporary trial while another developed LFS after lead revision. All patients were successfully treated when paddle electrodes replaced percutaneous cylindrical leads.

Conclusion: LFS may present as a barrier to successful SCS treatment. Clinicians placing percutaneous SCS leads should be aware of the variable time course of LFS presentation. Paddle style electrodes seem to offer an enduring solution to LFS so that patients may continue to benefit from SCS therapy.

Key words: Percutaneous electrodes, cylindrical electrode, paddle electrodes, ligamentum flavum stimulation, unwanted stimulation

Pain Physician 2014; 17:E397-E403

Spinal cord stimulation (SCS) has been utilized since the late 1960s for chronic, intractable pain. Percutaneous placement of electrodes is a minimally invasive procedure that allows for a therapeutic trial prior to surgical placement of a permanent cylindrical or paddle style electrode with an implantable pulse generator (IPG). Since their introduction in the 1970s, percutaneous cylindrical

electrodes have become the mainstay for trials and are also commonly employed for permanent implantation (1). Like paddle style electrodes, SCS administered through percutaneous leads can render similar uncomfortable side effects. Specifically, dorsal root activation in the low thoracic region results in unpleasant abdominal stimulation. Recruitment of these fibers is easily appreciated by patients; they

report thoracic radicular sensations, which may progress to segmental reflex muscle activation as the amplitude of the stimulation is increased. Because such a side effect has been commonly recognized to potentially limit therapy for both styles of electrodes, strategies such as transverse tripolar stimulation have been put forth as a solution (2).

However, a unique side effect of SCS therapy confined to percutaneous leads is inadvertent ligamentum flavum stimulation (LFS). LFS, as first described by North et al (3), is a non-radiating discomfort localized to the midline and unaccompanied by muscle contractions. It is believed to occur due to recruitment of small fibers in the ligamentum flavum by the circumferential stimulation of cylindrical electrodes. North et al entirely eliminated this side effect with paddle style electrodes. They further demonstrated that if the paddle electrode was inverted, LFS immediately reoccurred, supporting the argument that the nociceptive fibers in the ligamentum flavum are activated. Since the first description by North et al, little has been reported regarding the clinical presentation and course of LFS. We present a case series of 5 patients who presented with LFS at varied times after percutaneous cylindrical lead placement.

Methods/Case Reports

Case 1

A 55-year-old woman volunteered as a donor partial hepatectomy and underwent a laparotomy. She had a complicated post-operative course that included intra-abdominal hematoma, infection, and biliary leak. She eventually recovered, but developed chronic neuropathic abdominal wall pain spanning the right T6 to T9 dermatomes. She was placed on a combination of methadone and gabapentin with modest pain reduction. Intercostal blocks and cryoablation provided good but very temporary relief. Psychological assessment revealed mild depression but the patient was well motivated and continued to maintain employment. A successful trial of SCS was provided for the time course of 7 days after an 8-contact lead was placed via the L1/2 interspace and advanced to the top of the T6 vertebral level, slightly to the right of visual midline. The patient then had a permanent system placed with one 8-contact lead and rechargeable IPG (Precision Boston Scientific, Valencia, CA). The patient had good pain relief and maintained employment for the next 4 years.

She then re-presented with complaints of pain

more towards the right lower quadrant of the abdomen. Re-evaluation by her gastroenterologist using endoscopy and computed tomography (CT) failed to explain the symptoms, and so they were attributed to the spread of her neuropathic pain. The patient was scheduled to have an additional lead in order to render paresthesia coverage of the right lower quadrant. During the revision, the original lead at the T6 level was moved to a paraforaminal location to avoid any unwanted stimulation to the lower extremities (Figs. 1, 2). At no point intraoperatively did the patient indicate that she experienced stimulation in the back over the spinous processes. Over the next 2 months she became progressively frustrated because of the inability to use the SCS device on account of uncomfortable mid spine stimulation (Fig. 3). Evaluation of the leads revealed normal ranged impedances and reprogramming could not eliminate unwanted mid-back stimulation. LFS stimulation was suspected and the patient had the leads replaced with paddle style electrodes (anterograde lead, Lamitrode 44TM, retrograde lead Lamitrode Tripole 16cTM, St. Jude Medical Neuromodulation Division, Plano, TX) (Fig. 4). After a 2½-year follow-up, she continues to have good therapeutic results from SCS without LFS.

Case 2

A 33-year-old woman with a 2 year history of chronic right S1 radiculopathy, despite a successful L5/S1 discectomy, presented with ongoing severe radiating leg pain. She had tried multiple epidural steroid injections, physical therapy, and was dependent on sustained morphine release and breakthrough oxycodone/acetaminophen. After psychological evaluation, she was offered a trial of SCS. A single 8-contact lead (Octrode, St. Jude Medical Neuromodulation Division, Plano, TX) was placed via the T12/L1 interspace and advanced to the mid T8 vertebral level. She reported having good pain relief of her axial and radicular symptoms during a 7 day temporary trial. However, it was noted from initial activation of the lead as well as during the trial that she had mid-back discomfort near the T8-T9 spinous processes. This was minimized with programming but could not be eliminated. Because of suspected LFS, a 16-contact paddle and a rechargeable IPG (Tripole 16C and Eon miniTM, St. Jude Medical Neuromodulation Division, Plano, TX) were inserted. At one year post-implant, the patient continues to report stimulation in the right lower extremity, without any uncomfortable mid-back stimulation.

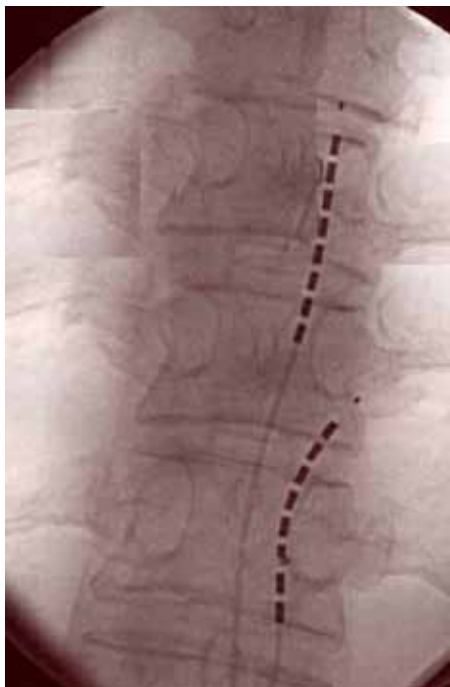


Fig. 1. Antero-posterior fluoroscopic view of cylindrical leads with tips at the level of T6 and T8 respectively in a paraforaminal location for right abdominal paresthesia coverage.

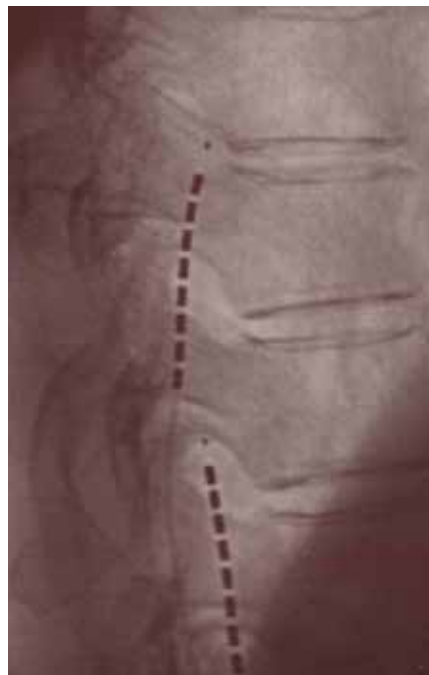
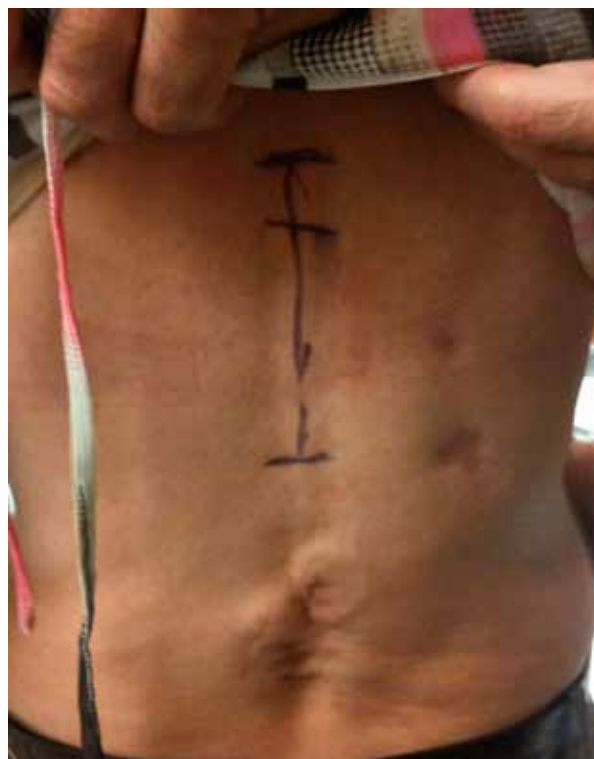
Fig. 2. Lateral fluoroscopic image of leads presented in Fig. 1 demonstrating paraforaminal location of dual cylindrical leads of Case 1.

Fig. 3. Marking represents the location of ligamentum flavum stimulation felt by the patient in Case 1. The 2 superior markings represent the simulation difference between the 2 programs, both of which are perceived by the patient as pain over the spinous processes. The inferior horizontal line represents the inferior border of where stimulation ceases to be perceived.



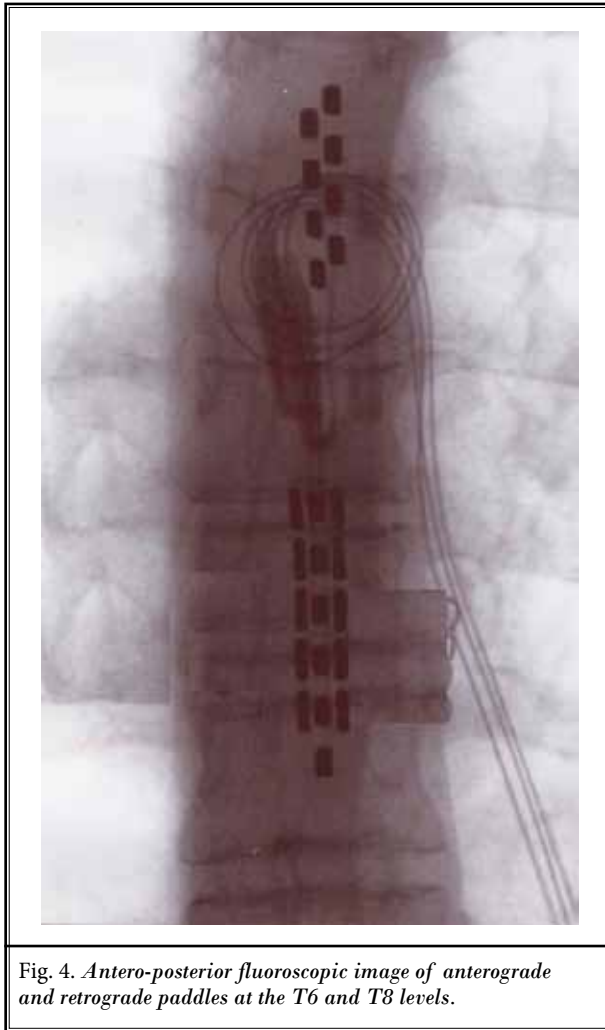


Fig. 4. Antero-posterior fluoroscopic image of anterograde and retrograde paddles at the T6 and T8 levels.

Case 3

A 45-year-old woman with history of a left lower extremity crush injury was status post multiple reconstructive surgeries. She had developed complex regional pain syndrome I and had failed to improve from conservative management consisting of serial sympathetic blocks, physical therapy, and poly-pharmaceuticals, which included sustained release oxycodone, duloxetine, clonazepam, and tizanidine. Psychological evaluation did not reveal any conditions that would preclude a good outcome from SCS therapy. The patient underwent a trial of SCS with a single percutaneous 8-contact lead (Boston Scientific, Valencia, CA) placed via L1/L2 and advanced to the top of the T12 vertebral level in order to ensure capture of the calf and foot. A 5 day temporary trial resulted in marked pain reduction. She had a permanent system placed consisting of dual

percutaneous 8-contact leads inserted at T12/L1 with the IPG (Precision Boston Scientific, Valencia, CA) placed in the right buttock. Excellent paresthesia coverage and consequent improvement in pain allowed for her to return to full employment one month after permanent implantation. Two months post permanent implant, she presented with a chief complaint of pressure-like pulling sensation over the midline at T12-L1. Fluoroscopic evaluation failed to reveal migration and electrical impedances were within normal range. Reprogramming could not eliminate the dysesthesias in the upper back region resulting in the patient's inability to use the SCS device. Replacement of the leads with a paddle style electrode (Artisan, Boston Scientific) eliminated LFS and at 6 month follow-up, the patient reports consistently good therapeutic response.

Case 4

A 46-year-old woman presented with bilateral lumbosacral radiculopathy that persisted despite L4/5 and L5/S1 laminectomy and posterior fusion. The patient had tried multiple courses of physical and injection-based therapies without success. She had been tried on multiple medications and continued on a combination of metaxalone, gabapentin, and hydrocodone/acetaminophen. Following a favorable psychological evaluation, the patient underwent a temporary single 8-contact lead (Octrode, St. Jude Medical Neuromodulation Division, Plano, TX) placement via the T12/L1 interspace and advanced to the inferior endplate of the T8 vertebral body. She experienced 100% relief of her radicular pain and 50% relief of low back pain symptoms. Permanent SCS implant consisted of dual 8-contact leads at the same level as the trial with a rechargeable IPG (Eon mini, Saint Jude Medical) placed in the left buttocks. At her 2 month follow-up visit, the patient reported an 85% overall reduction in pain intensity and was very satisfied with the therapy.

At 4 months after implantation, she complained of pain in her upper back with device activation and LFS was suspected. Over the next 2 months, this pain became progressive to the point where she could no longer use the device. Investigation of the device revealed no migration as well as no electrical impedance changes. Reprogramming of the stimulating contacts could not establish the necessary paresthesia coverage without suspected LFS. A paddle lead (Penta, St. Jude Medical Neuromodulation Division, Plano, TX) was used to replace the cylindrical leads and at 6 months follow-up, she had no reports of uncomfortable mid-back stimulation.

Case 5

A 61-year-old man presented with bilateral leg pain consistent with lumbosacral radiculopathy, which developed after a work-related injury. He had received a laminectomy with subsequent magnetic resonance imaging (MRI) studies revealing only modest foraminal stenosis at the lower lumbar levels. He failed to improve with serial epidural steroid injections, physical therapy, and multimodal analgesia that included hydrocodone, duloxetine, and pregabalin. After a favorable psychological evaluation, placement of a percutaneous SCS 8-contact trial lead (Octrode, St. Jude Medical Neuromodulation Division, Plano, TX) at the superior endplate of T8 achieved 50% pain reduction in the lower extremities. Subsequently, he underwent permanent implantation of dual 8-contact leads at the T8 level with a rechargeable IPG (EON, St. Jude Medical Neuromodulation Division, Plano, TX) placed in the right buttock.

He initially developed LFS immediately after placement, which resolved with re-programming resulting in marked alleviation of his sciatic pain. Specifically, cathodes of the second lead immediately to the left of the midline lead could no longer be used because they seemed to be the cause of LFS. Two years and 3 months after permanent SCS placement, he again developed axial stimulation related pain at the T9 level of the stimulating electrode. The patient reported that the stimulation in the upper back intensified over the course of one month to the point where he could no longer use the SCS device despite previously achieving good relief of his radicular symptoms. The leads were checked for electrical integrity, and no impedance abnormalities were found. Reprogramming of the device at this point could not establish paresthesia coverage without LFS. LFS resolved after a paddle style electrode (Penta, St. Jude Medical Neuromodulation Division, Plano, TX) was placed. At 2-year follow-up, the patient reported stable therapeutic paresthesia coverage of his lower extremities and no LFS.

Discussion

To our knowledge, this is the first case series describing LFS beyond the trial stage and the varying time intervals at which LFS may present after percutaneous cylindrical lead placement. North et al (3) described LFS only in the trial phase of SCS with percutaneous cylindrical leads. LFS seems to be able to develop months to years after successful implantation and may even manifest following revision of a lead in someone who

previously did not describe symptoms of LFS. When LFS does occur, it progressively disrupts therapy so that patients have little choice but to cease using the device. Although stimulation amplitudes were not recorded in these cases, patients could no longer use the amplitudes that render comfortable and effective paresthesias over the corresponding painful regions (e.g. back and legs). This was because the therapeutic level of amplitude caused significant pain localized over the stimulating portion of the lead. For patients presenting with restricted mid- or near mid-back pain at the level of the active stimulating contacts corresponding to the spinous processes, LFS should be considered as a potential cause regardless of time from lead placement (Fig. 3). The pain over the spinous process occurred only with the device on and was far above the lead anchors and site(s) of insertion. The physical exam did not reveal any point tenderness over the thoracic paraspinous muscles or spinous processes. Finally, LFS can occur with the electrode in a paraforaminal location (Case 1, Figs. 1, 2) or in a classic midline or just off midline for dorsal column stimulation (Cases 2 – 5).

Although the incidence of LFS is not established in the literature, it is felt to be a relatively uncommon side effect of SCS. This may relate to the fact that the innervation of the ligamentum flavum has been shown to be poor (4-8). The ligamentum flavum has no known painful pathological lesions, and the high elastin content gives it great dispensability for resisting injury (9). Nonetheless, some patients may have small nociceptive fibers on the anterior surface of the ligamentum flavum that may become activated by cylindrical electrodes. One study supports the possibility that the human ligamentum flavum is capable of nociception by demonstrating the presence of sodium channel subtypes expressed in nociceptors (10). Over time, fibrosis is known to develop over stimulating contacts and impedances between contacts are known to vary over the time (11). This effect commonly requires higher amplitudes on the cathode(s) in order to achieve therapeutic paresthesia. Higher levels of stimulating cathodic energy may also inadvertently be distributed to small fibers innervating the ligamentum flavum. Consequently, LFS may be seen months to years after implantation. It may also develop in the context of lead revision if the new lead is placed over a firm, fibrotic scar that results in it being positioned closer to the ligamentum flavum. Alternatively, there is a theoretical possibility that some patients may develop nerve ingrowth following the insertions of leads into the epidural space. While nerve ingrowth

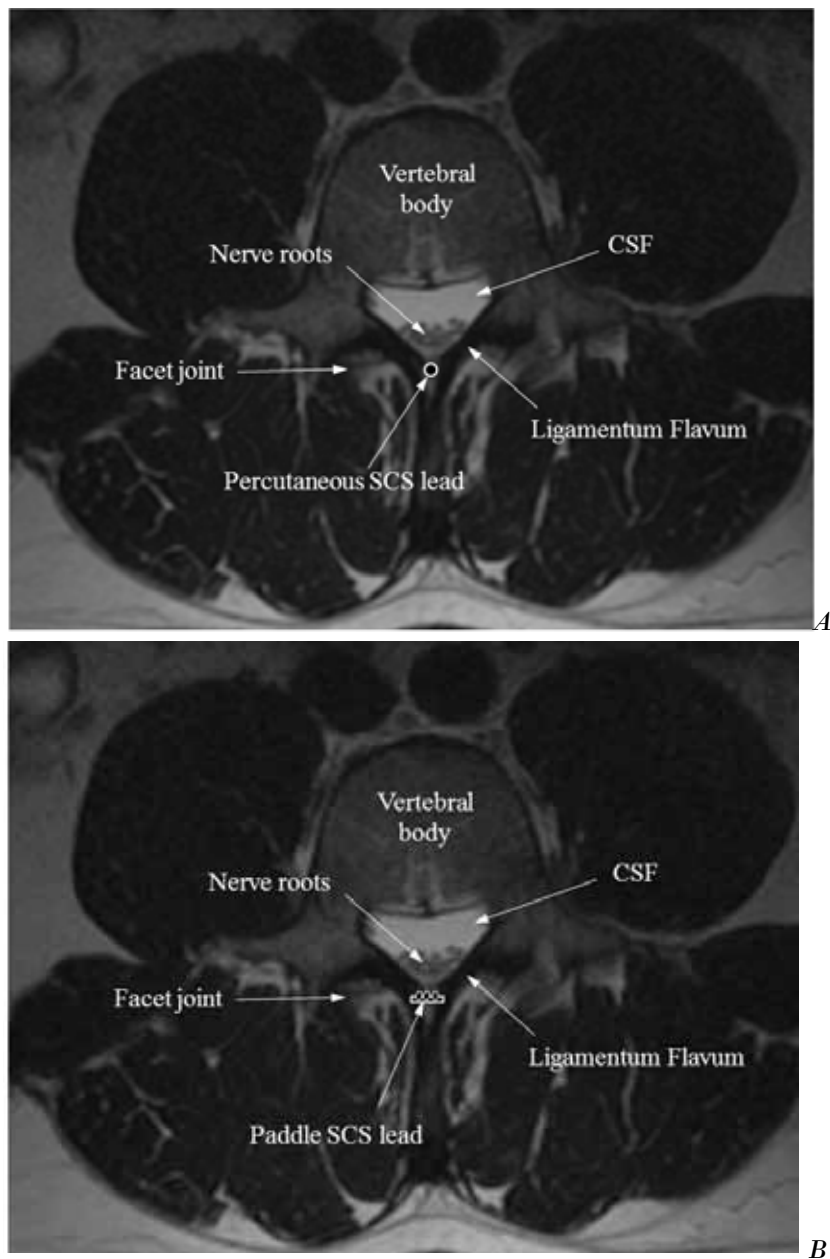


Fig. 5. A) T2 weighted MRI of lumbar spine, axial view. Diagram of percutaneous cylindrical spinal cord stimulator in epidural space. B) Diagram of insulated paddle style electrode placement in similar space.

has not been demonstrated to occur at the level of the ligamentum flavum, it is well known to occur in other spinal structures, such as in the intervertebral disc (12,13).

An important consideration in this case series is that LFS as a diagnosis is speculative. There was no

confirmatory measurement of the neuronal activation in any of the immediate posterior epidural space structures following a stimulation pulse. However, a reasonable argument supporting preferable stimulation of the ligamentum flavum can be made on the basis of electrode proximity and tissue resistivity. Fig.

5 demonstrates both a cylindrical and paddle lead with proximal anatomic structures that primarily includes the ligamentum flavum, lamina, and very laterally, the facet joints. The resistivity of connective tissue proteins, such as collagen and elastin that comprise the dura mater and ligamentum flavum is relatively low when compared to bone (14). Vertebral bone has a resistivity of 50,000 Ohms-mm compared to only 1,666 Ohms-mm for the dura mater (15). The current will flow in the path of the lowest resistance during a stimulation pulse to affect neurons in connective tissue such as the ligamentum flavum. Further conduction to the interspinous ligament is also possible and cannot be entirely excluded clinically as the stimulation reported by patients is midline. The paraspinal muscles are unlikely to be involved given both the off midline anatomic location as well as the lack of clinically apparent spasm.

A practical solution for patients in all cases was to replace percutaneous cylindrical leads with paddle style electrodes. Interestingly, even with more programming options available in 16-contact, multichannel systems compared to 4-contact cylindrical leads used over the prior 15 years, therapeutic paresthesia coverage could not be re-established. This side effect of SCS did not

vary amongst manufactures given that all percutaneous electrode designs are similar in their cylindrical omnidirectional characteristic. Paddle electrodes are always insulated on the dorsal surface regardless of the manufacturer. The dorsal surface of the paddle adequately insulates the stimulating contact(s), and thus does not permit electrical activation of structures posterior to the dura as demonstrated by North et al (3). Enduring pain relief was therefore possible using this style of lead design, provided LFS was diagnosed and the leads were appropriately revised.

CONCLUSION

LFS is a possible barrier for successful SCS therapy, and may present with a variable time course after the insertion of a cylindrical percutaneous electrode. This type of stimulation presents as a progressive, midline discomfort during active stimulation that eventually results in the loss of the ability to utilize SCS therapy. Replacement of percutaneous cylindrical leads with paddle style electrodes is typically a successful recovery option for eliminating LFS and restoring the benefit of SCS therapy.

REFERENCES

- Hoppenstein R. Percutaneous implantation of chronic spinal cord electrode for control of intractable pain, preliminary report. *Surg Neurol* 1975; 4:195-198.
- Stuijk JJ, Holsheimer J. Transverse tripolar spinal cord stimulation: Theoretical performance of a dual channel system. *Med & Biol Eng Comput* 1996; 34:273-279.
- North RB, Lanning A, Hessels R, Cutchis PN. Spinal cord stimulation with percutaneous and plate electrodes: Side effects and quantitative comparisons. *Neurosurg Focus* 1997; 2:e3.
- Yong-Hing K, Reilly J, Kirkaldy-Willis WH. The ligamentum flavum. *Spine* 1976; 1:226-234.
- Rhalmi S, Yahia L, Newman N, Isler M. Immunohistochemical study of the nerves in lumbar spine ligaments. *Spine* 1993; 18:264-267.
- Ashron IK, Ashron A, Gibson SJ, et al Polak JM, Jaffray DC, Eisenstein SM. Morphological basis for low back pain: The demonstration of nerve fibers and neuropeptides in the lumbar facet joint capsule but not in the ligamentum flavum. *J Orthop Res* 1992; 12:72-78.
- Korkala O, Gronblad M, Liesi P, Karaharju E. Immunohistochemical demonstration of nociceptors in the ligamentous structures of the lumbar spine. *Spine* 1985; 10:156-157.
- Vandenabeele F, Creemers J, Lambrichts I, Robberechts W. Fine structure of vesiculated nerve profiles in the lumbar facet joint. *J Anat* 1995; 187:681-692.
- Kirby MC, Sikoryn TA, Hukins DWL, Aspden RM. Structure and mechanical properties of the longitudinal ligaments and ligamentum flavum of the spine. *J Biomed Eng* 1989; 11:192-196.
- Bucknill AT, Coward K, Plumpton C, Tate S, Bountra C, Bich R, Sandison A, Hughes SPF, Anand P. Nerve fibers in lumbar spine structures and injured spinal roots express the sensory neuron-specific sodium channels SNS/PN3 and NaN/SNS2. *Spine* 2002; 27:135-140.
- Bradley K. The technology: The anatomy of a spinal cord and nerve root stimulator: The lead and power source. *Pain Med* 2006; 7:S27-S34.
- Freemont AJ, Peacock TE, Goupille P, Hoyland JA, O'Brien J, Jayson MIV. Nerve ingrowth into diseased intervertebral disc in chronic back pain. *The Lancet* 1997; 350:178-181.
- Peng, B, Wu W, Hou S, Li P, Zhang C, Yang Y. The pathogenesis of discogenic low back pain. *J Bone Joint Surg (Br)* 2005; 87-B:62-67.
- Fawcett DW. *A Text Book of Histology*. W.B. Saunders, Philadelphia, 1986.
- Lee D, Hershey B, Bradley K, Yearwood T. Predicted effects of pulse width programming in spinal cord stimulation: A mathematical modeling study. *Med Biol Comp* 2011; 49:765-774.

