

Retrospective Review

## Clinical Benefits of Femoroplasty: A Nonsurgical Alternative for the Management of Femoral Metastases

Ricardo Plancarte, MD, Jorge Guajardo, MD, Abelardo Meneses-Garcia, MD, Carolina Hernandez-Porras, MD, Faride Chejne-Gomez, MD, Roberto Medina-Santillan, MD, Georgina Galindo-Hueso, MD, Ulises Nieves, MD, and Oscar Cerezo, MSc

From: Instituto Nacional De  
Cancerologia, Mexico City,  
Mexico.

Address Correspondence:  
Ricardo Plancarte, MD  
Instituto Nacional De  
Cancerologia  
Av San Fernando  
22 Col Seccion XVI  
Tlalpan  
Mexico City, DF 14080  
E-mail: planky2@yahoo.com.mx

Disclaimer: There was no external funding in the preparation of this manuscript. Conflict of interest: Each author certifies that he or she, or a member of his or her immediate family, has no commercial association (i.e., consultancies, stock ownership, equity interest, patent/licensing arrangements, etc.) that might pose a conflict of interest in connection with the submitted manuscript.

Manuscript received: 08-14-2012  
Revised manuscript received:  
02-21-2014  
Accepted for publication:  
03-10-2012

Free full manuscript:  
[www.painphysicianjournal.com](http://www.painphysicianjournal.com)

**Background:** Bone metastases occur frequently in advanced cancer. The spine, pelvis, ribs, skull and femur are the most affected sites. It is reported that up to 83% of the patients develop pain at some point of the disease. The patient can also develop fractures and disability, particularly in the femur.

**Objectives:** To evaluate the effectiveness of percutaneous femoroplasty in patients with metastatic osseous disease located in the proximal femur (trochanter, neck, and femoral head).

**Study Design:** A retrospective clinical review, comparing pain status “before vs after” intervention.

**Setting:** National Cancer Institute in Mexico.

**Methods:** We included patients over 18 years old, with mild to severe pain due to metastasis in the proximal femur (trochanter, neck, or head), or with a high risk of fracture according to Mirels scale (> 8 points) or severe osteoporosis according to the World Health Organization (a Karnofsky score more than 50%). Exclusion criteria were femoral fracture. We recorded the following variables age, sex, type of neoplasm, concomitant therapy,

We used the Karnofsky functionality scale, the VAS pain intensity assessment, the “Mayo Clinic” scale to measure improved functionality, and the European Organisation for Research and Treatment of Cancer Quality of Life Questionnaire Core 15 Palliative (EORTC QLQ-C 15-PAL) (Spanish version) questionnaires. Follow-up was performed at 7 days, one month after femoroplasty, and during the individual outpatient that lasted one year on average.

**Results:** Eighty subjects were enrolled. Seventy-three percent were women. The most frequent tumors were breast (46.3%), followed by multiple myeloma (18.7%). All patients had a decrease in the intensity of pain, analgesic consumption, and improved quality of life, at 7 and 30 days after the intervention. There were no complications with serious consequences. Two participants experienced polymethylmethacrylate (PMMA) leakage, without clinical or functional impact. In 4 patients, the needle was occluded during the filling process and we had to place another biopsy needle through the same entry site to finish the injection process.

**Limitations:** The sample was a single group of patients evaluated before and after the femoroplasty. We did not include a control group.

**Conclusion:** The results of the current report suggest that femoroplasty, a percutaneous cement placement analogous to a vertebroplasty, might be a therapeutic option for patients with metastatic bone disease of the proximal femur, providing the patient an analgesic reduction and a better quality of life.

**Key words:** Femoroplasty, bone metastases, cancer, pain, bone pain

**Pain Physician 2014; 17:227-234**

**C**ancer metastasis is the most common cause of bone cancer. After the lung and the liver, bone is the most affected system in the human body for metastases, and about 50% of all patients diagnosed with cancer will develop metastases (1,2). Due to the increased incidence of cancer throughout the world and the increased life expectancy of these patients, there has been an increased incidence of metastatic bone disease (3 – 6). Bone metastases can cause pain and disability, in addition to affecting aspects of the quality of life of patients (7 – 9). The most common sites of bone metastasis are the spine level, ribs, pelvis, and femur. Half of the femur metastatic lesions are located in the femoral neck region; this produces a high risk of pathological fractures, especially of the femoral neck (50%), subtrochanteric region (30%), and intertrochanteric region (20%) (10,11). Osteolytic lesions are commonly found in metastatic disease and are frequently associated with fractures and hypercalcemia (12-14).

Due to the advances in cancer treatments (external beam radiation therapy, bisphosphonates, chemotherapy, and the use of strontium), patients with metastatic disease have a higher survival rate and better functionality. However, with the reported high rate of decline in the ossification of pathological fractures, surgical fixation could become a great challenge for the surgeon. These surgical treatments (internal fixation and/or total hip replacement) (15-18) affect the quality of life and can predispose the patient to require more health care. Therefore, new options for metastatic femoral disease have to be developed (19,20).

## **OBJECTIVES**

We sought to analyze the clinical effectiveness of percutaneous cementoplasty (femoroplasty), evaluating pain relief, analgesic consumption, and quality of life (QoL) in patients with metastatic osseous disease located in the proximal femur (trochanter, neck, and femoral head).

## **METHODS**

A follow-up clinical review, comparing “before vs after” status, was carried out between January 2006 and September 2011. The study was approved by the Ethical Committee of the National Institute of Cancer in Mexico. The sample comprised 80 patients over 18 years old. Inclusion criteria were moderate to severe pain rated 5 or more on the 10 point visual analogue scale (VAS) (21), due to metastasis in the proximal femur (trochan-

ter, neck, or head) or a high risk of fracture according to Mirels scale (22) (> 8 points) or severe osteoporosis according to the WHO (23) and a Karnofsky score (24) of more than 50%. Osseous metastatic disease was diagnosed by pelvis radiography and pelvic computed tomography (CT). Exclusion criteria were femoral fracture or image by CT demonstrating loss of the cortical bone that could predispose to polymethylmetacrylate (PMMC) leak, patients with coagulation disorders, and those who were not eligible for interventional procedures after an anesthetic and cardiology pre-assessment. We recorded the following variables: age, gender, type of neoplasm, concomitant therapy (chemotherapy and/or radiotherapy), densitometric values (T and Z score), Karnofsky functionality scale, pain intensity measure assessed by VAS, improved functionality using the Mayo Clinic scale (25), and European Organisation for Research and Treatment of Cancer Quality of Life Questionnaire Core 15 Palliative (EORTC QLQ-C15-PAL) (Spanish version) (26).

The primary outcome was clinical effectiveness measured by pain relief, analgesic consumption, and QoL after percutaneous femoroplasty.

## **Statistical Analysis**

The data were recording in a Microsoft® Excel® 2010 spreadsheet and analyzed using Stata/MP® (Stata Corp LP, College Station, Texas). Mean and standard deviation for quantitative variables and percentages (interquartile ranges) for qualitative variables were reported. To analyze the association between the main results of clinical effectiveness (pain palliation by VAS, functionality with the Mayo Clinic scale) at different time points a generalized linear model with ANOVA repeated measures was made.

The measurements (VAS, Mayo Clinic scale, and EORTC QLQ-C15-PAL) were made at baseline, and after the procedure at 7 days and one month by personnel qualified to collect such information. The patients were assessed from the time the intervention was made (femoroplasty) up to the appearance of a negative effect in health (recurrence of pain in the proximal femur, reduced functionality, or the presence of pathologic fracture) through a Kaplan – Meier survival curve. Given the clinical relevance of the disease (metastatic disease), a maximum 12-month follow-up was performed.

## **Procedure**

The procedure was performed in the angiography room under fluoroscopic control. Prophylactic second

generation cephalosporin was given to all patients. Through a nasal catheter, 2 – 4 L of oxygen was administered and sedation was provided with a bolus of fentanyl, propofol, and/or midazolam. Patients were monitored with pulse oximetry, electrocardiogram, and noninvasive blood pressure.

The patients were placed in a lateral decubitus position with the affected limb at the top with slight flexion of the hip. The area was prepared with antiseptic solution and surgical drapes were placed around the area. Then, the fluoroscopic arc was angled to create a tunnel vision appreciating an oval or circular figure from the femoral neck at an angle of 20 to 30 degrees caudal–cephalic tilt to align and visualize the femoral neck with the femoral head (Fig. 1).

The area was infiltrated with local anesthetic and two 22-gauge spinal needles were placed, the first one lateral to the greater trochanter of the femur and the other one just above the junction of minor trochanter and femoral neck as a reference. Then an 11-gauge biopsy bone needle was aimed between the reference needles, directing the tip of the needle to the center of the femoral head (Fig. 2 A). The biopsy needle

was advanced slowly, controlling the progress with lateral fluoroscopic views until the needle tip was at the junction of the anterior and middle third of the femoral head. Venography was performed with the administration 3 mL of nonionic contrast medium to identify the vascular drainage of the tumor, so that if the tip of the needle was localized in the main tumor drainage, we could move it forward or withdraw it a few millimeters.

Augmentation was conducted using PMMA Stryker® radiopaque bone cement with tobramycin, with the following characteristics: intermediate polymerization and high exothermic reaction, which was injected manually. The consistency of the PMMA administered was “toothpaste.” Its administration was visualized by lateral, anteroposterior, and oblique fluoroscopic projections (Fig. 3). The biopsy needle was slowly removed while the cement was injected until the needle was out of the bone, leaving a continuously filled canal. The amount of PMMA needed depended on the metastatic bone defect and the femoral head size. The application was stopped when the fluoroscopic image showed filling with PMMA at the proximal femur, associated with

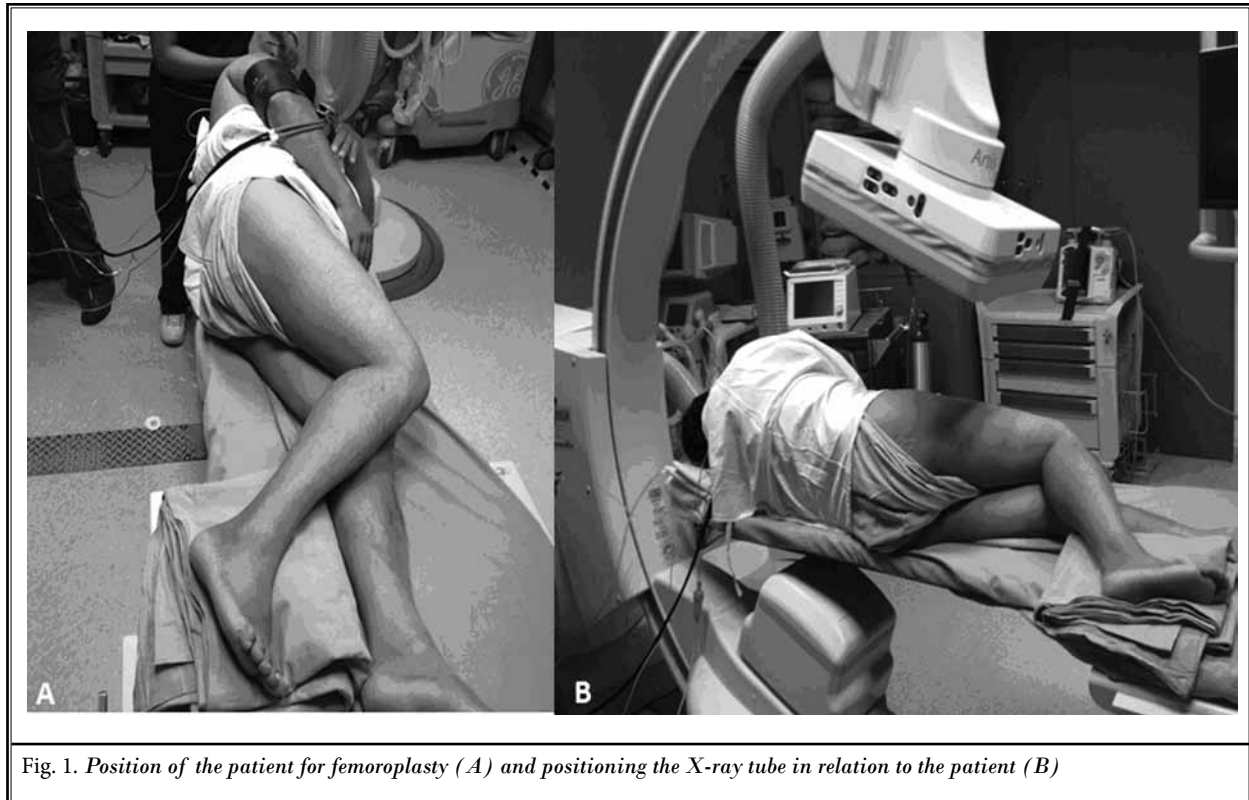


Fig. 1. Position of the patient for femoroplasty (A) and positioning the X-ray tube in relation to the patient (B)

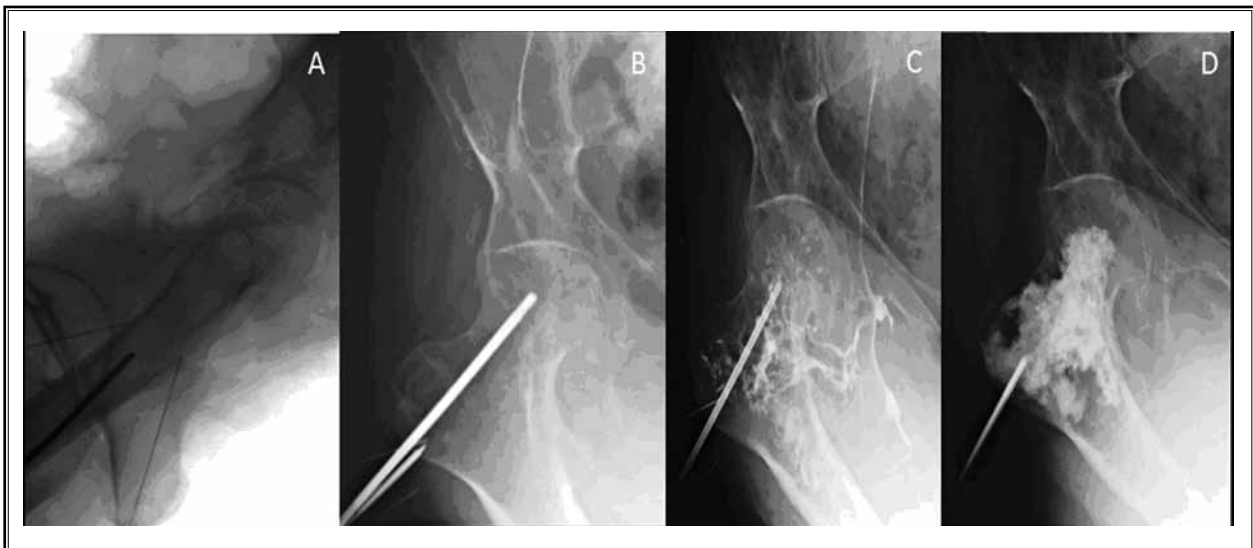

Fig. 2. Needle placement for femoroplasty. Placement of the needle (A), location end (B), venography (C) filling with PMMA (D).

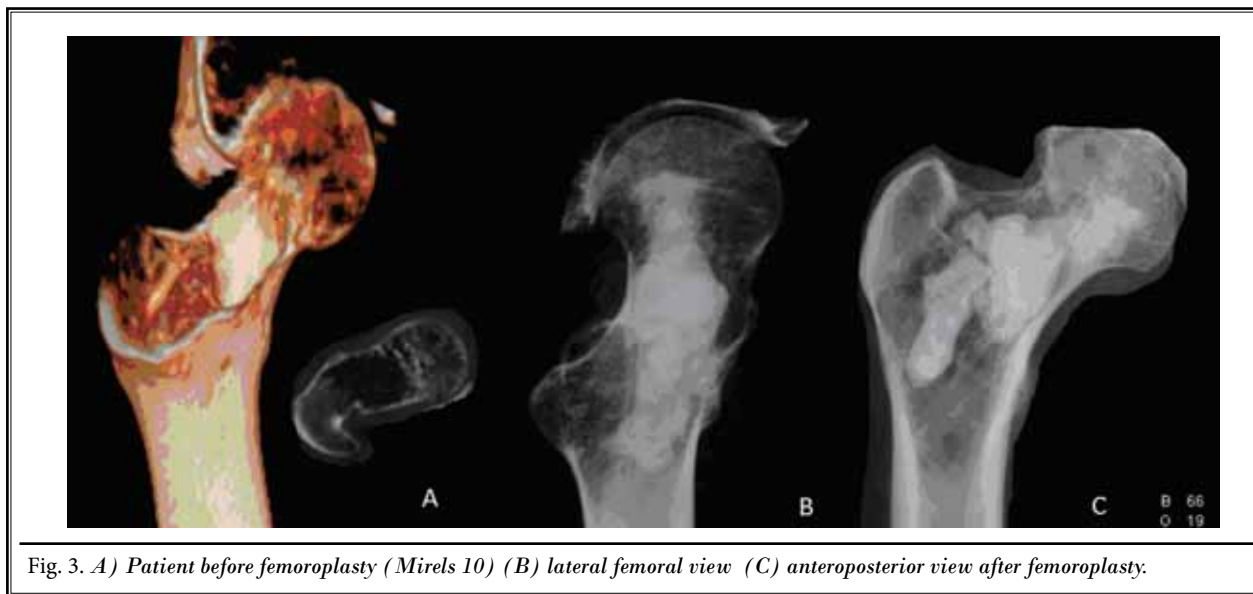


Fig. 3. A) Patient before femoroplasty (Mirels 10) (B) lateral femoral view (C) anteroposterior view after femoroplasty.

a raise of pressure while injecting the material, and/or when the PMMA approached the site of insertion of the needle or the cortical bone.

## RESULTS

We collected information from 80 patients, 59 women and 21 men (73.8% and 26.2%, respectively). Breast cancer was the most frequent tumor in the study

population at 46.3% of the patients, followed by 18.7% with multiple myeloma. The average Mirels scale was  $9.8 \pm 1.8$ , average VAS before the procedure was  $5.3 \pm 1.8$ , and the Karnofsky scale was  $69.5 \pm 9.3$ . At 7 and 30 days, we found that both VAS and Karnofsky had improved, showing a statistically significant difference ( $P < 0.001$ ) (Table 1). The analgesic consumption (acetaminophen, morphine, or tramadol) was significantly lower 30 days

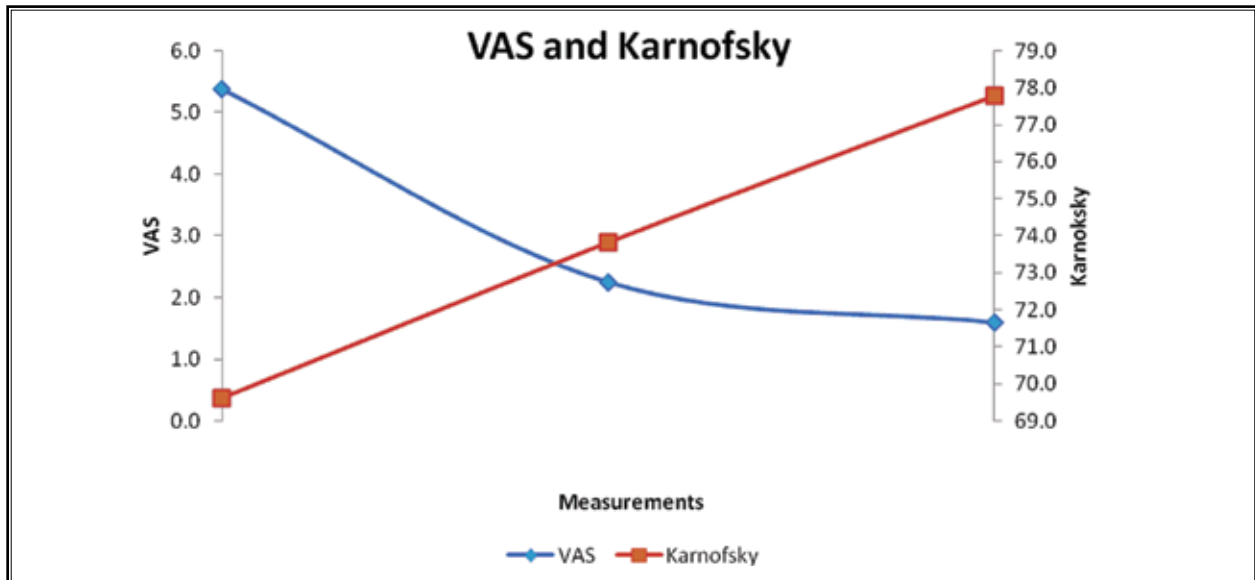


Table 1. VAS and Karnofsky performance.

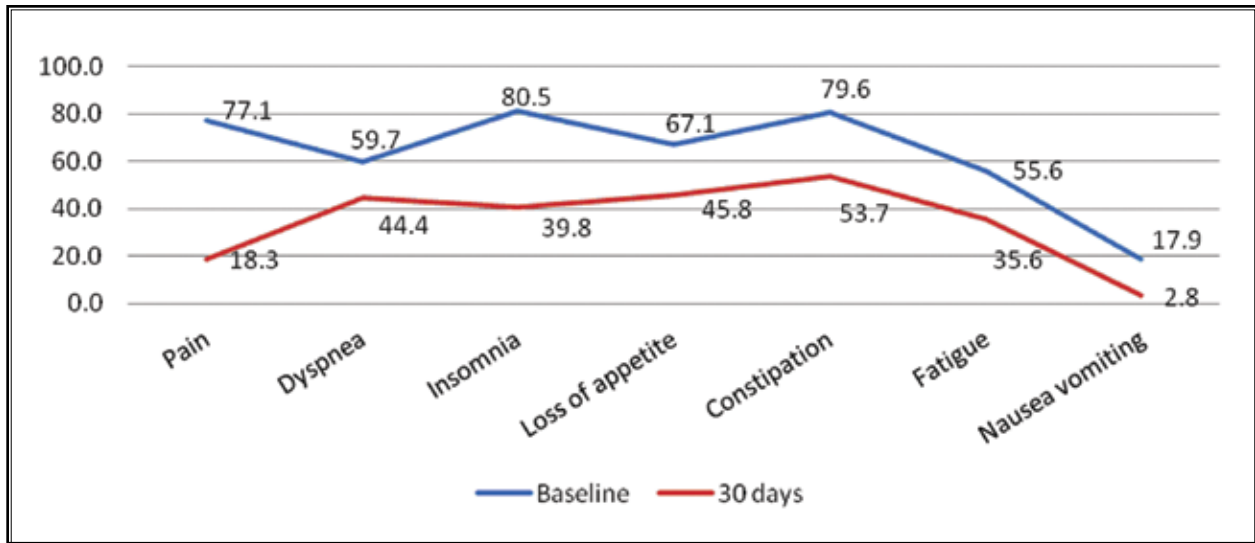


Table 2. EORTC QLQ-C15-PAL symptoms performance.

after the femoroplasty. Like pain, other variables such as dyspnea, insomnia, loss of appetite, constipation, fatigue, nausea, and vomiting showed a significant reduction after femoroplasty ( $P < 0.001$ ) (Table 2).

The EORTC QLQ-C15-PAL also showed a statistically significant improvement in the functional scales, such as physical, emotional, and the overall QoL, when we compared the results of the scales before the intervention and 30 days after it (Table 3). The median overall survival was 13

months (Table 4). The average follow-up was 12 months for prostate cancer and 18 months for breast cancer (Table 5).

### Complications

In one case, we observed slight leakage of PMMA through the retrochanteric area that could be explained by the vascularity of the large tumor. There was no need for extraction and it did not cause any pain or changes in functionality. Another patient had leakage

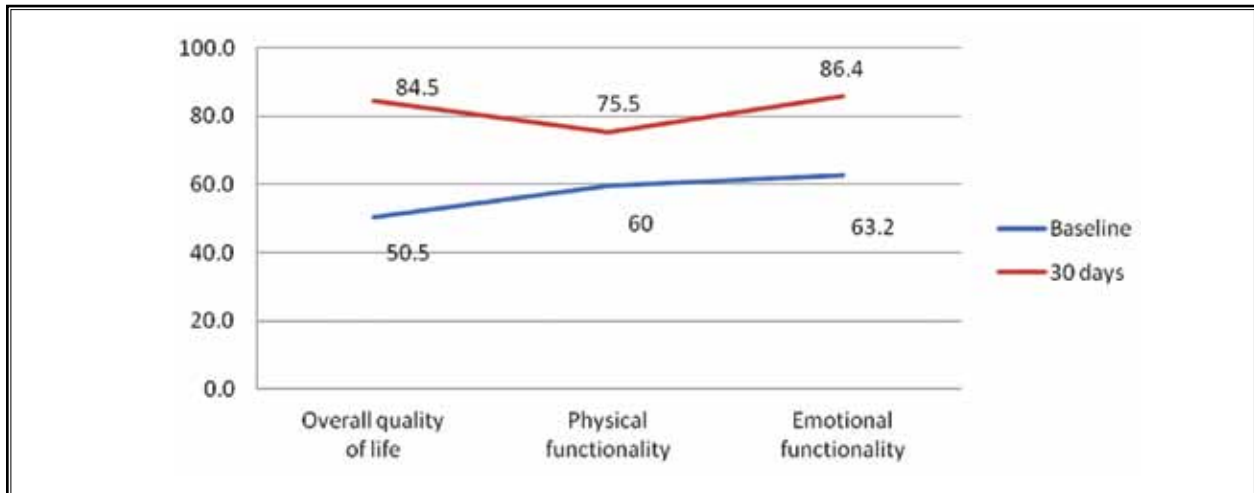


Table 3. EORTC QLQ-C15-PAL Functionality performance.

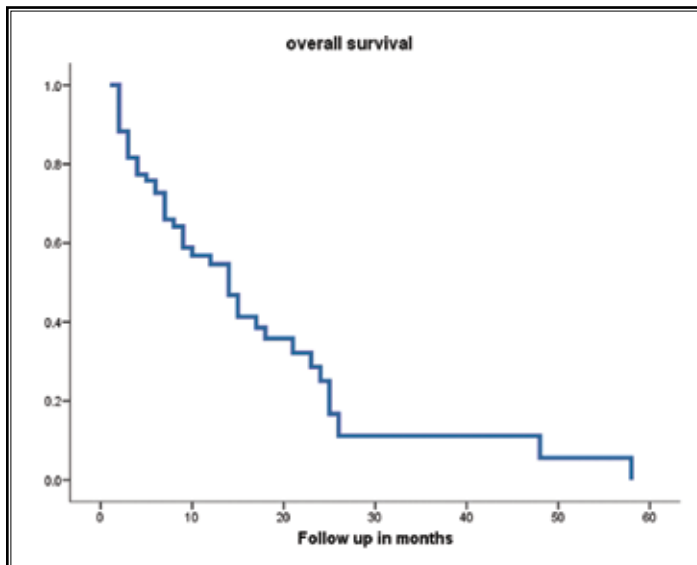


Table 4. Overall survival curve.

to soft tissue from the biopsy needle entrance, but during the follow-up, the patient did not present any symptoms.

### Discussion

Femoroplasty appears to be an effective technique for the treatment of metastatic bone disease at the proximal femur. All patients showed a significant reduction in VAS; consequently, analgesic and adjuvant consumption was decreased.

It is important to mention that all patients received specific oncologic treatment such as chemotherapy, radiotherapy, and

bisphosphonates. Several studies (27) have proven that this type of therapy can provide the patient a better QoL and improve pain control; however, the onset of palliation can require up to 2 weeks (28,29). In contrast, the benefits in pain score and other evaluated measurements were seen at the first week after femoroplasty.

This novel technique also demonstrated an improvement in the QoL, assessed with the validated EORTC QLQ-C15. Increases in the score of functional scales (physical, emotional, and role), and other symptoms (except dyspnea), can be related to the reduction in opioid consumption, which can be directly associated to the procedure.

To our knowledge, femoroplasty has only been reported recently as experimental in human cadaveric femora (30); it results in a prophylactic reinforcement of osteoporotic proximal femur that can protect the proximal femur against osteoporotic fractures. The findings of this study suggest that femoroplasty could give patients a decreased risk of femoral fracture.

Surgical procedures can be dangerous for certain subsets of patients and the undesirable effects may outweigh the clinical benefits for those with a short life expectancy. Improvements in pain and walking ability are essential for enhancing patient QoL, especially for those with good performance status

and anticipated lengthier survival. Our population was limited to patients with metastatic osseous disease, so the results cannot be generalized to other type of illnesses.

**CONCLUSION**

In conclusion, the results of the current study suggest that femoroplasty, a percutaneous cement placement analogous to a vertebroplasty, might be a therapeutic option for patients with metastatic bone disease at the proximal femur, providing the patient an analgesic reduction and a better QoL. Further studies are needed to evaluate its reproducibility.

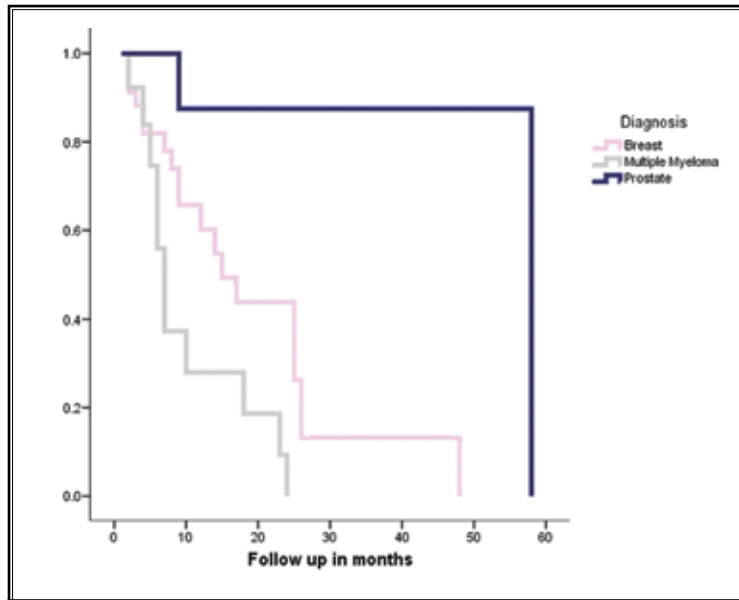


Table 5. Survival curve for tumor.

**REFERENCES**

- Malawer M, Delaney T. Treatment of metastatic cancer to bone. In: *Cancer: Principles and Practice of Oncology*. 3th edition. JB Lippincott, Philadelphia, 1989, pp 2310-2332.
- Coleman RE. Bone cancer in 2011: Prevention and treatment of bone metastases. *Nat Rev Clin Oncol* 2011; 20:76-78.
- Mercadante S. Malignant bone pain: Pathophysiology and treatment. *Pain* 1997; 69:1-18.
- Coleman R, Rubens R. The clinical course of bone metastases in breast cancer. *Br J Cancer* 1987; 77:336-340.
- Clines GA, Guise TA. Molecular mechanisms and treatment of bone metastasis. *Expert Rev Mol Med* 2008; 10:1-16.
- Sim FH. Metastatic bone disease of the pelvis and femur. *Instr Course Lect* 1992; 41:317-327.
- Clines GA, Guise TA. Molecular mechanisms and treatment of bone metastasis. *Expert Rev Mol Med* 2008; 10:1-16.
- Harvey HA, Cream LR. Biology of bone metastases: Causes and consequences. *Clin Breast Cancer* 2007; 7:57-513.
- Manabe J, Kawaguchi N, Matsumoto S, Tanizawa T. Surgical treatment of bone metastasis: Indications and outcomes. *Int J Clin Oncol* 2005; 10:103-111.
- Nazario J, Tam AL. Ablation of bone metastases. *Surg Oncol Clin N Am* 2011; 20:355-368.
- Lane JM, Scalco TP, Zoland SG. Treatment of pathologic fractures of the hip by endoprosthetic replacement. *J Bone Joint Surg Am* 1980; 62:954-959.
- Ruggieri P, Mavrogenis A, Casadei R, Errani C, Angelini A, Calabro T, Pala E, Mercuri M. Protocol of surgical treatment of long bone pathological fractures. *Injury* 2010; 41:1161-1167.
- Loftus LS, Edwards-Bennett S, Sokol GH. Systemic therapy for bone metastases. *Cancer Control* 2012; 19:145-153.
- Hsiang-Hsuan Michael Yu, ScM, Ya-Yu Tsai, Sarah E. Hoffe. Overview of diagnosis and management of metastatic disease to bone. *Cancer Control* 2012; 19:284-291.
- Mundy GR. Metastasis to bone: Causes, consequences and therapeutic opportunities. *Nat Rev Cancer* 2002; 2:584-593.
- Böhm P, Huber J. The surgical treatment of bony metastases of the spine and limbs. *J Bone Joint Surg* 2002; 84:521-529.
- Buggay D, Jaffe K. Metastatic bone tumors of the pelvis and lower extremity. *J Surg Orthop Adv* 2003; 12:192-199.
- Nakamura N, Shikama N, Wada H, Harada H, Nozaki M, Nagakura H, Tago M, Oguchi M, Uchida N. Patterns of practice in palliative radiotherapy for painful bone metastases: A survey in Japan. *Int J Radiat Oncol Biol Phys* 2012; 83:E117-E120.
- Hunt KJ, Gollogly S, Randall RL. Surgical fixation of pathologic fractures: An evaluation of evolving treatment methods. *Bull Hosp Jt Dis* 2006; 63:77-82.
- Plancarte R, Guajardo J, Cerezo O, Chejne F, Gómez G, Meneses G, Armas P, Saldaña G, Medina R. Femoroplasty: A new option for femur metastasis. *Pain Practice* 2013; 13:409-413.
- Wewers ME, Lowe NK. A critical review of visual analogue scales in the measurement of clinical phenomena. *Res Nurs Health* 1990; 13:227-236.
- Mirels H. Metastatic disease in long bones: A proposed scoring system for diagnosing impending pathologic fractures. *Clin Orthop* 1989; 249:256-264.
- Prevention and management of osteoporosis. *World Health Organ Tech Rep Ser* 2003; 921:1-164.
- Yates JW, Chalmer B, McKegney FP. Evaluation of patients with advanced cancer using the Karnofsky performance status. *Cancer* 1980; 45:2220-2224.
- Kavanagh B, Ilstrup D, Fitzgerald R. Revision total hip arthroplasty. *J Bone Joint Surg Am* 1985; 67:517-526.

26. Suárez-del-Real Y, Allende-Pérez S, Alférez-Mancera A, Rodríguez R, Jiménez-Toxtle S, Mohar A, Oñate-Ocaña L. Validation of the Mexican-Spanish version of the EORTC QLQ-C15-PAL questionnaire for the evaluation of health related quality of life in patients on palliative care. *Psychooncology* 2011; 20:889-896.
27. Smith H. Painful osseous metastases. *Pain Physician* 2011; 14:E373-E405.
28. Yoon MH, Kim WM, Lee HG, Choi JI, Kim YO, Song JA. Analgesic effect of intrathecal ginsenosides in a murine bone cancer pain. *Korean J Pain* 2010; 23:230-235.
29. Gill JB, Kuper M, Chin PC, Zhang Y, Schutt R Jr. Comparing pain reduction following kyphoplasty and vertebroplasty for osteoporotic vertebral compression fractures. *Pain Physician* 2007; 10:583-590.
30. Beckmann J, Springorum R, Vettorazzi E, Bachmeier E, Lüring C, Tingart M, Püschel K, Stark O, Grifka J, Gehrke T, Amling M, Gebauer M. Fracture prevention by femoroplasty cement augmentation of the proximal femur. *J Orthop Res* 2011; 29:1753-1758.