Pain Physician. 2004;7:319-322, ISSN 1533-3159

A Technical Report

A Novel Technique for Pudendal Nerve Block

Salahadin Abdi, MD, PhD, Pam Shenouda, MD, Nilesh Patel, MD, Bhupinder Saini, MD, Yogendra Bharat, MD, and Octavio Calvillo, MD

Pudendal nerve block is performed to confirm the diagnosis of pudendal neuralgia. Many physicians and patients are hesitant to pursue diagnostic nerve blocks to confirm the diagnosis of pudendal neuralgia secondary to significant patient discomfort, the need for special equipment, and the risk in the traditionally described approach.

Objective: To describe a novel technique for pudendal nerve block with minimal risk and decreased patient discomfort.

Description of the Technique: With the patient in the prone position, the C-arm is projected in the anteroposterior position until the pelvic inlet is visualized. Subsequently, the ischial spine is highlighted by 5 to 15 degree ipsilateral oblique angulation of the fluoroscope. A 25-gauge 3.5 cm needle is advanced to the tip of the ischial spine where the pudendal nerve transiently leaves the pelvis. The pudendal nerve block is performed at this level.

Conclusion: We described a new and novel technique to block pudendal nerve under fluoroscopic visualization safely with increased patient comfort.

Keywords: Pudendal neuralgia, pudendal nerve block, piriformis muscle, fluoroscopy

Despite advances in the understanding of pain mechanisms, chronic pelvic pain continues to be a diagnostic and therapeutic dilemma for physicians (1-5). Patients with chronic neuropathic pelvic pain for which no etiology could be found despite comprehensive diagnostic testing were originally described as suffering from "psychosomatic vulvovaginitis" by Dodson and Friedrich (6) in the late 1970s. Turner and Marinoff (7) later described this clinical presentation as consistent with pudendal neuralgia. Consequently, with suspicion of pudendal neuralgia, a pudendal nerve block may be performed to confirm the diagnosis.

Many physicians and patients are hesitant to pursue diagnostic nerve blocks secondary to patient discomfort, the need for special equipment, and the associated risks with the traditionally described approach (8). Traditional descriptions of this technique involve placing a patient in the lithotomy position. In a female patient, the ischial spine is palpated through the vaginal wall, and the physician uses a Koback needle or an Iowa trumpet and guides the needle along the course of the finger (Fig. 1B). Ten to fifteen milliliters of local anesthetic is then injected just posterior to the attachment of the sacrococcygeal ligament to the ischial spine. In a male patient, the ischial spine is palpated through the rectum, and the needle is inserted transperineally (8).

Several problems are associated with these traditional approaches. First, there is the possibility of a high level of patient discomfort associated with the procedure. Second, many pain clinics are not equipped to place patients easily in the lithotomy position. Third is the danger involved for the patient, as this is a blind technique in a vascular region near the bowel and bladder. Finally, danger is involved for physicians performing this procedure, as they direct a needle, by palpation, along the course of their fingers to palpate appropriate landmarks. This places such physicians at high risk for accidentally puncturing their fingers with the needle.

Calvillo et al (9) recognized the disadvantages of the traditional approach to the pudendal nerve block and described a computed tomography–guided approach. Their technique allows for minimal patient discomfort, negates the need for the lithotomy position, and probably increases patient and physician safety. However, the majority of pain clinics are not equipped with a computed tomography (CT) scanner and thus would have to send their patients to have the procedure performed in a radiology suite. This increases patients' travel time and time absent from work and takes the procedure away from the patient's primary pain physician.

A fluoroscope-guided approach to a pudendal nerve block has not been described in the literature. This is important, because most interventional pain clinics are equipped with a fluoroscopy machine. Performing pudendal nerve block under fluoroscopy has the advantages of the CT-guided approach and yet allows the performance of the procedure in any pain clinic that has fluoroscopy available.

Thus, we sought to describe a novel approach to the pudendal nerve block that may be both more acceptable to patients and safer.

Anatomy

The pudendal nerve arises from the sacral plexus. It is formed from contributions from the second, third, and fourth

From Department of Anesthesiology, Perioperative Medicine and Pain Management, UM/Jackson Memorial Hospital, Miami, Florida, Department of Anesthesia and Crictical Care, Massachusetts General Hospital, Advanced Pain Management Center, Milwaukee, Wisconsin, and Baylor College of Medicine, Houston, Texas. ddress Correspondence: Salahadin Abdi, MD, PhD, Department of Anesthesiology, Perioperative Medicine, and Pain Management, UM/Jackson Memorial Hospital, 1611 N.W. 12th Ave, C-301, Miami, FL 33136. E-mail: sabdi@med.miami.edu
Funding: There was no external funding in preparation of this manuscript.
Conflict of Interest: None
Acknowledgement: Manuscript received on 3/31/04. Revision submitted on 5/25/04. Accepted for publication on 6/4/04.

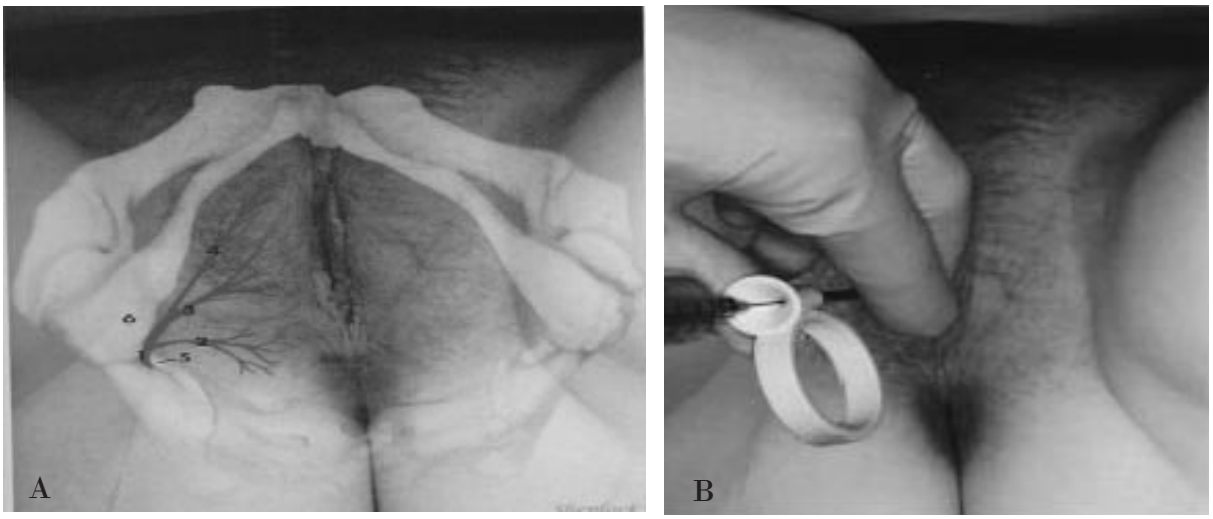

Fig 1a. *Distributions of the branches of the pudendal nerve and pelvis superimposed over the surface anatomy. 1: pudendal nerve; 2: inferior rectal nerve; 3: perineal nerve; 4: dorsal nerve of the clitoris; 5: ischial spine; 6: ischial tuberosity.* b. *Blockade of the pudendal nerve via the transvaginal approach.*
(Reproduced with permission [20])

sacral nerve roots. The pudendal nerve courses through the superior aspect of the pelvis anteriorly and inferiorly, exiting through the greater sciatic foramina just inferior to the piriformis muscle. At that point, the nerve crosses posterior to the attachment of the ischial spine and the sacrococcygeal ligament, anterior to the sacrotuberous ligament. It then reenters the pelvis through the lesser sciatic foramina. The nerve courses posteriorly and inferiorly through Alcock's canal, eventually dividing into three branches: the inferior rectal nerve, the perineal nerve, and the dorsal nerve of the penis or clitoris (Fig. 1A).

The inferior rectal nerve provides sensation to the distal aspect of the anal canal and to the perianal skin. It also provides motor innervation to the external anal sphincter. The perineal nerve provides sensation to the perineum and the ipsilateral posterior surface of the scrotum or the labia majora. It also provides motor innervations to the superficial and deep transverse perineal muscles, the bulbospongiosus, the ischiocavernosus, the sphincter urethrae, and the levator ani muscles. The final branch of the pudendal nerve—the dorsal nerve of the penis or clitoris—supplies sensation to the skin and deeper structures of the penis or clitoris (10). As the branches of the pudendal nerve run relatively superficially through the pelvis, they become increasingly vulnerable to injury.

Pathophysiology

Insults to the pudendal nerve tend to be unilateral. The most common pudendal nerve injury occurs during childbirth. This "obstetrical neuropathy" has been reported to be both a temporary and a permanent cause of morbidity (11, 12). Other causes of injury to the pudendal nerve include traumatic injury leading to fracture of the ischial spine; entrapment of the nerve as it courses beside the ischial spine between the sacrotuberous and sacrococcygeal ligaments (13); compression of the nerve as it courses through Alcock's canal (14); infectious damage to the nerve's structure (15, 16); and iatrogenic injury as the nerve is penetrated with a large, dull needle during pudendal nerve blocks or as damage to the nerve or its blood supply during any type of surgical interventions requiring exploration of the pelvis.

Bilateral pudendal nerve injury is relatively rare. The mechanism of bilateral injury usually involves a patient's falling and straddling a blunt object, such as a bicycle seat (17) or an equestrian saddle (18).

Clinical Presentation

Patients with pudendal neuralgia tend to describe neuropathic pain symptoms in the nerve's distribution. Common complaints include burning pain, paresthesias, hyperalgesia, hypesthesia, and intermittent lancinating pain. This pain can disrupt an affected patients' ability to carry out normal functions of day-to-day living, including being seated comfortably and engaging in sexual intercourse. Patients may also complain of associated motor deficits, including lack of control of their external anal sphincter and periurethral and perineal musculature (19).

Diagnosing pudendal neuropathy requires a high index of suspicion while obtaining a patient's medical history and performing a physical examination. In the event of trauma, one may suspect pudendal nerve injury after seeing a fracture of the ischial spine. On physical examination, scar tissue may be palpated along the course of the nerve. Ultimately, the diagnosis can be made by performing a pudendal nerve block.

Description of a New Technique

The patient is placed in the prone position, and the gluteal region is prepared and draped. Then a C-arm fluoroscope is projected in the anterior-posterior position with the patient in the prone posi-

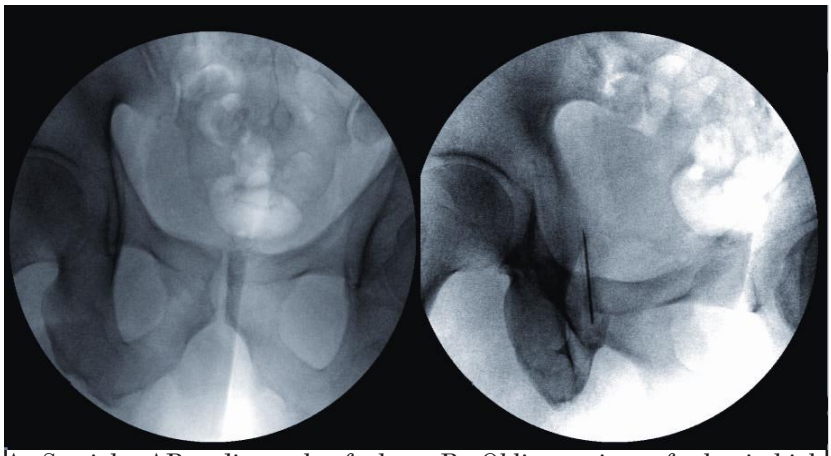

A. Straight AP radiograph of the pelvic bones.

B. Oblique view of the ischial spine. Note that the tip of the needle is at the falciform process of the ischial bone.

Fig 2. *Pudendal nerve block with our new approach.*

tion (at the level of the two femoral heads) until the pelvic inlet is visualized. The falciform process (the ischial spine) is then highlighted by 5- to 15-degree ipsilateral oblique angulation of the fluoroscope. A 25-gauge 3.5 inch needle is advanced to the tip of the ischial spine, where the pudendal nerve transiently leaves the pelvis. At this point, 3 to 4 ml of local anesthetic provides excellent anesthesia in the distribution of the pudendal nerve (Fig. 2).

Discussion

Despite diagnostic and therapeutic advances, patients with deep pelvic and perineal pain continue to pose a significant challenge for the majority of pain clinicians. Pudendal entrapment and neuralgias are implicated in some clinical presentations. Pudendal blockade may provide some hope for these patients. Lately, interest in this block has increased, as CT-guided injection has been described to have good results. Although the usefulness of this block is well known, the appearance of the classical blind approach often dissuades well-meaning physicians from offering the pudendal injection. The readily accessible fluoroscope in most pain clinics motivates physicians to utlize a C-arm guided approach to block the nerve.

Our fluoroscopic technique offers a precise and sublimate approach that should inspire its use when treating patients with pudendal neuralgia. Whenever practical, image-guided injections should supersede the traditional method, as effective pudendal blockade (with a fraction of the dose demanded by the conventional technique) is ensured when image guidance is adopted.

Further research has to be performed on this novel technique. Questions to be answered include the following: Which technique is most successful in isolating and blocking the pudendal nerve? Which technique has the highest rate of complications? Which technique provides the most patient and physician satisfaction? Elucidating the answers to such questions should result in an increased ability to diagnose and treat pudendal neuralgia.

Conclusion

The authors' belief is that the fluoroscopic approach to the pudendal nerve block is safe and effective.

Author Affiliation:

Salahadin Abdi, MD, PhD
Chief of Pain Medicine
Professor of Anesthesiology
JUM/Jackson Memorial Hospital
1611 N.W. 12th Ave. C-301
Miami FL 33136
E-mail: sabdi@med.miami.edu

Pam Shenouda, MD
Massachusetts General Hospital
Department of Anesthesia
32 Fruit Street
Boston, MA 02114

Nilesh Patel, MD
Advanced Pain Management Center
Milwaukee, WI
5900 S. Lake Drive
Cudahy, WI 53110

Bhupinder Saini, MD
Advanced Pain Management Center
5900 S. Lake Drive
Cudahy, WI 53110
E-mail: BSSaini@aol.com

Yogendra Bharat, MD
Advanced Pain Management Center
5900 S. Lake Drive
Cudahy, WI 53110

Octavio Calvillo, MD
Baylor College of Medicine
6550 Fannin Street, Suite 2421
Houston, TX 77030-2748
E-mail: ocalvillo@mysurgeon.com

References

1. Neil ME, Swash M. Chronic perineal pain: An unresolved problem. *JR Soc Med* 1982; 75:96–101.
2. Wesselman U, Bennett AL, Heinberg LJ. The urogenital and rectal pain syndromes. *Pain* 1997; 73:2692–2694.
3. Glazer HI, Romanzi L, Polaneczky M. Pelvic floor muscle surface electromyography. Reliability and clinical predictive validity. *J Reprod Med* 1999; 44:779–782.
4. Egan KJ, Kriegewr JL. Chronic abacterial prostatitis—A urogenital pain syndrome? *Pain* 1997; 69:213–218.
5. Robert R, Labat JJ, Lemur PA et al. Clinical, neurophysiological and therapeutic remarks from anatomic data on the pudendal nerve in some cases of perineal pain. *Chirugie* 1989; 115:515–520.
6. Dodson MG, Friedrich EG Jr. Psychosomatic vulvovaginitis. *Obstet Gynecol* 1978; 51(1):23S–25S.
7. Turner MLC, Marinoff SC. Pudendal neuralgia. *Am J Obstet Gynecol* 1991; 165:1233–1236.
8. Anatomy and technique of pudendal nerve block. In Raj PP (ed). *Chronic Pain Handbook of Regional Anesthesia.* Churchill-Livingstone, New York, 1985.
9. Calvillo O, Ioannis SM, Rockett C. Computed tomography–guided pudendal nerve block. a new diagnostic approach to long-term anoperineal pain: A report of two cases. *Reg Anesth Pain Med* 2000; 25:420–423.
10. McDonald JS and Rapkin AJ. General considerations. In: Loeser JD (ed). Bonica J. *The Management of Pain,* 3rd ed. 2001, pp 1364–1366.
11. Snooks SJ, Henry MM, Swash M. Fecal incontinence due to external sphincter division in childbirth is associated with dam-

age to the innervation of the pelvic floor musculature: A double pathology. *Br J Obstet Gynecol* 1985; 92:824–828.

12. Snooks SJ, Swash M, Henry MM. Risk factors in childbirth causing damage to the pelvic floor innervation. *Int J Colorectal Dis* 1986; 1:20–24.
13. Pisani R, Stubinsky R, Datti R. Entrapment neuropathy of the internal pudendal nerve. Report of two cases. *Scand J Urol Nephrol* 1997; 31:407–410.
14. Tognetti F, Poppi M, Gaist G. Pudendal neuralgia due to solitary neurofibroma. *J Neurosurg* 1982; 56:732–733.
15. Layzer RB, Connant MA. Neuralgia in recurrent herpes simplex. *Arch Neurol* 1974; 31:233–237.
16. Howard EJ. Postherpetic pudendal neuralgia. *JAMA* 1985; 253:2196.
17. Silbert PI, Dunne JW, Edis RH et al. Bicycling induced pudendal nerve pressure neuropathy. *Clin Exp Neurol* 1991; 128: 191–196.
18. McDonald JS and Loeser JD. Pelvic and perineal pain caused by other disorders. In: Loeser JD (ed). Bonica's Management of Pain, 3rd edition, Lippincott Williams & Wilkins, Philadelphia, PA, 2001, pp1462-1472.
19. Bonica J. The Management of Pain, 3rd ed. p 1467.
20. Sheppard R. Pudendal nerve. In: Hahn MB, McQuillan PM, Sheplock GJ. *Regional Anesthesia: An Atlas of Anatomy and Techniques,* 1st ed. Mosby-Year Book, Inc., St. Louis, MO, 1996, pp 267–271.