

Technical Review

## Lumbar Medial Branch Radiofrequency Ablation: Technical Suggestions Based on Emerging Ex-Vivo Evidence

Kevin S. Batti, MD<sup>1</sup>, Joshua B. Lewis, MD, PhD<sup>1</sup>, Ugur Yener, MD<sup>1</sup>, Alan D. Kaye, MD, PhD<sup>2</sup>, and Sayed E. Wahezi, MD<sup>1</sup>

From: <sup>1</sup>Department of Physical Medicine and Rehabilitation, Montefiore Medical Center/Albert Einstein College of Medicine, Bronx, NY; <sup>2</sup>Department of Anesthesiology, Louisiana State University School of Medicine, Shreveport, LA

Address Correspondence:  
Sayed Emal Wahezi, MD  
Department of Physical Medicine and Rehabilitation, Montefiore Medical Center  
1250 Waters Place, Tower #2 8th Floor  
Bronx, NY 10461  
E-mail: swahezi@montefiore.org

Disclaimer: No funding was received to assist with the preparation of this manuscript. Every author has contributed significantly to the paper through personal and active involvement and will accept public liability for the article's content. All data supporting the findings of this study are available within the article.

Conflict of interest: Dr. Sayed E. Wahezi receives research funding from Boston Scientific, Abbott, and Vertos. He is also a consultant for Boston Scientific and a Key Opinion Leader for TENEX. All other authors certify that he or she, or a member of his or her immediate family, has no commercial association (i.e., consultancies, stock ownership, equity interest, patent/licensing arrangements, etc.) that might pose a conflict of interest in connection with the submitted article.

Article received: 03-27-2025  
Revised article received:  
09-03-2025  
Accepted for publication:  
09-18-2025

Free full article:  
[www.painphysicianjournal.com](http://www.painphysicianjournal.com)

**Background:** Facetogenic pain accounts for 5–50% of chronic low back pain (CLBP) cases, and the prevalence of this pain increases with age. Because of poor imaging correlation, the diagnosis is challenging and relies on symptoms, exam findings, and “gold standard” diagnostic blocks, though optimal protocols remain debated. National societies have issued treatment recommendations for the condition, yet controversy persists. The present investigation focuses on medial branch block radiofrequency ablation (RFA) and highlights key factors for optimizing technique to improve patient outcomes.

**Objectives:** To demonstrate proper technique and factors that clinicians should consider to maximize the effectiveness of MBN RFA.

**Study Design:** Development of methodology integrating ex vivo evidence and clinical approach.

**Setting:** An academic healthcare institution

**Methods:** A PubMed review of article published between 2020 and 2025 was performed using the keywords “ex vivo,” “radiofrequency ablation,” and “lesion size.” RFA of medial branch nerves (MBNs) relies on precise anatomical knowledge to ensure proper needle placement. Recent studies have demonstrated that there are multiple factors to consider in MBN RFA. When compared to muscle, adipose reduces lesion size in relation to lower thermal conductivity. Adipose around the needle decreases lesion size, which may explain the reduced efficacy of RFA in obese patients. Commonly used solutions impact lesion dimensions: 2% lidocaine increases lesion width, while iohexol 240 increases length. In addition, a probe's proximity to bone increases lesion size, as poor thermal conductance traps energy in adjacent tissues. Therefore, shape and size can be modified in accordance with medication selection and the active tip's juxtaposition to tissue.

**Limitations:** Despite advancements, significant knowledge gaps remain in understanding the effectiveness of RFA, since most studies focus on tumor ablation rather than neurolysis, and lack in-vivo data. To improve real-world clinical outcomes, future research should evaluate functional outcomes and pain relief in patients undergoing individualized procedures tailored to their unique anatomy.

**Conclusions:** RFA of MBNs is a valuable way to treat axial, facetogenic low back pain. The technique should be optimized to best account for the unique anatomy of each patient and thereby maximize the effectiveness of the procedure.

**Key words:** Radio frequency ablation, medial branch, axial, lumbar, back pain

**Pain Physician 2025; 28:S137-S143**

In the current literature, much controversy surrounds lumbar facet joint pain, including the diagnosis, management strategies, and effectiveness of treatments for the condition. The prevalence of facetogenic back pain varies by report, but is estimated to account for 5–50% of all cases of chronic, axial low back pain cases (1). Certain populations may be at a higher risk of developing pain originating from the zygapophysial joints, and the prevalence for this pain increases with age. Manchikanti et al. (2) found that among individuals with chronic low back pain (CLBP), those aged 65 and older show a 52% prevalence of facetogenic pain, compared to a 30% prevalence in individuals aged 64 and younger. Lumbar trauma may elevate the risk of facet arthropathy, supporting the idea that repetitive stress or trauma to the facet joints may contribute to the development of chronic pain over time. However, diagnostic imaging has been found to have poor correlation for facetogenic pain (2,3). For this reason, the diagnosis of facetogenic pain is typically based on symptoms and exam findings and is confirmed with diagnostic blocks. Yet even the optimal protocols to diagnose facetogenic pain are strongly debated, thus resulting in a lack of consensus (4).

Although national societies have provided recommendations regarding interventional treatments for facetogenic pain, there is still debate regarding the reported effectiveness of the treatment (5-7). The authors submit that the reported controversy is, in part, due to differences of in adipose content among patients' neighboring medial branch nerves (MBNs) {AU: Please see that this edit retains your intended meaning;} and practitioner performance variability. We herein provide a review of medial branch block radiofrequency and highlight factors that may be implicated in optimizing the technique, based on recent research. Our goal in the present investigation is not to highlight the arguments presented by various research groups, but to instead focus on aspects that clinicians should consider when performing MBN radiofrequency ablation (RFA). These aspects are a blend of high efficacy within controlled trials and effectiveness noted in pragmatic, clinical settings.

## PROCEDURAL CONSIDERATIONS

### Anatomical Considerations

Lumbar facet joints are created by posterolateral articulations between adjacent vertebral arches. Each of these joints is a true synovial joint, containing ap-

proximately 1.0-2.0 mL of synovial fluid and enclosed within a fibrous capsule (5). The anterior surface of the capsule is supported by the ligamentum flavum, while fibers of the multifidus strengthen the posterior surface (1).

Innervation of the facet joint stems from the dorsal rami of the spinal cord. Each dorsal ramus divides into medial and lateral branches as it exits the intervertebral foramen. MBNs provide innervation to the facet joint at the same spinal level and from the level above (1). For example, the L3/L4 facet joint receives innervation from the L2 and L3 MBNs. In other words, each MBN innervates the facet joint at its own level and the level below it.

At the L1-L4 levels, the MBN courses along the inferior pole of the superior articular process, behind the mamillo-accessory ligament (MAL), which anchors the MBN to the vertebrae (8-10) (Fig. 1). The L5 MBN travels a different course than other lumbar MBNs do. The L5 dorsal ramus travels over the medial sacral ala, at the base of the S1 superior articular process (SAP) (1,11) (Fig. 2).

### Technical Considerations

Lumbar facet RFA requires anatomical knowledge and radiographic recognition to guide placement of the needle in the recess created by the superior articular process (SAP) and transverse process (TP). MBNs reside at the base of the SAP and course medio-inferiorly to the superior medial pole of the TP. Traditional recommendations advise that probes be placed parallel to MBN to maximize the lesioning effect on the MBN (2,6). However, the recess is difficult to target because of anatomical variability and the fluoroscopic limitation of curvilinear evaluation. The MBNs course over the base of the SAPs; therefore, the authors submit that needle placement should target this location because it is a flat surface that is more reliably identified with fluoroscopy (Fig. 3). Before the ablation of the nerve, electrical stimulation testing should be performed to ensure proper electrode placement while also minimizing involvement of nontargeted structures. Motor testing ensures that the probe is not in close proximity to a ventral ramus or spinal nerve, preventing a patient from potentially being paralyzed. Sensory testing ensures placement of the probe at the intended MBN prior to ablation. However, it is known that the L4 and L5 MBNs electrical stimulation verification are unreliable due to a myriad of anatomical features

common to this location, including multifidus atrophy, excessive lordosis, and facet arthropathy (12) (Table 1).

**Factors Affecting Lesion Size**

The presence of adipose tissue near the intended needle placement location has been shown to modu-

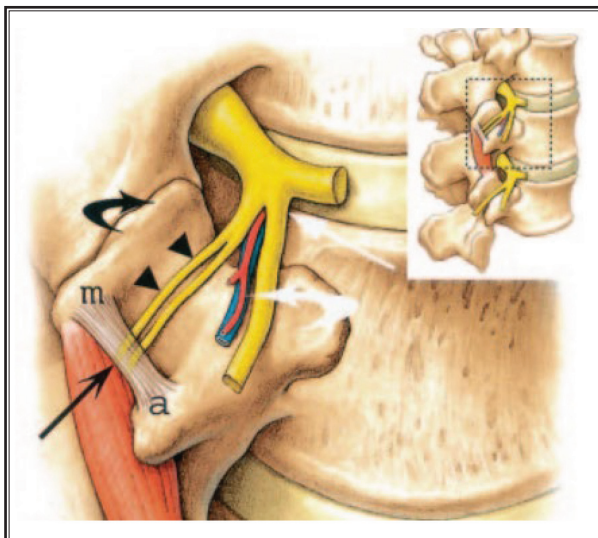


Fig. 1. The MBN (pair of arrows) is shown coursing under the mamillary ligament (long black arrow), which is attached to the mamillary process (m) and the accessory process (a). The lateral branch nerve (curved white arrow) is seen in close proximity to the MBN; this nerve has no role in facet joint (rounded black arrow) innervation but provides motor innervation to the erector spinae muscles adjacent to the multifidus innervated by the MBN.

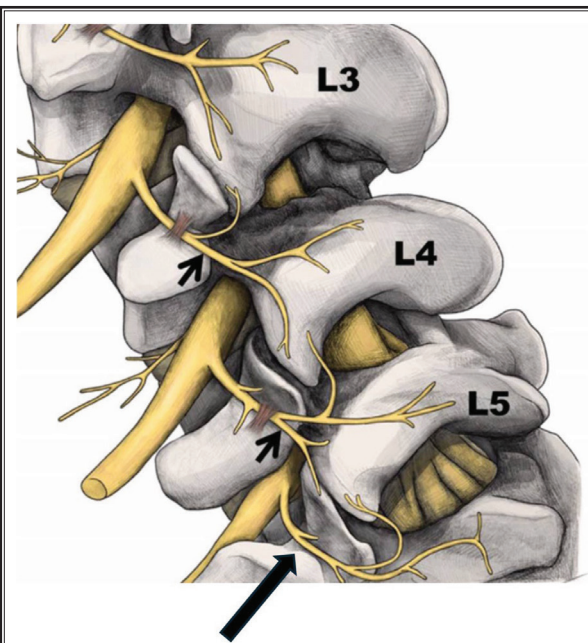


Fig. 2. Small black arrows displaying medial branch nerves of L3 and L4. The dorsal branch of L5, which is located at the base of the S1 SAP, is shown by the long black arrow.

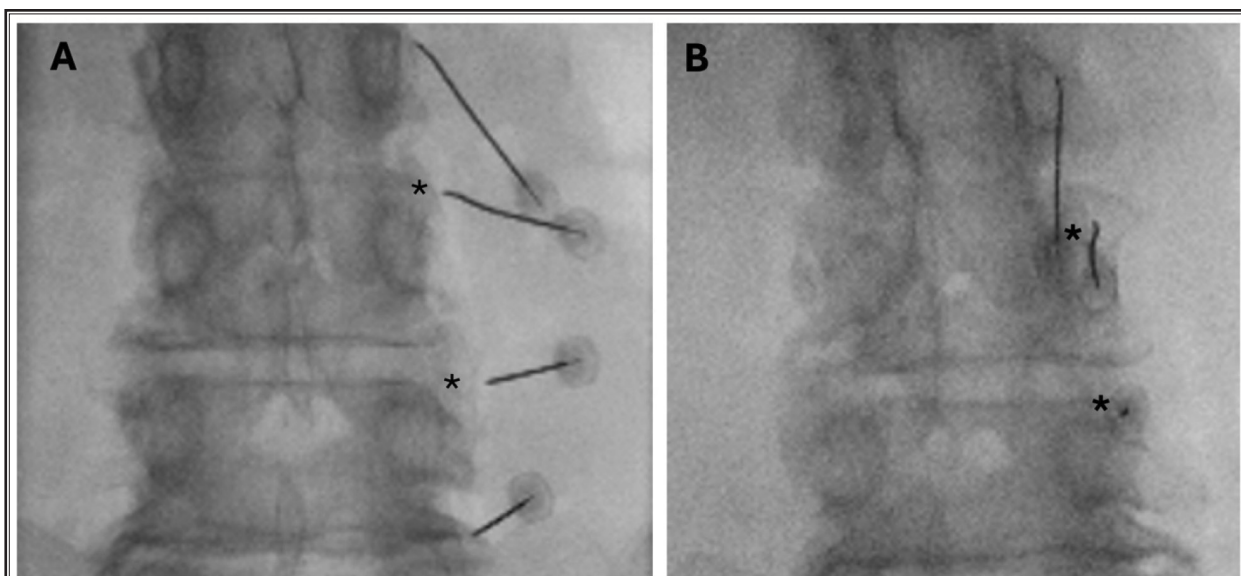


Fig. 3. Base of the SAP is easily identified (asterisk) in the AP (A) and slightly oblique (B) images. Note that the recesses defined by the intersection of the SAP and TP are not easily identified.

Table 1. *Technical considerations and recommendations for lesion optimization.*

| Consideration  | Recommendation   |
|----------------|--|
| MBN Path       | Target the lesion at the base of the SAP. The probe should enter laterally to medially, angled slightly superiorly at the tip. |
| Adipose Tissue | Adiposity near the intended target decreases the lesion size.  |
| Bone Proximity | Bone located near the intended target increases the lesion size.   |
| Injectate      | Lidocaine 2% and iohexol 240 increase the lesion size and should be considered as pre-ablative solutions.                      |

late lesion size (13). Wahezi et al. demonstrated that when more adipose tissue was present around the needle, the lesion size decreased. This effect is hypothesized to be caused by decreased thermal conductivity in fat compared to muscle. These findings may provide an explanation as to why Stelzer et al. (14) found that patients with a body mass index (BMI) > 30 had reduced efficacy in RF therapy at 6 and 12 months.

In contrast, the proximity of bone to the intended needle placement site has the opposite effect, increasing lesion size (15). A study by Eckmann et al. found that when RFA was performed at a bony interface, lesion size nearly doubled compared to within muscle tissue alone. The lesion geometry expanded predominantly perpendicularly to the needle along the bony interface. This effect is hypothesized to occur due to bone's poor thermal conductance, which traps thermal energy in the adjacent soft tissue (16).

Shahgholi et al. (13) demonstrated that iatrogenic injections of fluid, be it for contrast or for local anesthesia, can also modulate the area of thermal injury. Statistically significant increases in lesion size were described when using 2% lidocaine or iohexol 240 compared to lesions on which no injectate was used (17). Geometrically, the length was increased by 20% compared to controls when 2% lidocaine was used, and the width was increased by 20% compared to controls when iohexol 240 was used. These findings represented approximately 3-4 mm lesion size difference, which may be significant in MBN localization during mild probe misplacement.

The uses of various concentrations of saline have also been investigated in attempts to alter the size of lesions. A study by Provenzano et al. (18) found that the use of hypertonic saline increased the lesion size.

Additionally, it is important to be mindful of the MAL, which can intercept the delivery of thermal en-

ergy to the intended MBN and decrease the quality of thermal injury (19). Therefore, avoiding this ligament is important to maximize the effectiveness of the ablation.

The selection of cannulas should also be considered when maximizing lesion size. Newer cannulas utilize a protruding electrode array that maximizes lesion size by penetrating tissues for a more effective thermal injury. The research that we present in this article focuses on newer studies that employ these types of delivery systems. Nonprotruding needles would produce smaller sizes of thermal injury than what has been analyzed here. Cooled RFA techniques still use heat to create a neural lesion, however at a decreased temperature than conventional RFA. This approach has been shown to increase the size of the lesion as well (7).

Clinically, physicians should be mindful of the local environment in which they perform RFA. The geography of adipose tissue, blood vessels, ligaments, and bone should be considered and leveraged to best control the size and dimensions of the lesion. Furthermore, the thermal environment can be altered by the injectates used throughout the procedure.

## DISCUSSION

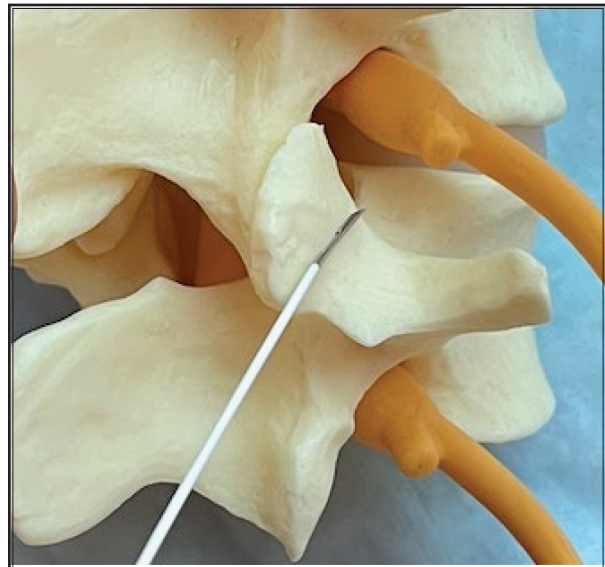
The facet joints of the spine are a common source of low back pain, though a universally accepted clinical diagnostic standard for this condition remains elusive. As such, diagnostic anesthetization of the MBNs is necessary to confirm facetogenic pain before proceeding with RFA. In this paper, we provide a comprehensive review of optimal techniques and key anatomic and iatrogenic factors that clinicians should consider to enhance lesion effectiveness.

MBNs should be targeted at the base of the SAP. Positioning electrodes parallel to the target has been shown to maximize thermal injury. Probes should enter in a lateral to medial fashion, angled slightly inferior to superior so the probe's active tip intersects the path of the MBN. Positioning the probe parallel to the medial branch has been recommended in historic literature, but recent reports of adipose related limitation of lesion size argue against this strategy. Individual anatomical considerations also play a significant role: adipose tissue near the target reduces lesion size, whereas bone in the vicinity increases it (13,20). Thus, the active tip of the needle should contact the greatest amount of bone possible at the SAP to maximize MBN ablation potential (Fig. 4). Thus, the technical strategy for performing MBN RFA should be towards accurate targeting of the

SAP and positioning of the needle so that it contacts bone (Fig. 5). Upon placement of the probe, sensory testing should be done if minimal local anesthesia is injected to the site. Motor testing should also be completed as well to rule out approximation with spinal nerves. Though the specificity of L4 and L5 MBN needle verification is low, motor and sensory testing should always be performed to assess approximation to the spinal nerves. Injectates can also be used to modify the geometry of the lesion. To increase the width of the lesion, 0.5 mL of lidocaine 2% or 0.5 mL of iohexol 240 can be used. Therefore, these agents can buffer against mildly misaligned probe placement.

Given the multitude of factors influencing the quality of thermal injury, a comprehensive understanding of these elements is essential for optimizing patient outcomes. Recognizing the patient's unique anatomy and physique can significantly impact treatment success. For instance, BMI serves as a useful indicator of adiposity around the target site, which reduces thermal conductance and diminishes thermal injury in the area. Utilizing 3-dimensional imaging can help identify individual anatomical differences and thus enable tailored treatment approaches. Additionally, appreciating skeletal variability among patients allows clinicians to adapt lesion dispersal patterns creatively to enhance effectiveness. With deeper insight into these variables, clinicians can achieve better outcomes for their patients.

As we continue to develop a deeper understanding of the factors influencing the quality of our techniques and clinical outcomes, there remain significant knowledge gaps that warrant further investigation. For instance, many studies examining the effects of adiposity and bone were performed in non-in vivo settings. While achieving consistent and objective lesion data across studies is challenging, real-world application remains the most critical context for improving patient outcomes. We propose that future studies should focus

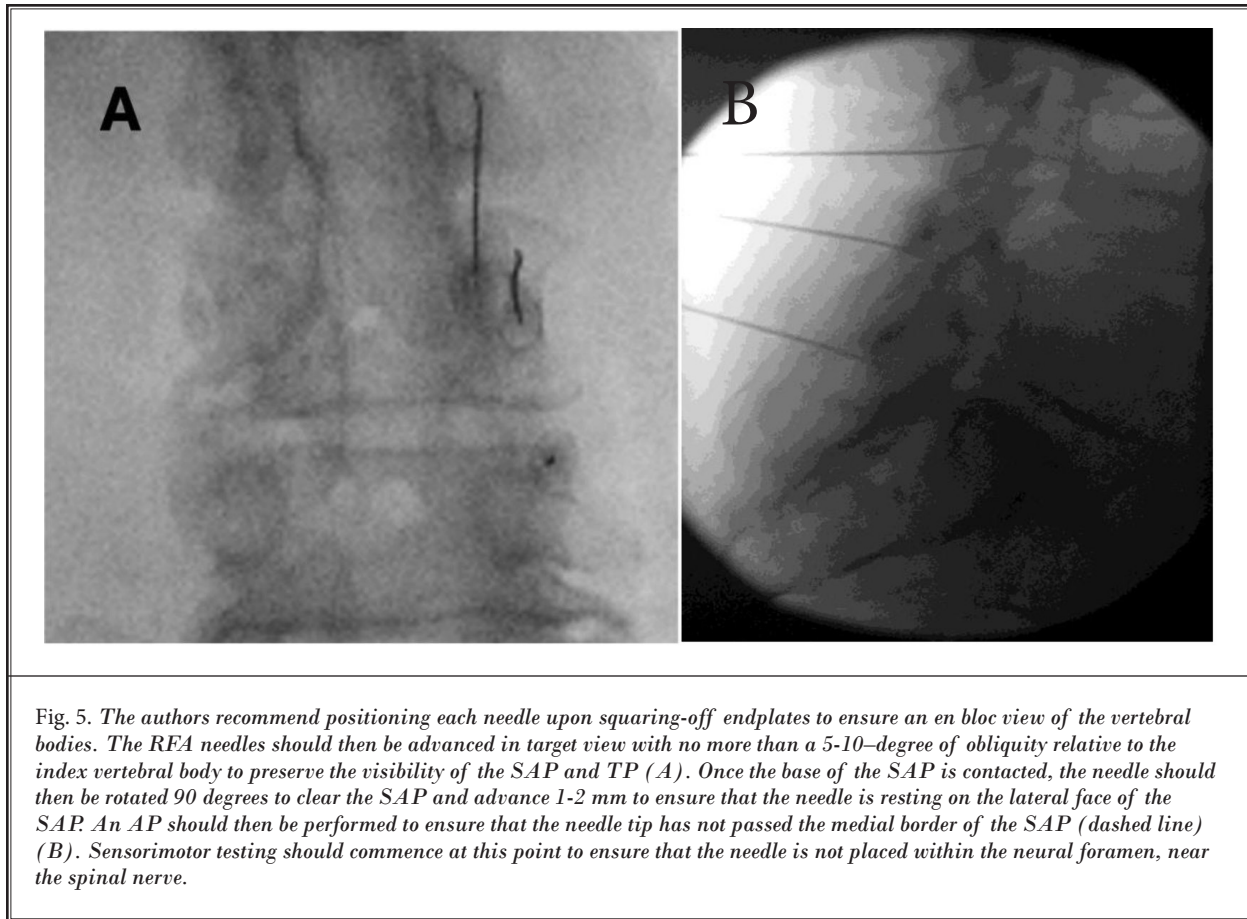


*Fig. 4. The authors submit that the ideal placement of the RFA needle is when it is contacting the base of the SAP. This placement has demonstrated increases in lesion size during ex vivo research.*

on evaluating both functional outcomes and pain relief in patients who undergo individualized procedures tailored to their unique anatomical environment.

## **CONCLUSION**

RFA of MBNs is an effective way to treat axial, facetogenic low back pain. However, revised practice guidelines that consider RFA lesion determinants such as: 1) placing the probe at the base of the SAP, juxtaposed to bone; 2) using iohexol 240 and lidocaine 2%, as a preablative solution; and 3) evaluating computed tomography and/or magnetic resonance imaging prior to RFA to target a SAP location that is surrounded by minimal adipose, may optimize the efficacy of this procedure.



## REFERENCES

1. Van den Heuvel SAS, Cohen SPC, de Andrès Ares J, Van Boxem K, Kallewaard JW, Van Zundert J. 3. Pain originating from the lumbar facet joints. *Pain Pract* 2024; 24:160-176.
2. Manchikanti L, Kaye AD, Soin A, et al. Comprehensive evidence-based guidelines for facet joint interventions in the management of chronic spinal pain: American Society of Interventional Pain Physicians (ASIPP) Guidelines Facet Joint Interventions 2020 Guidelines. *Pain Physician* 2020; 23:S1-S127.
3. Manchikanti L, Knezevic E, Knezevic NN, et al. Effectiveness of facet joint nerve blocks in managing chronic axial spinal pain of facet joint origin: A systematic review and meta-analysis. *Pain Physician* 2024; 27:E169-E206.
4. Manchikanti L, Kosanovic R, Pampati V, et al. Low back pain and diagnostic lumbar facet joint nerve blocks: Assessment of prevalence, false-positive rates, and a philosophical paradigm shift from an acute to a chronic pain model. *Pain Physician* 2020; 23:519-530.
5. Cohen SP, Bhaskar A, Bhatia A, et al. Consensus practice guidelines on interventions for lumbar facet joint pain from a multispecialty, international working group. *Reg Anesth Pain Med* 2020; 45:424-467.
6. Lee DW, Pritzlaff S, Jung MJ, et al. Latest Evidence-Based Application for Radiofrequency Neurotomy (LEARN): Best practice guidelines from the American Society of Pain and Neuroscience (ASPN). *J Pain Res* 2021; 14:2807-2831.
7. Sayed D, Grider J, Strand N, et al. The American Society of Pain and Neuroscience (ASPN) evidence-based clinical guideline of interventional treatments for low back pain. *J Pain Res* 2022; 15:3729-3832.
8. Poodendaen C, Suwannakhan A, Chaiyamoong A, et al. Anatomy of mamillo-accessory foramen and prevalence of ossified mamillo-accessory ligament in lumbar vertebrae related to age. *Surg Radiol Anat* 2024; 46:1367-1371.
9. Demondion X, Vidal C, Glaude E, Subocz L, Francke JP, Cotten A. The posterior lumbar ramus: CT-anatomic correlation and propositions of new sites of infiltration. *AJNR Am J Neuroradiol* 2005; 26:706-710.
10. Wahezi SE, Alexeev E, Georgy JS, et al. Lumbar medial branch block volume-dependent dispersion patterns as a predictor for ablation success: A cadaveric study. *PM R* 2018; 10:616-622.

11. Dreyfuss P, Schwarzer AC, Lau P, Bogduk N. Specificity of lumbar medial branch and L5 dorsal ramus blocks. A computed tomography study. *Spine (Phila Pa 1976)* 1997; 22:895-902.
12. Jani M, Mehta N, Yu S, et al. Mitigating factors in L4 and L5 medial branch motor stimulation during radiofrequency ablation. *Curr Pain Headache Rep* 2024; 28:465-467.
13. Shahgholi L, Ortiz N, Naeimi T, et al. Adipose tissue impacts radiofrequency ablation lesion size: Results of an ex vivo poultry model. *Pain Physician* 2023; 26:569-574.
14. Stelzer W, Stelzer V, Stelzer D, Braune M, Duller C. Influence of BMI, gender, and sports on pain decrease and medication usage after facet-medial branch neurotomy or SI joint lateral branch cooled RF-neurotomy in case of low back pain: Original research in the Austrian population. *J Pain Res* 2017; 10:183-190.
15. Eckmann MS, Martinez MA, Lindauer S, Khan A, Ramamurthy S. Radiofrequency ablation near the bone-muscle interface alters soft tissue lesion dimensions. *Reg Anesth Pain Med* 2015; 40:270-275.
16. Feldmann A, Wili P, Maquer G, Zysset P. The thermal conductivity of cortical and cancellous bone. *Eur Cell Mater* 2018; 35:25-33.
17. Ortiz N, Shahgholi L, Kohan L, Wahezi SE. The effect of local anesthetics and contrast agents on radiofrequency ablation lesion size. *Pain Med* 2023; 24:269-274.
18. Provenzano DA, Cosman ER Jr, Wilsey JT. Hypertonic sodium chloride preinjectate increases in vivo radiofrequency ablation size: Histological and magnetic resonance imaging findings. *Reg Anesth Pain Med* 2018; 43:776-788.
19. Liu Z, Chen J, Fang D, et al. Anatomical observation and clinical significance of the medial branch of the lumbar dorsal rami. *Spine (Phila Pa 1976)* 2024; 49:E164-E172.
20. Lau P, Mercer S, Govind J, Bogduk N. The surgical anatomy of lumbar medial branch neurotomy (facet denervation). *Pain Med* 2004; 5:289-298.

